



■ HIP

An algorithmic approach to total hip arthroplasty in patient with post-polio paralysis and fixed pelvic obliquity

**R. Malhotra,
D. Gautam,
S. Gupta,
K. K. Eachempati**

From All India Institute
of Medical Sciences,
New Delhi, India

Aims

Total hip arthroplasty (THA) in patients with post-polio residual paralysis (PPRP) is challenging. Despite relief in pain after THA, pre-existing muscle imbalance and altered gait may cause persistence of difficulty in walking. The associated soft tissue contractures not only imbalances the pelvis, but also poses the risk of dislocation, accelerated polyethylene liner wear, and early loosening.

Methods

In all, ten hips in ten patients with PPRP with fixed pelvic obliquity who underwent THA as per an algorithmic approach in two centres from January 2014 to March 2018 were followed-up for a minimum of two years (2 to 6). All patients required one or more additional soft tissue procedures in a pre-determined sequence to correct the pelvic obliquity. All were invited for the latest clinical and radiological assessment.

Results

The mean Harris Hip Score at the latest follow-up was 79.2 (68 to 90). There was significant improvement in the coronal pelvic obliquity from 16.6° (SD 7.9°) to 1.8° (SD 2.4°; $p < 0.001$). Radiographs of all ten hips showed stable prostheses with no signs of loosening or migration, regardless of whether paralytic or non-paralytic hip was replaced. No complications, including dislocation or infection related to the surgery, were observed in any patient. The subtrochanteric shortening osteotomy done in two patients had united by nine months.

Conclusion

Simultaneous correction of soft tissue contractures is necessary for obtaining a stable hip with balanced pelvis while treating hip arthritis by THA in patients with PPRP and fixed pelvic obliquity.

Cite this article: *Bone Jt Open* 2021;2-9:696–704.

Keywords: Total hip arthroplasty, Soft-tissue contracture, Contracture release, Post-polio paralysis

Introduction

Total hip arthroplasty (THA) is the established treatment for patients presenting with painful disabling hip arthritis and/or associated instability secondary to muscular imbalance, not amenable to non-arthroplasty options.¹ Hip arthritis is seen both in the affected and contralateral limbs with post-polio residual paralysis (PPRP). While the affected side can become subluxated and dysplastic due to weak abductors and extensors combined with normal flexors and adductors, the contralateral hip can become arthritic owing to leg length discrepancy,

pelvic obliquity, and severe deformities of the affected hip.²

After THA, despite pain relief from the arthritic hip, patients may continue to experience difficulty in walking, with or without support, due to pre-existing muscle imbalance and altered gait. The associated deformity due to soft tissue contractures, especially on the contralateral side, poses the risk of dislocation or early loosening.^{3,4}

The problems in the polio-affected hip include dysplastic acetabulum, valgus femoral neck, narrow femoral canal, disuse osteoporosis, and increased risk of dislocation after THA due to muscular imbalance

Correspondence should be sent to Deepak Gautam; email: cmcdeepak@yahoo.com

doi: 10.1302/2633-1462.29.BJO-2021-0084.R1

Bone Jt Open 2021;2-9:696–704.

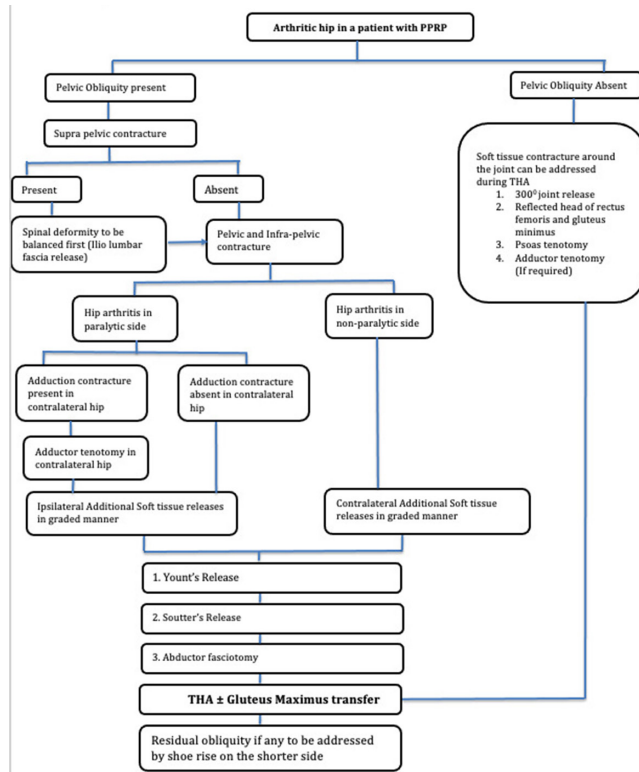


Fig. 1

Authors' algorithm for managing soft tissue contractures during total hip arthroplasty in patients with post-polio residual paralysis and fixed pelvic obliquity.

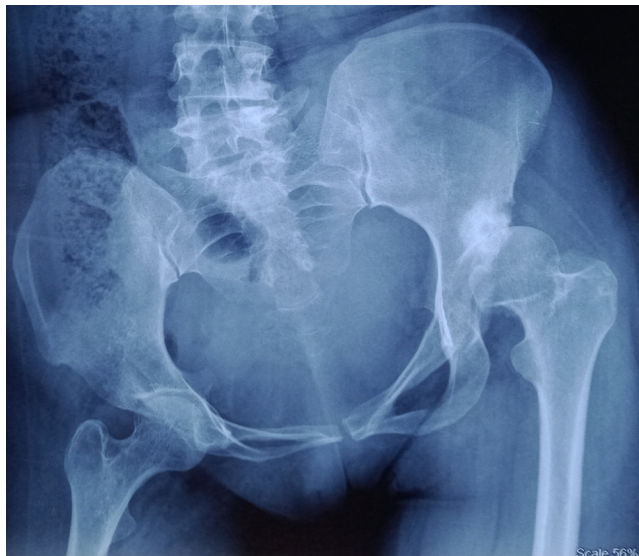


Fig. 2

Radiograph of pelvis with both hips in a 30-year-old female with post-polio residual paralysis affecting her right lower limb. She was walking with hand to knee (right side) gait. She presented with pain in left hip. Note the arthritic changes in her left hip and tilting of pelvis towards right side. She also had flexion contracture in right knee.

between the hip abductors-adductors and extensors-flexors.^{5,6} Issues with the contralateral hip include

muscular imbalance between the abductors of either side, pelvic obliquity, and inability to correct limb length discrepancy following THA due to contralateral paralytic limb.

There is paucity of literature on THA in patients with residual paralysis following poliomyelitis.¹ There is also a considerable void in reporting from the developing world, where patients with residual paralysis have either been neglected or denied arthroplasty surgeries in anticipation of complications due to soft tissue contractures. To the best of our knowledge, no study has reported on results of THA in patients with PPRP with fixed pelvic obliquity and hip arthritis. We report our series of patients with PPRP with fixed pelvic obliquity who underwent THA and combined soft tissue release on ipsilateral and contralateral side to achieve correction of the pelvic obliquity. The sequence of soft tissue release is delineated.

Methods

In all, ten hips in ten patients with PPRP with fixed pelvic obliquity who underwent THA in two centres (All India Institute of Medical Sciences, New Delhi, India, and Medico-cover Hospital, Madhapur, India) from January 2014 to March 2018 with a minimum two years follow-up were evaluated. Fixed pelvic obliquity was defined as inability to square the pelvis when a traction is applied in the short limb. Patients without pelvic obliquity and those who did not require additional soft tissue releases were excluded from the study. The additional soft tissue releases were defined as those other than the following:

1. The 300° pericapsular release (sparing 60° for protecting the abductors);
2. Muscles in close vicinity of the joint (gluteus minimus muscle and the reflected head of rectus femoris);
3. The adductor tenotomy (if required);
4. and Psoas tenotomy at the trochanteric attachment (if required).

In every case, the operative procedure followed detailed planning after consideration of patient's clinical condition and radiographs by the senior surgeons (RM, KKE) from the two hospitals. The requirement of additional soft tissue procedure(s) was anticipated preoperatively after clinical examination. All additional soft tissue contractures were addressed prior to THA in a sequential manner, as per the algorithm shown in Figure 1. The contracture releases were aimed at correcting the pelvic obliquity (Figures 2 to 7). All the surgeries were performed via the standard posterior approach. Subtrochanteric shortening osteotomy was required in two cases (20%), with high riding femur to achieve reduction.

Additional soft tissue procedures. One or more of the following combined soft tissue procedures were performed as per the requirement:

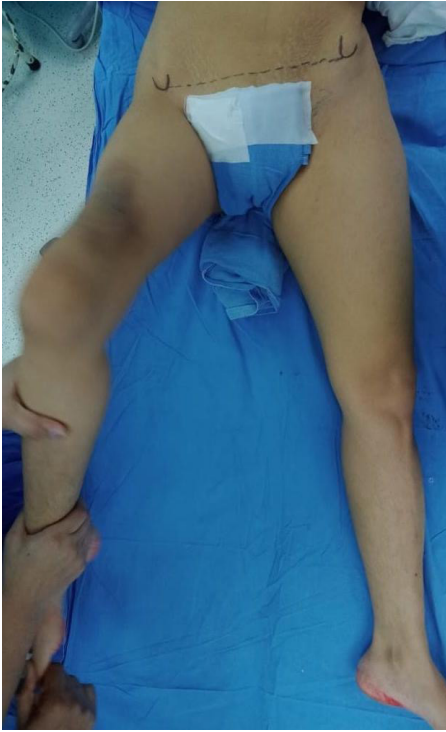

Fig. 3

Clinical photograph of the 30-year-old female showing pelvis tilted to right side. On clinical examination, she had tight Iliotibial band.

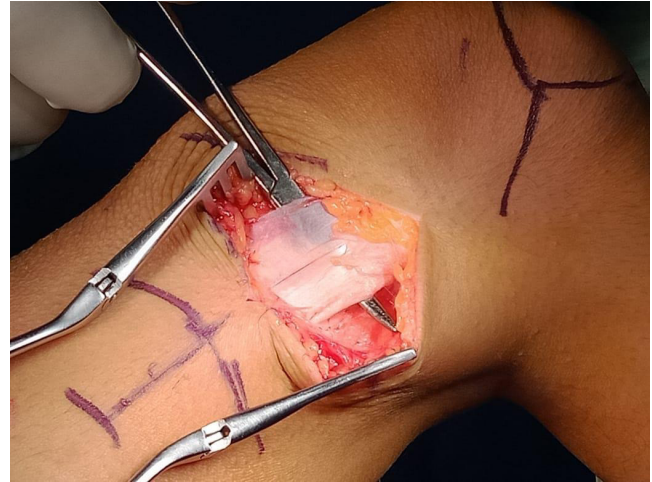


Fig. 4

Intraoperative picture showing exposure of tight iliotibial band for Yount's release.

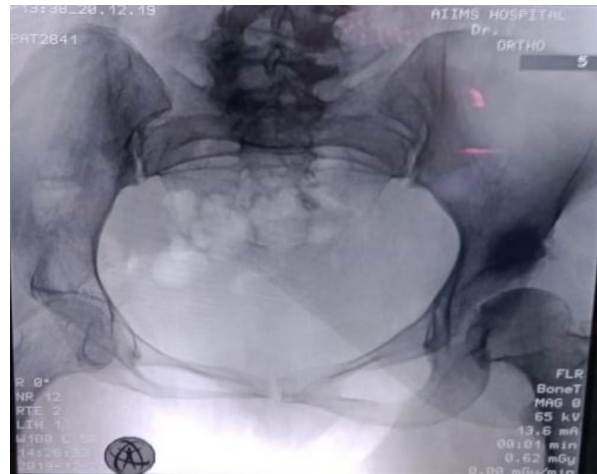

Fig. 6

Intraoperative traction radiograph of the pelvis in anteroposterior view showing a squared pelvis. The patient was then positioned in right lateral position and left total hip arthroplasty was performed via posterior approach.

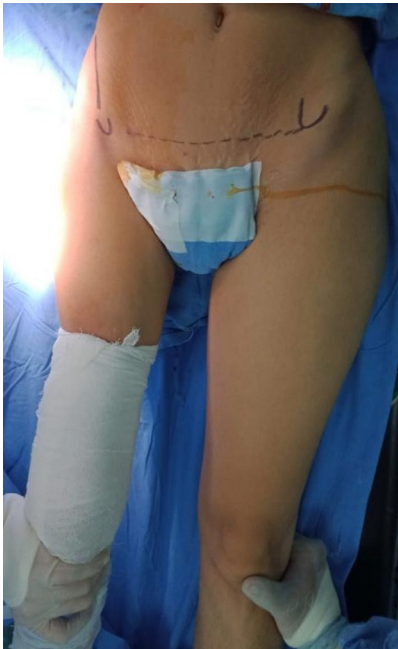

Fig. 5

Intraoperative clinical photograph showing near normal squaring of the pelvis after Yount's release.

1. Yount's release:⁷ With the patient in a lateral or floppy lateral position, 5 cm to 8 cm incision was given on the lateral aspect of the distal thigh. The Iliotibial band

was exposed and isolated and excised for a length of at least 2 cm. This was followed by the division of the intermuscular septum and release of lateral hamstrings as per the requirement. The knee extension, as well as hip extension and adduction, were checked at each stage of the surgical release. Once the procedure was completed and the wound closed, the patient was positioned supine and re-assessed clinically. If the patient had a residual hip contracture despite Yount's release, Soutter's soft tissue release around the hip was undertaken.

2. Soutter's release:⁸ Contractures around the hip were in flexion, either alone or associated with abduction. A short transverse incision of around 5 cm was given two finger breadths inferior to the anterior superior

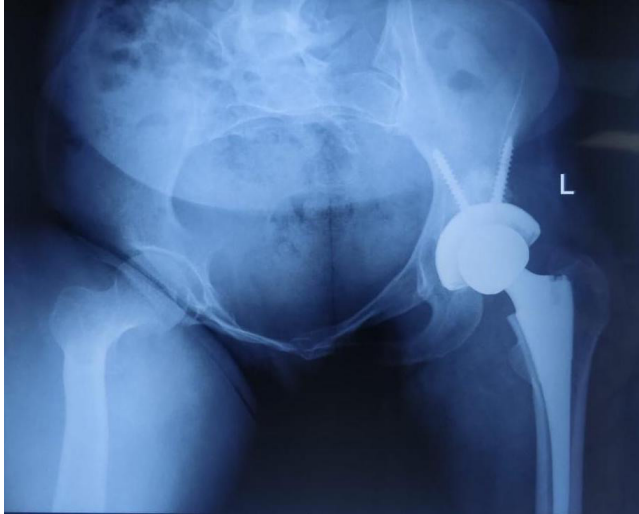


Fig. 7

Two-year follow-up radiograph of pelvis with both hips showing stable implants in situ. Note the near squared pelvis. The patient is pain free and walking with a floor reaction orthosis on her right leg.

iliac spine. The avascular plane between the sartorius and tensor fascia lata was identified after protecting the lateral cutaneous nerve of thigh. The tight structures were released in a stepwise manner in the sequence of fascia of sartorius followed by the muscle itself. This was followed by the release of tensor fascia lata at the musculotendinous junction near its attachment at the outer border of iliac crest. If the flexion contracture still persisted, the straight head of rectus femoris was released. Any residual flexion contracture was addressed by anterior capsular release and/or psoas release during the THA procedure. If the flexion contracture was associated with abduction contracture, the release was extended posteriorly up to the gluteus fascia, and was further addressed either by gluteus maximus transfer and a dual mobility component, or a constrained hip prosthesis during THA.

3. Gluteus maximus transfer:⁹ Gluteus maximus transfer was carried out in the case where the contracture necessitated the Soutter's release to be extended till the abductor fascia, resulting in compromised abductor function and in patients undergoing THA on the paralytic side with abductor power less than 3/5. The transfer was carried out according to the steps described by Whiteside.⁹ The gluteus maximus muscle was split in line, approximately to half of the length of the muscle continuing distally to split the fascia lata approximately 4 cm distal to the upper attachment of the gluteus maximus. The anterior portion of the gluteus maximus was then elevated as a flap by splitting the fibres of tensor fascia lata in its line proximally up to the iliac crest, hence creating a triangular flap based proximally. The lateral cortex of the greater trochanter was then exposed through 2

cm of the proximal attachment of vastus lateralis by splitting along its midline and elevating the gluteus medius and vastus lateralis in continuity. The lateral cortex was roughened with multiple drill holes, and the apex of the gluteus maximus triangular flap sutured onto the lateral cortical bone with multiple non-absorbable sutures under moderate tension. The split vastus lateralis and the gluteus medius were repaired over the attached flap with absorbable sutures. The hip was held in 15° abduction for closure. The posterior musculocapsule complex was re-attached to the posterior border of greater trochanter. The anterior margin of the posterior part of gluteus maximus was sutured to the posterior margin of the transferred flap. The fascial closure was completed by snug suturing of anterior and posterior portions of the fascia lata over the transferred flap making a Y-shaped closure proximally.

4. Iliolumbar fascia release:¹⁰ Iliolumbar fascia release was carried out in one patient to address an associated fixed pelvic obliquity due to suprapelvic contracture. The suprapelvic contracture was diagnosed in a patient with non-structural lumbar scoliosis where the pelvic obliquity was due to contracture of supra-pelvic soft tissues. The contracture release was done as described by Lee et al.¹⁰ With the patient in floppy lateral position and slightly flexed trunk, a curved incision was made extending proximally from the iliac crest upto the spinous process of L5 vertebra. The subcutaneous layer was dissected in the line of skin incision to expose the posterior layer of iliolumbar fascia. The thick layer of iliolumbar fascia posteriorly was divided transversely from the iliac crest extending upto the L5 spinous process leaving the underlying erector spinae muscle intact. The division was carried laterally upto the junction where the anterior and posterior fascial layers blend. The interspinous ligaments at the levels L4/L5 and L5/S1 were divided, and the erector spinae muscle was reflected medially to free up the fascial attachments and short rotator muscles from the L4 and L5 transverse processes. The release was completed by dividing the arcuate band of the iliolumbar ligament. An intraoperative traction image (traction to the ipsilateral limb by an assistant after removing the back support and making the patient supine) was taken to assess the squaring of pelvis. THA was completed as per the standard procedure.

Postoperatively, all the patients were nursed prone for at least two hours, three times a day, for six weeks. The side with preoperative adduction deformity was kept abducted. Patients were discharged with instructions to adhere to the precautions as advised. All the patients were regularly follow-up as per our service protocol.

After approval from Institutional Ethics Committee of both the hospitals, we retrospectively analyzed all

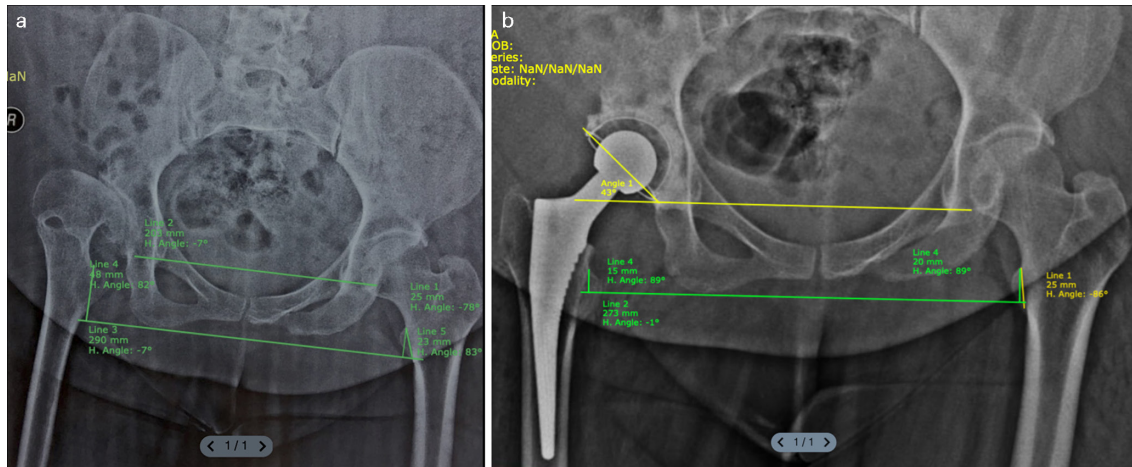


Fig. 8

a) Preoperative radiograph showing hip arthritis with subluxation in a paralytic right lower limb due to polio; b) Six years follow-up following right total hip arthroplasty. Note the stable hip prosthesis is situ.

ten patients who were able to attend the outpatient department as a part of regular follow-up. The clinical and surgical details were obtained from the outpatient department record card and hospital medical records. The clinical assessment was done using the Harris Hip Score¹¹ and radiological assessment with serial radiographs. The preoperative radiographs were retrieved from the service record for comparison. Residual limb length discrepancy and tilting of the pelvis were evaluated with the anteroposterior radiographs of the pelvis. The type of the coronal plane pelvic obliquity in each patient was classified as described by Lee et al.¹⁰ The coronal plane pelvic obliquity was measured by drawing a line joining the inferior margins of the two ischial tuberosities and the angle made by it with the horizontal. The acetabular inclination was measured as the angle between the acetabular axis and the horizontal. All the radiological measurements were done using the Surgimap software (Nemaris, USA). The limb length was assessed radiologically by drawing a line parallel to the inter-teardrop line at the level of lesser trochanters and measuring the level of upper margin of lesser trochanter with respect to that line (Figure 8). Use of orthosis (if any) was noted during the clinical assessment.

Results

All the patients were female with mean age of 39.7 years (standard deviation (SD) 8.5; 25 to 52) at the time of surgery. The mean follow-up was four years (2 to 6). Five patients had undergone THA on contralateral non-paralyzed side and four patients on the paralyzed side. One patient had bilateral involvement due to polio with left side being flail and the right having weakness of hip abductors (power of 1/5). The right hip, on the higher side of the pelvic obliquity had painful dislocated hip for the last two years before surgery. Prior to the dislocation,

the patient was ambulating on this hip with the help of a walker. The indication for surgery was severe hip pain with end-stage arthritis and chronic dislocated right hip rendering the patient unable to carry out her activities of daily living. All operations were performed under spinal anaesthesia. The soft tissue procedures performed were necessitated as a part of THA to achieve pelvic obliquity correction in each patient. All the patients had non-structural scoliotic deformity secondary to contractures of the hip and knee and one patient with lumbar scoliosis required additional iliolumbar fascia release. Clinical and surgical details obtained from the records are summarized in Table I.

The mean Harris Hip Score at the latest follow-up was 79.2 (68 to 92). Compared to the preoperative status, all patients had a satisfactory outcome, except two, who were pain free but partially satisfied because of the paralytic limb.

The radiographs of all ten hips showed stable prostheses, with no signs of loosening or migration, regardless of whether paralytic or non-paralytic hip was replaced. There was no osteolysis or heterotopic ossification in any of the radiographs at the latest follow-up (Figure 8b). The pelvic obliquity as measured in the anteroposterior pelvis radiograph showed significant improvement from 16.6° (SD 7.9°; 95% confidence interval (CI) 10.8 to 22.3) to 1.8° (SD 2.4°; 95% CI 0.5 to 3.5) ($p < 0.001$, paired t -test). The limb length discrepancy on the paralytic limb decreased significantly from 2.9 cm (SD 1.6; 95% CI 1.7 to 4.1) to 0.6 cm (SD 0.8; 95% CI 0.4 to 1.2) ($p < 0.001$, paired t -test). The mean acetabular component inclination was 37.9° (SD 5.6°; 30 to 44) (Table II). The subtrochanteric shortening osteotomy carried out in two patients had united by nine months.

No complications, including dislocation or infection related to the surgery, were observed in any patient. The

Table I. Demographics, surgical details, and clinical follow-up of the patients.

Serial no (initials)	Age, yrs (sex)	Limb affected by polio	THA side	Type of pelvic obliquity ¹⁰	Sequence of soft tissue procedures	Implants used	HHS at latest follow-up	Use of walking aids at present	Remarks
1 (VL)	52 (F)	Left	Left	IIB	Ipsilateral Yount's and Soutter's release, plus abductor fasciotomy, plus gluteus maximus transfer	Uncemented dual mobility component (Evolutis) plus Corail Stem (Depuy)	90 at six years	KFO and cane on left side	Satisfactory
2 (AA)	46 (F)	Right	Right	IIC	Ipsilateral Yount's and Soutter's release, plus abductor fasciotomy, plus gluteus maximus transfer	Cemented Snap fit component (Link) plus Corail Stem (Depuy)	78 at six years	Crutch on right side	Satisfactory
3 (MA)	46 (F)	Left	Right	IID	Contralateral Yount's & Soutter's release plus ipsilateral Iliolumbar fascia release plus adductor tenotomy	Modular dual mobility component (Stryker) plus SROM Stem (Depuy)	72 at five years	KFO on left side	Partially satisfied
4 (GR)	43 (F)	Right	Right	IIC	Ipsilateral Yount's & Soutter's release+ Abductor fasciotomy+ Gluteus Maximus transfer	Uncemented dual mobility component (Evolutis) plus Hactiv Stem (Evolutis)	92 at five years	KFO on right side	Satisfactory
5 (PC)	45 (F)	Right	Left	IB	Contralateral Yount's & Soutter's release plus adductor tenotomy	Uncemented Pinnacle component (Depuy) plus S-ROM stem (Depuy)	80 at five years	KFO on right side	Satisfactory
6 (SR)	42 (F)	Right	Left	IIC	Contralateral Yount's and Soutter's release	Libertas dual mobility component (Max) plus Latitud Stem (Max)	68 at three years	Weightbearing on left side only with a cane, right leg flail	Partially satisfied
7 (AD)	30 (F)	Right	Left	IIC	Contralateral Yount's release	R3 component (Smith & Nephew) plus Synergy Stem (Smith & Nephew)	80 at two years	FRO on right side	Satisfactory
8 (LD)	32 (F)	Left	Right	IIC	Contralateral Yount's and Soutter's release	Modular dual mobility component (Stryker) plus ML Taper Stem (Zimmer Biomet)	74 at 2 years	KFO on left side	Satisfactory
9 (SD)	25 (F)	Left	Left	IIC	Ipsilateral Yount's and Soutter's release, plus Abductor fasciotomy, plus gluteus maximus transfer	Uncemented dual mobility component (Evolutis) plus SROM Stem (Depuy)	82 at two years	KFO on left side	Satisfactory
10 (NM)	36 (F)	Right	Right	IB	Ipsilateral Yount's and Soutter's release, plus Abductor fasciotomy, plus gluteus maximus transfer	Uncemented Pinnacle Gription component (Depuy) plus SROM stem (Depuy)	76 at two years	KFO on right side	Satisfactory

FRO, floor reaction orthosis; KAFO, knee ankle foot orthosis; SD, standard deviation.

Table II. Change in pelvic parameters following soft tissue procedure and total hip arthroplasty.

Serial no (author initials)	Pelvic inclination, °		Limb length discrepancy, cm		Acetabular inclination, °
	Preoperative	Post-surgery	Preoperative	Post-surgery	
1 (VL)	15	0	1.5	0.0	39
2 (AA)	16	0	2.5	0.5	43
3 (MA)	37	8	6.0	2.5	32
4 (GR)	11	2	1.5	0.0	30
5 (PC)	17	1	2.5	1.0	43
6 (SR)	11	0	3.0	0.0	39
7 (AD)	20	3	2.0	0.0	34
8 (LD)	18	2	4.5	1.0	44
9 (SD)	9	0	1.0	0.0	31
10 (NM)	12	2	5.0	1.5	44

survivorship free from any reoperation, dislocation, loosening, or infection was 100% at six years.

Discussion

The successful implementation of vaccination regime dramatically reduced the new cases of poliomyelitis worldwide.¹² However, patients in developing nations who were infected in the later years of eradication, and left with residual paralysis, are still a cause of concern. Although they have learned to live with the paralytic limb, the quality of life further deteriorates when the patient

develops pain due to arthritic changes in the joints. Either of the hips (paralytic or non-paralytic) can be affected with hip arthritis.¹³ The altered gait pattern due to motor weakness, limb length discrepancy, and pelvic obliquity ostensibly predisposes these patients to degenerative changes in the weightbearing joints.¹⁴⁻¹⁶

Historical treatment with arthrodesis has been gradually replaced by THA, albeit with caution in polio survivors presenting with painful hip arthritis.¹⁷ There is paucity of literature on THA in PPRP with a few case reports and small series.¹⁸ Most of the studies have reported clinical

and radiological results in these patients but little has been discussed about the necessary soft tissue releases to correct the fixed pelvic obliquity frequently encountered in these patients. A systematic review by Upadhyaya et al,¹⁸ including the present authors, found that the rate of complications following THA in these patients is reported upto 17.18% with 7% dislocation as the major complication¹⁸ It is unambiguous that the dislocation in these patients is primarily due to muscle imbalance, soft tissue contracture, and consequent pelvic obliquity. This persistence of contracture and pelvic obliquity may not only lead to dislocation but also early loosening and accelerated polyethylene liner wear. The accelerated poly wear may eventually lead to osteolysis and late dislocations. Hence, a well-functioning non-dislocated hip may still be at a risk of polyethylene liner wear and dislocation if the soft tissue contractures are not addressed properly. The authors believe that apart from the pain relief, correction of deformity and a squared pelvis is needed for the optimum outcome following THA in PPRP. Moreover, deformity correction also gives a sense of cosmetic wellbeing and postural balance. The sequence of soft tissue procedures adopted by the authors resulted in a satisfactory outcome and 100% survival at a follow-up of two to six years. There were no dislocations or any other complications reported at the latest follow-up. One patient with contralateral THA had a low score because of flail paralytic hip and the patient has to use a support for ambulation.

The choice of implant has always been a matter of concern in these patients, and the use of a constrained liner was justified for muscular weakness and a pre-emptive measure to reduce the risk of dislocation. The constrained liners protect the hips against dislocation, but at the cost of acetabular loosening due to increased transmission of stresses across the joint.^{19,20} With the advent of a dual mobility component, the use of constrained acetabular components has decreased due to the fact that the increase in effective diameter of head facilitates greater range of motion before dislocation.²¹ We had good outcomes in our series, wherein four of the six patients (66.6%) received a dual mobility acetabular prosthesis. Although a longer follow-up is required to document long-term fixation in our series, the dual mobility components showed satisfactory osseointegration, as evidenced by the absence of any radiolucent lines and/or component loosening at a mean follow-up of four years (SD 1.75; 2 to 6).

Release of abductor contracture and restoration of femoral offset are important for maintaining pelvic balance in cases of fixed obliquity.²² On the other hand, abductor tension is important in providing the hip stability, hence we recommend gluteus maximus transfer to provide an optimum soft tissue tension around the joint if the abductor power is less or compromised due to releases. One case of contralateral THA with good abductor tension could be managed

with uncemented unconstrained prosthesis. However, one case with hip arthritis in paralytic limb required a constrained prosthesis due to the absence of abductor function. Both these patients are doing well with stable prostheses at the latest follow-up.

Limitations. Despite satisfactory results, there are a few limitations of this study. First, this is a small series with a retrospective study design. However, a prospective randomized study is not possible on this topic due to the rarity of disease; this is the only study to report on combined soft tissue procedures and THA in patients of post-polio paralysis. Second, two different surgeons (RM, KKE) were involved. Nonetheless, the same surgical principles were used in all the cases, and were performed after discussion between the two senior surgeons. Third, the limb length discrepancy was measured radiologically at pelvic level only, and was not corroborated with the clinical discrepancy (if any) as these patients may also have discrepancy due to infrapelvic causes. The deformities distal to the knee were not accounted. Fourth, only one patient had a significant lumbar spine deformity necessitating release, making it difficult to generalize our findings.

In conclusion, the results of this series have re-emphasized that THA can be considered a feasible treatment for hip arthritis in patients with PPRP. This is the first study to report on the additional soft tissue procedures performed along with THA in patients with post-polio paralysis so as to simultaneously correct the deformity, and give a squared or a nearly squared painless pelvis. In addition to pain relief, correction of soft tissue contractures is also needed for hip stability and pelvic balance. Given the risk of implant loosening with the use of constrained prosthesis, the authors advocate the use of dual mobility prosthesis whenever possible. One should also consider gluteus maximus transfer if the abductor power is compromised due to the contracture release. Although a general conclusion cannot be made with a limited number of patients, this study proves that simultaneous correction of bilateral contractures is an important aspect of treating hip arthritis in patients with PPRP. New cases of poliomyelitis are unlikely to be seen in developed countries (as they have been eliminated or eradicated by vaccinations), it is intuitive that patients infected before the eradication era are still there in the age range for THA in developing countries, and will be approaching orthopaedic surgeons for a few decades in the future.



Take home message

- Either of the hips (paralytic or non-paralytic) can be affected with hip arthritis in post-polio residual paralysis.
- If a contralateral non-paralytic hip is arthritic, the contracted soft tissue on the paralytic side should be released before undertaking total hip arthroplasty (THA) on the contralateral side.
- If the paralytic hip is arthritic, the THA should be performed cautiously, along with soft tissue release as it may require a constrained liner and a gluteus maximus transfer to achieve a stable hip.

References

- DeDeugd CM, Perry KI, Trousdale WH, Taunton MJ, Lewallen DG, Abdel MP.** Total hip arthroplasty in patients affected by poliomyelitis. *Bone Joint J.* 2018;100-B(6):733–739.
- Sonohata M, Kitajima M, Kawano S, Mawatari M.** Total hip arthroplasty for the paralytic and non-paralytic side in patient with residual poliomyelitis. *Open Orthop J.* 2016;10:105–110.
- Hernigou P, Filippini P, Flouzat-Lachaniette CH, Batista SU, Poignard A.** Constrained liner in neurologic or cognitively impaired patients undergoing primary THA. *Clin Orthop Relat Res.* 2010;468(12):3255–3262.
- Berend KR, Lombardi AV, Mallory TH, Adams JB, Russell JH, Groseth KL.** The long-term outcome of 755 consecutive constrained acetabular components in total hip arthroplasty: Examining the successes and failures. *J Arthroplasty.* 2005;20(7 suppl 3):93–102.
- Merchant AC.** Hip abductor muscle force; an experimental study of the influence of hip position with particular reference to rotation. *J Bone Joint Surg Am.* 1965;47-A:462–476.
- Bjerkreim I.** Secondary dysplasia and osteoarthritis of the hip joint in functional and in fixed obliquity of the pelvis. *Acta Orthop Scand.* 1974;45(6):873–882.
- Yount CC.** The role of the tensor fascia femoris in certain deformities of the lower extremities. *J Bone Joint Surgery.* 1926;8(1):171–193.
- Soutter R.** New operation for hip contracture in poliomyelitis. *Boston Med Surg J.* 1914;170:380–381.
- Whiteside LA.** Surgical technique: transfer of the anterior portion of the gluteus maximus muscle for abductor deficiency of the hip. *Clin Orthop Relat Res.* 2012;470(2):503–510.
- Lee DY, Choi IH, Chung CY, Cho TJ, Lee JC.** Fixed pelvic obliquity after poliomyelitis: classification and management. *J Bone Joint Surg Br.* 1997;79-B(2):190–196.
- Harris WH.** Traumatic arthritis of the hip after dislocation and acetabular fractures: treatment by mold arthroplasty. An end-result study using a new method of result evaluation. *J Bone Joint Surg Am.* 1969;51-A(4):737–755.
- Bahl S, Bhatnagar P, Sutter RW, Roesel S, Zaffran M, SigrunRoesel MZ.** Global polio eradication – way ahead. *Indian J Pediatr.* 2018;85(2):124–131.
- Haddad FS, Masri BA, Garbuz DS, Duncan CP.** Primary total replacement of the dysplastic hip. *Instr Course Lect.* 2000;49:23–39.
- Cabanela ME, Weber M.** Total hip arthroplasty in patients with neuromuscular disease. *Instr Course Lect.* 2000;49:163–168.
- Queally JM, Abdulkarim A, Mulhall KJ.** Total hip replacement in patients with neurological conditions. *J Bone Joint Surg Br.* 2009;91-B(10):1267–1273.
- Yoon B-H, Lee Y-K, Yoo JJ, Kim HJ, Koo K-H.** Total hip arthroplasty performed in patients with residual poliomyelitis: Does it work? *Clin Orthop Relat Res.* 2014;472(3):933–940.
- Faldini C, De Fine M, Di Martino A, et al.** Outcomes of total hip replacement in limbs affected by poliomyelitis. *HIP International.* 2017;27(2):198–204.
- Upadhyaya G, Patralekh M, Jain V, et al.** Total hip arthroplasty in patients with post-polio residual paralysis: a systematic review. *J Arthroplasty.* 2021;36(6):2239–2247.
- Hernigou P, Filippini P, Flouzat-Lachaniette CH, Batista SU, Poignard A.** Constrained liner in neurologic or cognitively impaired patients undergoing primary THA. *Clin Orthop Relat Res.* 2010;468(12):3255–3262.
- Berend KR, Lombardi AV, Mallory TH, Adams JB, Russell JH, Groseth KL.** The long-term outcome of 755 consecutive constrained acetabular components in total hip arthroplasty examining the successes and failures. *J Arthroplasty.* 2005;20(7 suppl 3):93–102.
- Guyen O, Pibarot V, Vaz G, Chevillotte C, Béjui-Hugues J.** Use of a dual mobility socket to manage total hip arthroplasty instability. *Clin Orthop Relat Res.* 2009;467(2):465–472.
- Zhou X, Wang Q, Zhang X, et al.** Severe pelvic obliquity affects femoral offset in patients with total hip arthroplasty but not leg-length inequality. *PLoS One.* 2015;10(12):e0144863.

Author information:

- R. Malhotra, MS, FRCS, Professor
- D. Gautam, MS, FACS, Assistant Professor
- S. Gupta, MS, DNB, Fellow Orthopedics department, All India Institute of Medical Sciences, New Delhi, India.
- K. K. Eachempati, MS, Director of Orthopedics, Orthopaedics department, Medicover Hospital, Madhapur, India.

Author contributions:

- R. Malhotra: Chief surgeon, Conceptualized and designed the study, Edited the manuscript.
- D. Gautam: Collected and analyzed the data, Prepared the manuscript.
- S. Gupta: Collected and analyzed the data, Prepared the manuscript.
- K. K. Eachempati: Senior surgeon, Conceptualized and designed the study.

Funding statement:

- No benefits in any form have been received or will be received from a commercial party related directly or indirectly to the subject of this article.

Open access funding:

- The authors confirm that open access funding for this manuscript was self-funded.

Acknowledgements:

- The authors would like to thank Dr Jaiben George for helping in the statistical analysis.

Ethical review statement:

- The conduct of this study was approved by the Institute Ethics Committee.

© 2021 Author(s) et al. This is an open-access article distributed under the terms of the Creative Commons Attribution Non-Commercial No Derivatives (CC BY-NC-ND 4.0) licence, which permits the copying and redistribution of the work only, and provided the original author and source are credited. See <https://creativecommons.org/licenses/by-nc-nd/4.0/>