



## ■ INFECTION

# Infection after intracapsular femoral neck fracture – does antibiotic-loaded bone cement reduce infection risk after hemiarthroplasty and total hip arthroplasty?

DATA FROM THE GERMAN ARTHROPLASTY REGISTRY

**D. Szymiski,  
N. Walter,  
P. Krull,  
O. Melsheimer,  
A. Grimberg,  
V. Alt,  
A. Steinbrueck,  
M. Rupp**

From University  
Hospital Regensburg,  
Regensburg, Germany

**Aims**

The aim of this investigation was to compare risk of infection in both cemented and uncemented hemiarthroplasty (HA) as well as in total hip arthroplasty (THA) following femoral neck fracture.

**Methods**

Data collection was performed using the German Arthroplasty Registry (EPRD). In HA and THA following femoral neck fracture, fixation method was divided into cemented and uncemented prostheses and paired according to age, sex, BMI, and the Elixhauser Comorbidity Index using Mahalanobis distance matching.

**Results**

Overall in 13,612 cases of intracapsular femoral neck fracture, 9,110 (66.9%) HAs and 4,502 (33.1%) THAs were analyzed. Infection rate in HA was significantly reduced in cases with use of antibiotic-loaded cement compared with uncemented fixated prosthesis ( $p = 0.013$ ). In patients with THA no statistical difference between cemented and uncemented prosthesis was registered, however after one year 2.4% of infections were detected in uncemented and 2.1% in cemented THA. In the subpopulation of HA after one year, 1.9% of infections were registered in cemented and 2.8% in uncemented HA. BMI ( $p = 0.001$ ) and Elixhauser Comorbidity Index ( $p < 0.003$ ) were identified as risk factors of periprosthetic joint infection (PJI), while in THA cemented prosthesis also demonstrated an increased risk within the first 30 days (hazard ratio (HR) = 2.73;  $p = 0.010$ ).

**Conclusion**

The rate of infection after intracapsular femoral neck fracture was statistically significantly reduced in patients treated by antibiotic-loaded cemented HA. Particularly for patients with multiple risk factors for the development of a PJI, the usage of antibiotic-loaded bone cement seems to be a reasonable procedure for prevention of infection.

**Cite this article:** *Bone Joint Res* 2023;12(5):331–338.

**Keywords:** Hip arthroplasty, Hemiarthroplasty, Bone cement, Femoral neck, Fracture, Periprosthetic joint infection

Correspondence should be sent to  
Markus Rupp; email:  
markus.rupp@ukr.de

doi: 10.1302/2046-3758.125.BJR-  
2022-0314.R1

*Bone Joint Res* 2023;12(5):331–  
338.

**Article focus**

■ To investigate the influence of antibiotic-loaded bone cement on the development of periprosthetic joint infections (PJIs)

after hemiarthroplasty (HA) and total hip arthroplasty (THA) for the treatment of femoral neck fractures.

- To determine risk factors for the development of PJIs.
- To describe the prevalence of PJIs following THA and HA after femoral neck fracture.

### Key messages

- Significant reduction of infection rate was observed in HAs with antibiotic-loaded bone compared with uncemented arthroplasties.
- A reduction of infection rate was also demonstrated in THAs, however without statistically significant results.
- BMI and comorbidities are major risk factors for the development of PJIs after femoral neck fracture.

### Strengths and limitations

- Over 13,000 cases with femoral neck fracture and following (hemi)arthroplasties were used for this analysis of the German Arthroplasty Register.
- Cemented and uncemented HAs and THAs were matched by age, sex, BMI, and Elixhauser Comorbidity Index to reduce confounding factors.
- Due to its age, the register has a limited amount of five-year data.

### Introduction

Demographic changes lead to an expected doubling of intracapsular femoral neck fracture cases until 2050 with annual numbers of 7.3 to 21.3 million fractures worldwide.<sup>1</sup> Within the last decade, the number of intracapsular femoral neck fractures has already increased by 23%. The elderly population aged 70 years and older are particularly at risk, and suffer from a four-times increased incidence.<sup>2</sup> In over 80% of cases in Germany, intracapsular femoral neck fractures are followed by a partial (hemiarthroplasty (HA)) or total hip arthroplasty (THA), while only a minority are treated by osteosynthesis.<sup>3</sup> In the USA, between 2003 and 2013 over 800,000 intracapsular femoral neck fractures were registered and are responsible for a one-year mortality of up to 22%.<sup>4,5</sup> Each fracture incurs initial hospital costs of between \$14,776 and \$17,097, and therefore results in a high financial burden for the health system.<sup>5</sup>

For joint arthroplasty procedures, a decision always has to be made between cemented and uncemented fixation. While, in the USA, HAs after hip fracture are mainly implanted without any cemented fixation,<sup>4,6</sup> in Germany and Norway the usage of bone cement is preferred.<sup>7</sup> Fernandez et al<sup>8</sup> have already demonstrated a statistically significantly reduced mortality and reduced rate of periprosthetic fractures for cemented HA in a randomized controlled trial. For THAs after femoral neck fracture, no clear predominance of a fixation technique has become apparent.<sup>3</sup> In addition to a reduced rate of periprosthetic fractures, faster mobilization and a statistically significant reduction of postoperative pain have been demonstrated as advantages of cemented hip arthroplasties after fracture.<sup>9,10</sup>

One major complication of HA and THA after femoral neck fracture is periprosthetic joint infection (PJI).<sup>11,12</sup>

Between HAs and THAs, no statistically significant differences with regard to infection rate were found at a 4.5-year follow-up after implantation of HA or THA, respectively.<sup>13</sup> The rate of postoperative infection was also lower in cemented HAs compared with uncemented fixations, with a hazard ratio (HR) of 1.2 within one year after fracture.<sup>7</sup>

However, the literature lacks a longitudinal approach based on registry data or a prospective clinical trial investigating the rate of infections following HA and THA with cemented and uncemented fixation after intracapsular femoral neck fracture. Therefore, the aim of the present investigation was: 1) to determine the rate of septic revisions after treatment of intracapsular femoral neck fractures with either HA or THA; and 2) to analyze and compare the influence of fixation method and other risk factors in infections between uncemented and cemented prosthesis fixation methods.

### Methods

**Data collection.** This study is based on the prospective German Arthroplasty Registry (EPRD) and investigates the revision rate of THA and HA for the treatment of intracapsular femoral neck fractures depending on their fixation method. Prosthesis implantations in Germany have been documented since 2012 in the EPRD in collaboration with statutory health insurance funds (AOK Bundesverband GbR (AOK-B), Verband der Ersatzkassen e.V vdek (vdek)), the German Medical Technology Association (BVMed), and several participating hospitals. Approximately 70% of all hip and knee arthroplasties performed in Germany are covered in the registry up to 2020.<sup>14</sup> Cross-validation of data provided by the surgeons was carried out by inclusion of two participating health insurance associations (AOK-B, vdek), which covers approximately 65% of the German population. Surgical revisions registered in the EPRD were followed up based on insurance billing data, even if they were performed in a hospital not participating in the arthroplasty registry. With the exception of procedures performed outside Germany, this algorithm ensures near-perfect tracking of patients insured by these companies.<sup>15</sup>

For the classification and identification of diagnoses and procedures, the German versions of the International Classification of Procedures in Medicine (ICPM), the Operation and Procedure Code (OPS) 301 system, and the International Classification of Diseases, Tenth Revision (ICD-10) were used.

**Patients.** All patients between November 2012 and September 2021 with HA and THA after intracapsular femoral neck fracture as main diagnosis (ICD-10: S72.0-) were included in the present analysis of the EPRD (Figure 1). Patients were divided into subpopulations with cemented and uncemented fixation of THA or HA and paired according to age, sex, BMI, and Elixhauser Comorbidity Index (in the van Walraven variant)<sup>16</sup> using Mahalanobis distance matching in a 1:1 ratio in patients with HA and THA. The Elixhauser Comorbidity Index pools a variety of

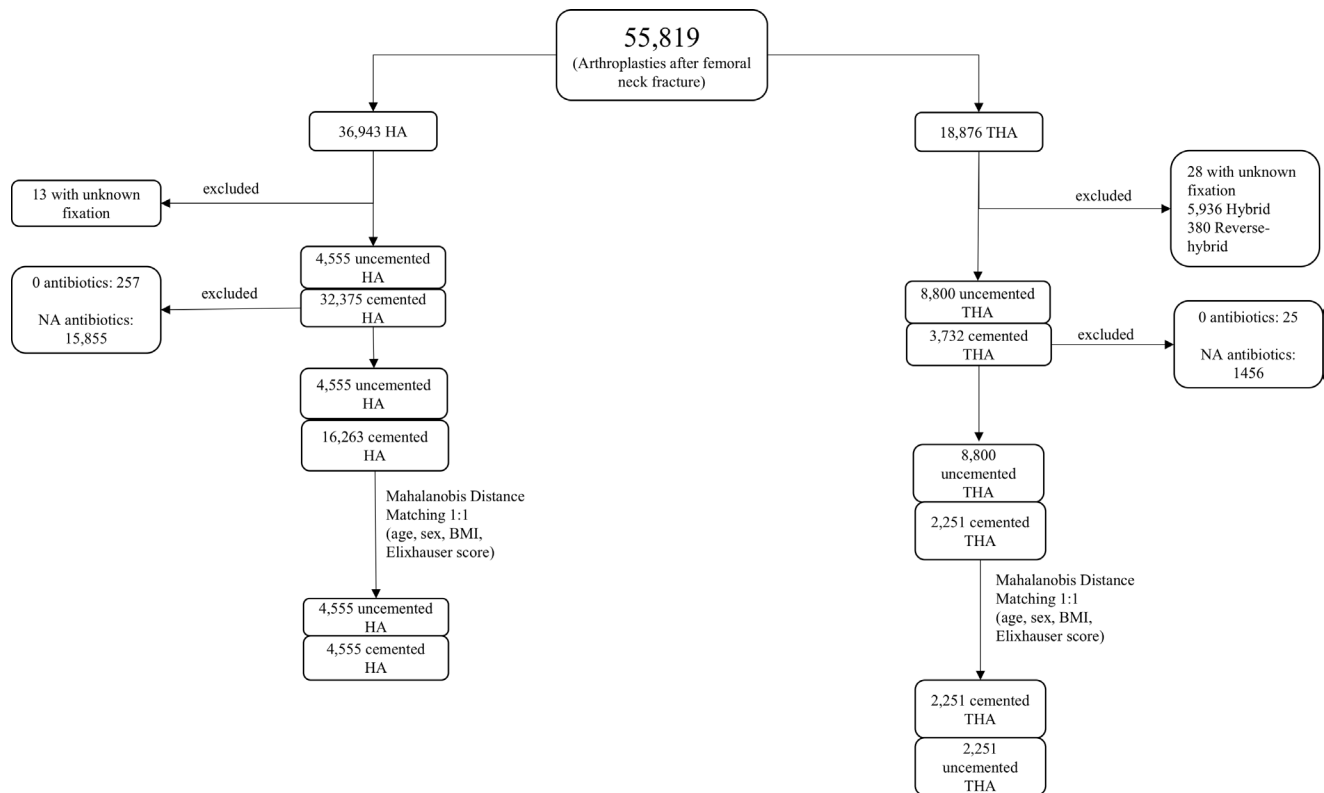


Fig. 1

Flowchart with composition of the study population. HA, hemiarthroplasty; N/A, not available; THA, total hip arthroplasty.

comorbidities of different organ systems and entities.<sup>16</sup> Coded comorbidities in the initial hospital stay during primary implantation of the arthroplasty were the basis for the calculation of the Elixhauser Comorbidity Index. All patients with cemented fixation of components included in the evaluation received antibiotic-loaded bone cement. The use of bone cement and antibiotic loading was determined by evaluation of the applied material during surgery using the classification information of the common product library of EPRD and the National Joint Registry (NJR). Infection rate was determined through searching the ICD-10 code for PJI (T84.5) in the registry. Through analysis of Operation and Procedure Code (OPS-Codes), a detailed registration of procedure and side of interest was obtained. Data provided by the registration of the surgeons were cross-validated by analysis of insurance data. Exclusion criteria were patients who were not treated with a femoral neck fracture as main diagnosis. Patients for whom no statement could be made regarding fixation of components or type of prosthesis were also excluded from the data collection. THAs with only one cemented component were not part of the analysis. Prosthesis with no antibiotic-loaded bone cement and no information on the use of included antibiotics were not part of the data analysis.

**Statistical analysis.** The data were analyzed to determine infection rates and influencing factors for cemented and uncemented HAs and THAs after intracapsular femoral

neck fractures in Germany. To account for bias in the selection of patients for a particular treatment (cemented or uncemented HA and THA), Mahalanobis distance matching of patients was performed using the variables of sex, age at the time of surgery, and the van Walraven weighted version of the Elixhauser Comorbidity Index<sup>16</sup> and, if the information was available, the patient's BMI. The statistical programme R package version 4.2.0 – package “comorbidity” (R Foundation for Statistical Computing, Austria) was used to perform the statistical analysis. Independent-samples *t*-test was used for statistical comparison of anthropometry between uncemented and cemented THA and HA. For post-matching statistical analysis, Kaplan-Meier estimates were calculated, and HRs were calculated for the matched data by using a Cox proportional hazards model. Initially, a Cox proportional hazards model without time split was performed. For all considered variables which did not meet the assumption of a time-constant effect, time split was executed in a second step. Log-rank test was used for the comparison of cemented and uncemented THA and HA. Categorical variables are presented in number of observations and frequency, continuous variables in mean and standard deviation. Significance level was assessed at the 5% level.

## Results

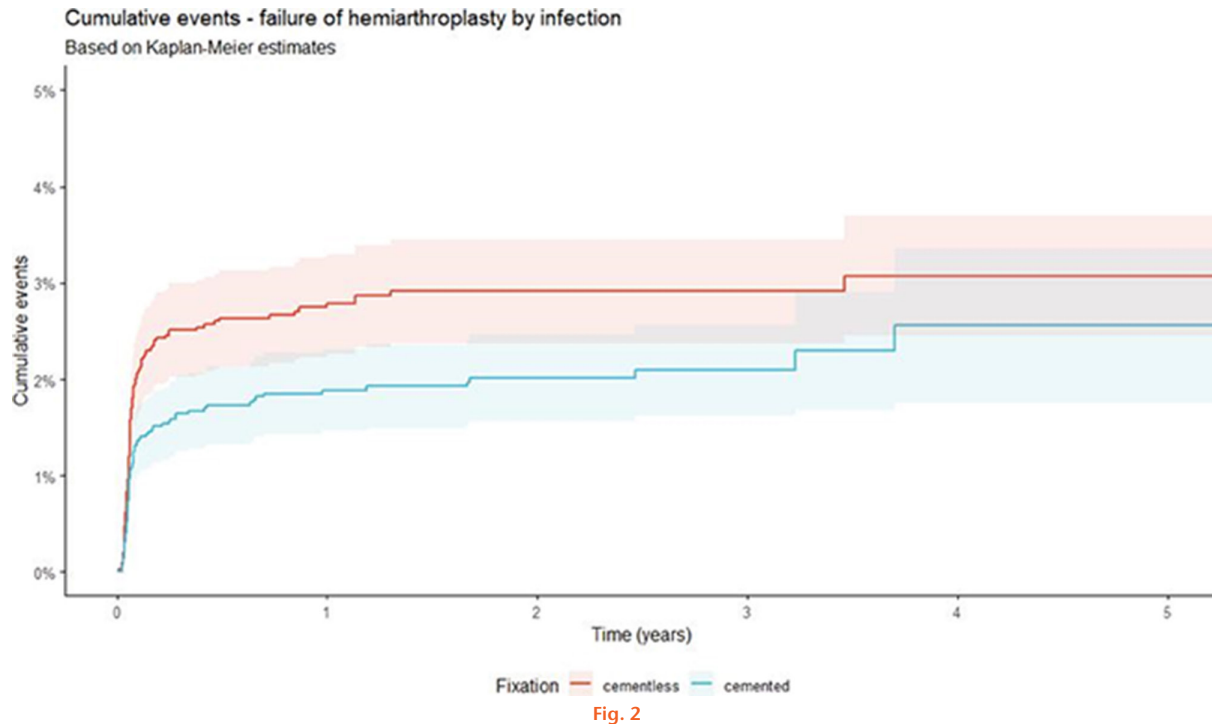
Overall, 55,819 patients with HAs and THAs after intracapsular femoral neck fracture were identified in the

**Table I.** Anthropometry and risk factors after matching (1:1) of the patient collective with hemiarthroplasty after femoral neck fracture.

Characteristic	Hemiarthroplasty			Total hip arthroplasty		
	Uncemented	Cemented	p-value*	Uncemented	Cemented	p-value*
Number	4,555	4,555	N/A	2,251	2,251	N/A
Mean age, yrs (SD)	82.3 (8.42)	82.4 (8.11)	0.543	79.7 (8.01)	80.3 (8.53)	0.020
Sex (female), n (%)	3,066 (67.3)	3,067 (67.3)	1.000	1,651 (73.3)	1,651 (73.3)	1.000
Elixhauser Comorbidity Index	8.35 (7.86)	8.36 (7.75)	0.968	7.26 (7.32)	7.46 (7.53)	0.352
BMI, kg/m <sup>2</sup> (SD)	25.0 (4.24)	24.9 (4.30)	0.266	24.8 (4.22)	24.8 (4.24)	0.827

\*Independent-samples *t*-test.

N/A, not applicable; SD, standard deviation.



Development of infection in cemented and uncemented hemiarthroplasties after femoral neck fractures over a period of five years ( $p = 0.013$ , log-rank test).

EPRD. After exclusion of incomplete datasets, 31,869 cases were used for matching. After the matching process using age, sex, Elixhauser Comorbidity Index, and BMI, in total 13,612 patients with 9,110 (66.9%) HAs and 4,502 (33.1%) THAs were included in further data analysis (Table I).

Within a five-year timeframe after HA, due to intracapsular femoral neck fracture the rate of postoperative infection was significantly higher in patients with uncemented stem fixation method compared with cemented HAs ( $p < 0.013$ , log-rank test; Figure 2). The rate of infection in uncemented HA increased from 1.9% after one month to 2.8% after one year and 3.1% after five years, while in cemented HA 1.3%, 1.9%, and 2.6% were registered during the same time (Table II).

Additionally, as influencing factors for failure due to infection, BMI (HR = 1.06;  $p = 0.001$ ) and Elixhauser Comorbidity Index (HR = 1.04;  $p < 0.001$ ) were identified by Cox proportional hazards model (Table III).

In patients with THA after femoral neck fracture, no significant difference between cemented and uncemented fixation was recognized with regard to infection rate within a five-year follow-up period ( $p = 0.640$ , log-rank test; Figure 3). The proportion of infections increased in cemented THA from 1.4% after one month to 2.1% after 12 months and 2.3% after five years. Uncemented THA showed equal trend with a 0.8% infection rate after one month, 2.4% after one year, and 2.6% five years after implantation (Table IV). As factors influencing the failure of THA by infection, BMI (HR = 1.10;  $p < 0.001$ ), Elixhauser Comorbidity Index (HR = 1.05;  $p = 0.003$ ), and in the first 30 days following implantation cemented fixation (HR = 2.73;  $p = 0.010$ ) were identified by Cox proportional hazards model. However, after 30 days the use of bone cement showed a risk reduction with a HR of 0.49 (95% confidence interval (CI) 0.23 to 1.03) (Table III).

**Table II.** Infection rate and absolute number of infections after hemiarthroplasty for femoral neck fracture.

Prosthesis	Timepoint						
	1 mth	2 mths	3 mths	6 mths	1 yr	3 yrs	5 yrs
<b>Uncemented</b>							
Cumulative events, % (95% CI; n)	1.9 (1.5 to 2.4; 79)	2.3 (1.9 to 2.8; 95)	2.5 (2.0 to 3.0; 99)	2.6 (2.1 to 3.1; 105)	2.8 (2.3 to 3.3; 109)	2.9 (2.4 to 3.4; 112)	3.1 (2.4 to 3.7; 113)
<b>Cemented</b>							
Cumulative events, % (95% CI; n)	1.3 (0.9 to 1.6; 53)	1.5 (1.1 to 1.8; 60)	1.6 (1.2 to 1.9; 64)	1.7 (1.3 to 2.1; 70)	1.9 (1.5 to 2.3; 75)	2.1 (1.6 to 2.6; 79)	2.6 (1.8 to 3.4; 81)

CI, confidence interval.

**Table III.** Cox proportional hazards model for the failure by infection of hemiarthroplasty and total hip arthroplasty after intracapsular femoral neck fracture.

Variable	Hemiarthroplasty			Total hip arthroplasty		
	Hazard ratio	95% CI	p-value	Hazard ratio	95% CI	p-value
Age at admission	0.98	0.96 to 1.00	0.051	0.98	0.95 to 1.01	0.194
Sex: female	0.75	0.53 to 1.06	0.099	0.91	0.52 to 1.58	0.726
BMI	1.06	1.02 to 1.09	0.001	1.10	1.05 to 1.15	< 0.001
Elixhauser Comorbidity Index	1.04	1.02 to 1.06	< 0.001	1.05	1.02 to 1.08	0.003
<b>Fixation method: cemented*</b>						
≤ 30 days	0.76	0.55 to 1.06	0.105	2.73	1.27 to 5.87	0.010
> 30 days	0.76	0.55 to 1.06	0.105	0.49	0.23 to 1.03	0.060

\*Fixation violated proportional hazards assumption for total hip arthroplasty, and was adjusted with a time split at 30 days to allow two different hazards for ≤ 30 days and > 30 days.  
CI, confidence interval.

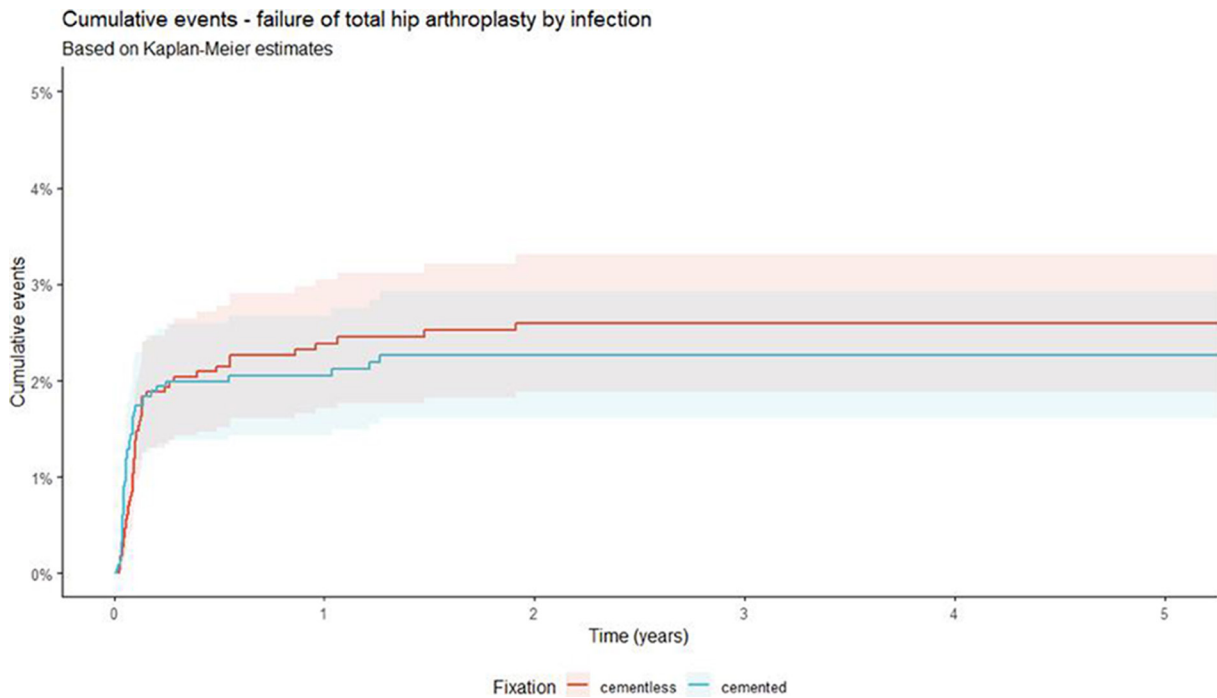


Fig. 3

Development of infection in cemented and uncemented total hip arthroplasties after femoral neck fractures over a period of five years (p = 0.640, log-rank test).

**Discussion**

Over 13,000 patients with intracapsular femoral neck fracture registered in the EPRD with treatment by HA or

THA were included in this investigation. While for HAs a significantly increased rate of septic revision was diagnosed after uncemented fixation, in patients suffering

**Table IV.** Infection rate and absolute number of infections after total hip arthroplasty for femoral neck fracture.

Prosthesis	Timepoint						
	1 mth	2 mths	3 mths	6 mths	1 yr	3 yrs	5 yrs
<b>Uncemented</b>							
Cumulative events, % (95% CI; n)	0.8 (0.5 to 1.2; 18)	1.9 (1.3 to 2.5; 39)	1.9 (1.3 to 2.5; 40)	2.1 (1.5 to 2.8; 44)	2.4 (1.7 to 3.0; 48)	2.6 (1.9 to 3.3; 51)	2.6 (1.9 to 3.3; 51)
<b>Cemented</b>							
Cumulative events, % (95% CI; n)	1.4 (0.9 to 1.9; 30)	1.8 (1.3 to 2.4; 38)	2.0 (1.4 to 2.6; 41)	2.0 (1.4 to 2.6; 41)	2.1 (1.4 to 2.7; 42)	2.3 (1.6 to 2.9; 45)	2.3 (1.6 to 2.9; 45)

CI, confidence interval.

femoral neck fractures and treated by THA, no statistical difference in the infection rate was detected when comparing cemented with uncemented fixation.

The literature describes an infection rate between 0.9% and 10% for postoperative infections after HA with a pooled rate of 2.87% (95% CI 1.99 to 3.75).<sup>17-19</sup> For patients treated with THA, the percentage of septic revision is reported to be between 1.4% and 6.6%.<sup>20,21</sup> Our study demonstrated similar data within the five-year follow-up period and a rate of up to 3.1% for septic revisions after HA and up to 2.6% after THA. Crego-Vita et al<sup>22</sup> previously described the positive effect of antibiotic-loaded bone cement on infection rate compared with plain bone cement in HAs after femoral neck fracture. In our investigation, a significantly reduced rate of infection was registered in patients treated with antibiotic-loaded cemented HA compared with an uncemented fixated prosthesis ( $p = 0.013$ , log-rank test). Patients treated with THA also had a higher risk of infection in uncemented THA with a percentage of 2.6% after five years compared with 2.3%, however this was not statistically significant ( $p = 0.640$ , log-rank test). Contrary to expectations within the first 30 days after surgery, an increased risk of infection was detected for cases with cemented THA (HR = 2.73;  $p = 0.010$ , Cox proportional hazards model). Outside the 30-day period immediately after implantation, however, patients with cemented THA showed a risk reduction with a HR of 0.486. A possible reason for the increased risk in the first 30 days might be the indications for the usage of cemented THA. Especially in patients with reduced bone quality, the use of cemented prosthesis is indicated. A potentially reduced peripheral blood supply and a higher number of comorbidities could be a reason for the increased infection rate immediately after implantation.<sup>10</sup> With regard to infection rate in HAs after femoral neck fractures, a clear advantage of fixation with antibiotic-loaded bone cement was found compared with uncemented fixation methods. However, in the USA in 2018 only 51.6% of all HAs were treated with cemented HAs, while in Germany between 2009 and 2019 86.2% of all HAs were implanted with application of bone cement.<sup>3,4</sup> Due to the low numbers of registered cemented arthroplasty procedures using antibiotic-free cement, no further comparison could be performed between antibiotic-loaded and antibiotic-free bone cement. Another geographical difference comparing

the USA and Germany is the usage of antibiotic-loaded bone cement, which in Germany is the gold standard and includes at least one antibiotic, whereas in the USA, according to the American Joint Arthroplasty Registry, antibiotic-enhanced bone cement was only used in 44% of cemented cases.<sup>6</sup>

The advantage of reduction of the infection rate when using antibiotic-loaded cement in the fixation of HAs, and an identical mechanical stability, no verifiable antibiotic resistance using an antibiotic-enhanced bone cement, and unquestionable toxicological properties have resulted in the clinical recommendation to use antibiotic-enriched bone cements for the prophylaxis of PJI.<sup>23,24</sup> Ever since, however, the use of antibiotic-loaded bone cement has been the subject of controversial discussions. The local administration of antibiotics in commercially available bone cement offers a complementary option to the systematic prophylaxis (mostly with cefazolin or cefuroxime) for the reduction of postoperative infection risk and treatment of potentially antibiotic-resistant bacteria.<sup>25</sup> High local doses of antibiotics in the affected joint can be achieved by use of antibiotic-loaded bone cements, which are especially favourable against establishing biofilms.<sup>26</sup> For this purpose, several antibiotic-loaded bone cement products have been approved by the Food and Drug Administration (FDA), and mostly consist of a single antibiotic application (0.5 or 1 g gentamicin or 1 g tobramycin) or a double antibiotic-loaded bone cement (1 g gentamicin + 1 g clindamycin or 0.5 g gentamicin + 2 g vancomycin).<sup>27</sup> Substantial side effects of local administration of antibiotic-loaded bone cements are renal failure and *Clostridium difficile* infections. However, in a RCT no statistically significant differences were registered concerning the occurrence of any side effect between low single-dose antibiotic-loaded bone cement and high-dose double-loaded bone cement.<sup>28</sup> On the other hand, a statistically significantly reduced number of superficial and deep surgical site infections and critical care unit stays were found in the group with high-dose double-loaded antibiotic bone cement.<sup>28</sup>

Compared with HA, the infection rate in THA was lower in our analysis. No statistically significant reduction of PJI was found for the usage of antibiotic-loaded bone cement in THA treating femoral neck fractures. A possible reason for this trend could be the physical condition of the patient, which also makes a comparison between

HA and THA after intracapsular femoral neck fracture complicated. The anthropometric data of our investigation demonstrate that patients who received treatment with HA had a higher age and higher Elixhauser Comorbidity Index. Recommendations suggest implantation of HAs for patients of older age with reduced life expectancy (< five years) and severe comorbidities, and consequently with increased intraoperative risk factors.<sup>21,29,30</sup> However, for primary THA a reduction of infections was reported through the use of antibiotic-loaded bone cement by 72.6% compared with plain bone cement.<sup>31</sup> When comparing HA and THA in patients with complex comorbidities and neurological diseases, no statistically significant differences in revision rates were detected in an analysis of the Swedish Hip Arthroplasty Register.<sup>32</sup> Furthermore, a socioeconomic advantage in terms of cost savings of at least €2,600 per patient has been postulated by the use of antibiotic-loaded bone cement compared with plain bone cement.<sup>31</sup> In addition to cost savings, a statistically significantly increased quality of life has been reported for patients with cemented implants in the World Hip Trauma Evaluation 5 (WHiTE 5) trial.<sup>33</sup> Therefore, a clear clinical recommendation for the application of antibiotic-loaded bone cement in cemented THA and HA for the prevention of PJI is given. The introduction of an interdisciplinary board with clear guidelines has been established to optimize postoperative outcomes after femoral neck fracture and to speed up the decision-making process for treatment.<sup>34</sup> In particular, the decision-making between THA and HA can be improved.<sup>35</sup>

As risk factors for PJIs, older age, increased BMI, and a high number of (cardiovascular) comorbidities were evaluated recently.<sup>36,37</sup> This specific group of patients suffers from a modified or weakened immune system and reduced blood flow in the periphery, e.g. in limbs. Therefore, the risk of delayed wound healing and rate of infection is reported to be increased in this patient group.<sup>38,39</sup> In a Cox proportional hazards model, an increased number of comorbidities, which were registered through the Elixhauser Comorbidity Index, and an increased BMI were statistically significant risk factors of infection for both HA and THA performed after femoral neck fracture. Especially in the patient population characterized by several risk factors for development of infection, the use of an antibiotic-loaded bone cement should be taken into consideration.<sup>23</sup> Since the aetiology of PJI is multifactorial and influenced by the aforementioned patient-specific risk factors, operating time, surgeon experience, postoperative haematoma formation, and reoperations are noted as playing a critical role in the development of PJI.<sup>40</sup> Other advantages such as lower periprosthetic fracture risk using bone cement in HA and the evidenced lower infection risk in the present investigation support the clinical application of antibiotic-loaded bone cement for fixation of HA and THA after femoral neck fracture.<sup>41</sup>

Despite multiple advantages of the EPRD, some limitations were noted due to study design. The quality of data in this registry is dependent on registration by surgeons

and correct coding of procedures. To minimize this effect and limitation, included patient data were cross-validated by using insurance data. The Elixhauser Comorbidity Index was calculated by using the comorbidities coded in the initial hospital stay during primary implantation and is therefore a further limitation. We matched patients by age, sex, BMI, cementation, and comorbidities attempted to create as homogeneous a comparison group as possible in each subpopulation. Nevertheless, not all comorbidities are queried with the Elixhauser Comorbidity Index, and osteoporosis may distort the result of the matching and the decision of cementation. Nevertheless, matching using multiple variables and a wide comorbidity index created groups that were as comparable as possible. Another limitation is the length of time for which the registry has existed, which does not currently allow investigation of follow-ups longer than five years. Matching between HA and THA patients was not performed because of the different indications for the surgical technique.

In conclusion, infections after (hemi)arthroplasty following intracapsular femoral neck fracture are a severe problem in trauma surgery. Increased BMI and elevated number and severity of comorbidities were demonstrated to be risk factors for the development of a PJI after femoral fracture. In patients treated with HA, the use of antibiotic-loaded bone cement reduces the infection rate statistically significantly, while after THA a statistically non-significant reduction was observed compared with uncemented fixed prosthesis. Particularly for patients with risk factors for PJI, the application of antibiotic-loaded bone cement seems to be a suitable and safe option for prevention of infection.

## References

1. Gullberg B, Johnell O, Kanis JA. World-wide projections for hip fracture. *Osteoporos Int.* 1997;7(5):407–413.
2. Rupp M, Walter N, Pfeifer C, et al. The Incidence of Fractures Among the Adult Population of Germany—an Analysis From 2009 through 2019. *Dtsch Arztebl Int.* 2021;118(40):665–669.
3. Szynski D, Walter N, Lang S, et al. Incidence and treatment of intracapsular femoral neck fractures in Germany. *Arch Orthop Trauma Surg.* 2023;143(5):2529–2537.
4. Okike K, Chan PH, Prentice HA, Paxton EW, Burri RA. Association Between Uncemented vs Cemented Hemiarthroplasty and Revision Surgery Among Patients With Hip Fracture. *JAMA.* 2020;323(11):1077–1084.
5. Ju DG, Rajae SS, Mirocha J, Lin CA, Moon CN. Nationwide Analysis of Femoral Neck Fractures in Elderly Patients: A Receding Tide. *J Bone Joint Surg Am.* 2017;99(22):1932–1940.
6. No authors listed. *American Joint Replacement Registry (AJRR): 2018 Annual Report.* Rosemont, Illinois: American Academy of Orthopaedic Surgeons (AAOS), 2018.
7. Kristensen TB, Dybvik E, Kristoffersen M, et al. Reply to the Letter to the Editor: Cemented or Uncemented Hemiarthroplasty for Femoral Neck Fracture? Data from the Norwegian Hip Fracture Register. *Clin Orthop Relat Res.* 2020;478(3):687–689.
8. Fernandez MA, Achten J, Parsons N, et al. Cemented or Uncemented Hemiarthroplasty for Intracapsular Hip Fracture. *N Engl J Med.* 2022;386(6):521–530.
9. Parker MJ, Gurusamy KS, Azegami S. Arthroplasties (with and without bone cement) for proximal femoral fractures in adults. *Cochrane Database Syst Rev.* 2010;6:CD001706.
10. Heckmann ND, Chen XT, Ballatori AM, et al. Cemented Vs Cementless Femoral Fixation for Total Hip Arthroplasty After Displaced Femoral Neck Fracture:

- A Nationwide Analysis of Short-Term Complications and Readmission Rates. *J Arthroplasty*. 2021;36(11):3667–3675.
11. **Gausden EB, Cross WW, Mabry TM, Pagnano MW, Berry DJ, Abdel MP.** Total Hip Arthroplasty for Femoral Neck Fracture: What Are the Contemporary Reasons for Failure? *J Arthroplasty*. 2021;36(7S):S272–S276.
  12. **Iamthaporn K, Chareancholvanich K, Pornrattanameewong C.** Reasons for revision of failed hemiarthroplasty: Are there any differences between unipolar and bipolar? *Eur J Orthop Surg Traumatol*. 2018;28(6):1117–1123.
  13. **Lewis DP, Wæver D, Thorninger R, Donnelly WJ.** Hemiarthroplasty vs Total Hip Arthroplasty for the Management of Displaced Neck of Femur Fractures: A Systematic Review and Meta-Analysis. *J Arthroplasty*. 2019;34(8):1837–1843.
  14. **Grimberg A, Jansson V, Lütznier J, Melsheimer O, Morlock M, Steinbrück A.** Jahresbericht 2021: Mit Sicherheit mehr Qualität. Endoprothesenregister Deutschland (EPRD). 2021. [https://www.eprd.de/fileadmin/user\\_upload/Dateien/Publikationen/Berichte/Jahresbericht2021\\_2021-10-25\\_F.pdf](https://www.eprd.de/fileadmin/user_upload/Dateien/Publikationen/Berichte/Jahresbericht2021_2021-10-25_F.pdf) (date last accessed 13 February 2022).
  15. **Jansson V, Grimberg A, Melsheimer O, Perka C, Steinbrück A.** Orthopaedic registries: the German experience. *EFORT Open Rev*. 2019;4(6):401–408.
  16. **van Walraven C, Austin PC, Jennings A, Quan H, Forster AJ.** A modification of the Elixhauser comorbidity measures into a point system for hospital death using administrative data. *Med Care*. 2009;47(6):626–633.
  17. **Guren E, Figved V, Frihagen F, Watne LO, Westberg M.** Prosthetic joint infection—a devastating complication of hemiarthroplasty for hip fracture. *Acta Orthop*. 2017;88(4):383–389.
  18. **Craxford S, Marson BA, Nightingale J, et al.** Deep infection after hip hemiarthroplasty: risk factors for infection and outcome of treatments. *Bone Jt Open*. 2021;2(11):958–965.
  19. **Masters J, Metcalfe D, Ha JS, Judge A, Costa ML.** Surgical site infection after hip fracture surgery. *Bone & Joint Research*. 2020;9(9):554–562.
  20. **Savage P, McCormick M, Al-Dadah O.** Arthroplasty infection rates in fractured neck of femur: single vs dual antibiotic cement. *Ann R Coll Surg Engl*. 2019;101(7):514–518.
  21. **Liodakis E, Antoniou J, Zukor DJ, Huk OL, Epure LM, Bergeron SG.** Major Complications and Transfusion Rates After Hemiarthroplasty and Total Hip Arthroplasty for Femoral Neck Fractures. *J Arthroplasty*. 2016;31(9):2008–2012.
  22. **Crego-Vita D, Aedo-Martín D, Garcia-Cañás R, Espigares-Correa A, Sánchez-Pérez C, Berberich CE.** Periprosthetic joint infections in femoral neck fracture patients treated with hemiarthroplasty - should we use antibiotic-loaded bone cement? *World J Orthop*. 2022;13(2):150–159.
  23. **Hanssen AD.** Prophylactic use of antibiotic bone cement: an emerging standard—in opposition. *J Arthroplasty*. 2004;19(4 Suppl 1):73–77.
  24. **Tootsi K, Heesen V, Lohrengel M, et al.** The use of antibiotic-loaded bone cement does not increase antibiotic resistance after primary total joint arthroplasty. *Knee Surg Sports Traumatol Arthrosc*. 2022;30(9):3208–3214.
  25. **Nodzo SR, Boyle KK, Frisch NB.** Nationwide Organism Susceptibility Patterns to Common Preoperative Prophylactic Antibiotics: What Are We Covering? *J Arthroplasty*. 2019;34(7S):S302–S306.
  26. **Svensson Malchau K, Tillander J, Zaborowska M, et al.** Biofilm properties in relation to treatment outcome in patients with first-time periprosthetic hip or knee joint infection. *J Orthop Translat*. 2021;30:31–40.
  27. **Berberich CE, Josse J, Laurent F, Ferry T.** Dual antibiotic loaded bone cement in patients at high infection risks in arthroplasty: Rationale of use for prophylaxis and scientific evidence. *World J Orthop*. 2021;12(3):119–128.
  28. **Sprowson AP, Jensen C, Chambers S, et al.** The use of high-dose dual-impregnated antibiotic-laden cement with hemiarthroplasty for the treatment of a fracture of the hip: The Fractured Hip Infection trial. *Bone Joint J*. 2016;98-B(11):1534–1541.
  29. **Ossendorf C, Scheyerer MJ, Wanner GA, Simmen H-P, Werner CM.** Treatment of femoral neck fractures in elderly patients over 60 years of age - which is the ideal modality of primary joint replacement? *Patient Saf Surg*. 2010;4(1):16.
  30. **Bhandari M, Devereaux PJ, Tornetta P, et al.** Operative management of displaced femoral neck fractures in elderly patients. An international survey. *J Bone Joint Surg Am*. 2005;87(9):2122–2130.
  31. **Sanz-Ruiz P, Matas-Diez JA, Sanchez-Somolinos M, Villanueva-Martinez M, Vaquero-Martín J.** Is the Commercial Antibiotic-Loaded Bone Cement Useful in Prophylaxis and Cost Saving After Knee and Hip Joint Arthroplasty? The Transatlantic Paradox. *J Arthroplasty*. 2017;32(4):1095–1099.
  32. **Cnudde PHJ, Nätman J, Hailer NP, Rogmark C.** Total, hemi, or dual-mobility arthroplasty for the treatment of femoral neck fractures in patients with neurological disease: analysis of 9,638 patients from the Swedish Hip Arthroplasty Register. *Bone Joint J*. 2022;104-B(1):134–141.
  33. **Png ME, Petrou S, Fernandez MA, et al.** Cost-utility analysis of cemented hemiarthroplasty versus hydroxyapatite-coated uncemented hemiarthroplasty for the treatment of displaced intracapsular hip fractures: the World Hip Trauma Evaluation 5 (WHITe 5) trial. *Bone Joint J*. 2022;104-B(8):922–928.
  34. **Roberts HJ, Barry J, Nguyen K, et al.** 2021 John Charnley Award: A protocol-based strategy when using hemiarthroplasty or total hip arthroplasty for femoral neck fractures decreases mortality, length of stay, and complications. *Bone Joint J*. 2021;103-B(7 Suppl B):3–8.
  35. **Frihagen F, Comeau-Gauthier M, Axelrod D, et al.** Who, if anyone, may benefit from a total hip arthroplasty after a displaced femoral neck fracture?: a post hoc subgroup analysis of the HEALTH trial. *Bone Jt Open*. 2022;3(8):611–617.
  36. **Triantafyllopoulos GK, Soranoglou VG, Memsoudis SG, Sculco TP, Poultsides LA.** Rate and Risk Factors for Periprosthetic Joint Infection Among 36,494 Primary Total Hip Arthroplasties. *J Arthroplasty*. 2018;33(4):1166–1170.
  37. **Dobson PF, Reed MR.** Prevention of infection in primary THA and TKA. *EFORT Open Rev*. 2020;5(10):604–613.
  38. **Kunutsor SK, Whitehouse MR, Blom AW, Beswick AD, INFORM Team.** Patient-Related Risk Factors for Periprosthetic Joint Infection after Total Joint Arthroplasty: A Systematic Review and Meta-Analysis. *PLoS One*. 2016;11(3):e0150866.
  39. **Kapadia BH, Berg RA, Daley JA, Fritz J, Bhavs A, Mont MA.** Periprosthetic joint infection. *Lancet*. 2016;387(10016):386–394.
  40. **de Jong L, Klem T, Kuijper TM, Roukema GR.** Factors affecting the rate of surgical site infection in patients after hemiarthroplasty of the hip following a fracture of the neck of the femur. *Bone Joint J*. 2017;99-B(8):1088–1094.
  41. **Inngul C, Blomfeldt R, Ponzer S, Enocson A.** Cemented versus uncemented arthroplasty in patients with a displaced fracture of the femoral neck: a randomised controlled trial. *Bone Joint J*. 2015;97-B(11):1475–1480.

#### Author information:

- D. Szymiski, MD, Physician
- N. Walter, MSc, Research Associate
- V. Alt, MD, Clinical Professor
- M. Rupp, MD, Senior Physician
- Department of Trauma Surgery, University Hospital Regensburg, Regensburg, Germany.
- P. Krull, cand. med., Research Associate
- O. Melsheimer, MSc, Head of Medical Biometry and Statistics
- A. Grimberg, MD, Head of Medical Affairs
- Deutsches Endoprothesenregister gGmbH, Berlin, Germany.
- A. Steinbrueck, MD, Clinical Professor, Scientific Study Coordinator, Deutsches Endoprothesenregister gGmbH, Berlin, Germany; Orthopädisch Chirurgisches Kompetenzzentrum Augsburg (OCKA), Augsburg, Germany.

#### Author contributions:

- D. Szymiski: Conceptualization, Methodology, Validation, Investigation, Writing – original draft.
- N. Walter: Methodology, Validation, Writing – review & editing.
- P. Krull: Conceptualization, Methodology, Software, Formal analysis, Validation, Visualization, Investigation, Writing – review & editing.
- O. Melsheimer: Conceptualization, Methodology, Software, Formal analysis, Validation, Investigation, Writing – review & editing.
- A. Grimberg: Project administration, Funding acquisition, Writing – review & editing.
- V. Alt: Project administration, Writing – review & editing.
- A. Steinbrueck: Conceptualization, Methodology, Investigation, Writing – review & editing, Project administration.
- M. Rupp: Conceptualization, Methodology, Investigation, Writing – review & editing, Project administration.

#### Funding statement:

- The authors choose not to disclose receipt of any financial or material support for the research, authorship, and/or publication of this article.

#### ICMJE COI statement:

- A. Grimberg, O. Melsheimer, and A. Steinbrueck report participation in the Implant-Outlet-Workgroup of the German Arthroplasty Registry (EPRD), not related to this study.

#### Ethical review statement:

- The study design of the German Arthroplasty Registry was approved by the University of Kiel (ID: D 473/11).

#### Open access funding:

- The authors report that they received open access funding for their manuscript from the University of Regensburg.

© 2023 Author(s) et al. This is an open-access article distributed under the terms of the Creative Commons Attribution Non-Commercial No Derivatives (CC BY-NC-ND 4.0) licence, which permits the copying and redistribution of the work only, and provided the original author and source are credited. See <https://creativecommons.org/licenses/by-nc-nd/4.0/>