



## ■ HIP

# Coxa valga and antetorta increases differences among different femoral version measurements

## POTENTIAL IMPLICATIONS FOR DEROTATIONAL FEMORAL OSTEOTOMY PLANNING

**F. Schmaranzer,  
M. K. Meier,  
T. D. Lerch,  
A. Hecker,  
S. D. Steppacher,  
E. N. Novais,  
A. M. Kiapour**

*From Boston Children's Hospital, Harvard Medical School, Boston, Massachusetts, USA*

### Aims

To evaluate how abnormal proximal femoral anatomy affects different femoral version measurements in young patients with hip pain.

### Methods

First, femoral version was measured in 50 hips of symptomatic consecutively selected patients with hip pain (mean age 20 years (SD 6), 60% (n = 25) females) on preoperative CT scans using different measurement methods: Lee et al, Reikerås et al, Tomczak et al, and Murphy et al. Neck-shaft angle (NSA) and  $\alpha$  angle were measured on coronal and radial CT images. Second, CT scans from three patients with femoral retroversion, normal femoral version, and anteversion were used to create 3D femur models, which were manipulated to generate models with different NSAs and different cam lesions, resulting in eight models per patient. Femoral version measurements were repeated on manipulated femora.

### Results

Comparing the different measurement methods for femoral version resulted in a maximum mean difference of 18° (95% CI 16 to 20) between the most proximal (Lee et al) and most distal (Murphy et al) methods. Higher differences in proximal and distal femoral version measurement techniques were seen in femora with greater femoral version ( $r > 0.46$ ;  $p < 0.001$ ) and greater NSA ( $r > 0.37$ ;  $p = 0.008$ ) between all measurement methods. In the parametric 3D manipulation analysis, differences in femoral version increased 11° and 9° in patients with high and normal femoral version, respectively, with increasing NSA (110° to 150°).

### Conclusion

Measurement of femoral version angles differ depending on the method used to almost 20°, which is in the range of the aimed surgical correction in derotational femoral osteotomy and thus can be considered clinically relevant. Differences between proximal and distal measurement methods further increase by increasing femoral version and NSA. Measurement methods that take the entire proximal femur into account by using distal landmarks may produce more sensitive measurements of these differences.

**Cite this article:** *Bone Jt Open* 2022;3-10:759–766.

**Keywords:** Femoral version, Femoral derotational osteotomy, Hip joint preserving surgery, Femoral acetabular impingement

Correspondence should be sent to Malin Kristin Meier; email: malinkristin.meier@gmail.com

doi: 10.1302/2633-1462.310.BJO-2022-0102.R1

*Bone Jt Open* 2022;3-10:759–766.

### Introduction

In recent years, there has been an increased focus on femoral version abnormalities, since they have been recognized as a cause

of hip pain in young adults and have been integrated into the concept of femoroacetabular impingement (FAI) and hip instability.<sup>1</sup> Femoral version abnormalities can be the

**Table I.** Demographic characteristics.

Characteristic	Study group
Total, patients (hips)	42 (50)
Mean age at surgery, yrs (SD)	20 (6)
Skeletally mature, % (n)	96 (48/50)
Female sex, % (n)	60 (30/50)
Previous hip surgery, % (n)	0 (0/50)
<b>Hip condition, % (n)</b>	
Dysplasia	36 (18/50)
Femoroacetabular impingement	64 (32/50)
Subsequent surgery	56 (28/50)
Surgical hip dislocation	14 (4/28)
Periacetabular osteotomy	46 (13/28)
Hip arthroscopy	29 (8/28)

SD, standard deviation.

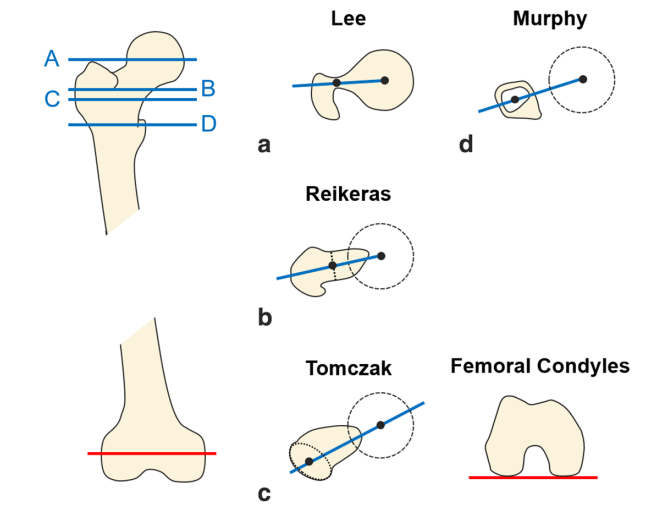
cause of FAI, e.g. posterior extra-articular impingement in patients with increased femoral version, or anterior extra-articular subspine impingement in patients with femoral retroversion.<sup>2-4</sup> On the other hand, femoral anteversion can contribute to hip instability in patients with developmental hip dysplasia (DDH) and high acetabular version.<sup>5</sup> In addition, these deformities can occur in combination and aggravate or cancel each other out.

Although indications are still evolving, femoral derotational osteotomies are increasingly performed in the setting of FAI and DDH to correct for femoral version abnormalities and improve biomechanics.<sup>5-10</sup> Consequently, the exact quantification of femoral version is crucial for diagnosis and surgical planning. Several methods for measuring femoral version have been described. These methods differ regarding the selected anatomical landmarks, which affect resulting femoral version angles.<sup>11</sup> To date, it is unclear how these measurement methods are affected based on common osseous deformities of the femur, and which femoral version measurement method best reflects overall femoral malalignment.

Thus, we aimed firstly to determine method-related differences in femoral version, and secondly to evaluate how varus/valgus deformity (i.e. neck-shaft angle), extent of femoral version, and presence of cam deformity affect femoral version measurements. We hypothesized that femoral version varies significantly based on measurement technique, and that those method-related differences are associated with extent of femoral version, varus/valgus deformity (i.e. neck-shaft angle), and cam deformity (i.e.  $\alpha$  angle).

## Methods

**Study population.** This retrospective study was conducted following institutional review board approval, and was based on a two-step approach. First, we screened our institutional database for patients with hip pain and osseous hip deformities who underwent a preoperative

**Fig. 1**

Schematic illustration of the different methods of femoral version measurement.

CT scan, including the distal femoral condyles, between May 2017 and August 2018. This search yielded 74 hips (61 patients). A total of 24 hips (19 patients) with previous hip surgery were excluded, leading to a total study population of 50 hips (42 patients). Mean age was 20 years (standard deviation (SD) 6) and 60% (25/42) of patients were female. Diagnosis of hip pain was established by a senior paediatric hip surgeon (ENN) based on a history of symptoms for longer than three months, and a positive impingement test result and/or a positive apprehension test result, in the presence of osseous deformities indicative for FAI or DDH.<sup>12,13</sup> Of the included hips, 36% (18/50) of the included hips were diagnosed with hip dysplasia and 64% (32/50) of hips had symptomatic FAI (Table I); 56% (28/50) of hips had subsequent surgery, 14% (4/28) underwent surgical hip dislocation, 46% (13/28) underwent periacetabular osteotomy, and 29% (8/28) underwent hip arthroscopy.

**CT acquisition.** All patients underwent non-contrast CT of the pelvis and the entire femur on a dual-source CT scanner (Somatom Force; Siemens Healthcare, Germany) or a 64-slice multidetector row CT scanner (Sensation; Siemens Healthcare) using automated attenuation-based tube current modulation for reduction of radiation dose. Image analysis was performed on axially reformatted images with 1 mm slice thickness.

**Anatomical index measurements in the study population.** Femoral version was measured in all patients by a radiology resident (FS) with eight years of experience in diagnostic imaging of the hip using four common methods for femoral version measurement. These methods differ regarding the level of anatomical landmark for the proximal femoral neck axis (Figure 1). The method of Lee et al<sup>14</sup> uses the most proximal definition at the junction

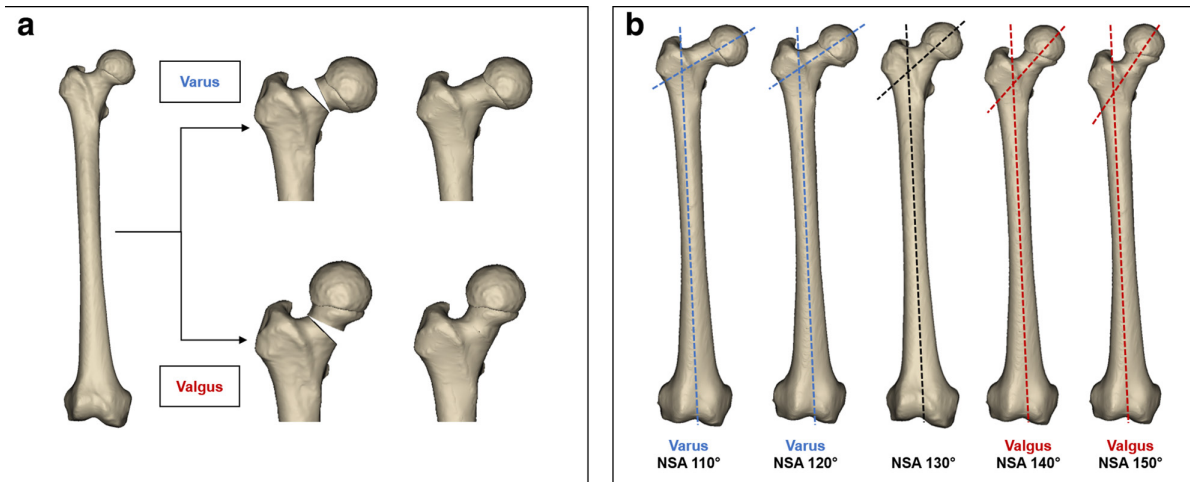


Fig. 2

a) 3D CT models of three patients (retroversion/normal version/anteversion) were manipulated to b) simulate different degrees of neck-shaft angle (NSA).

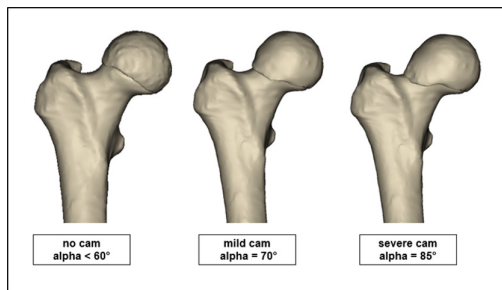


Fig. 3

3D CT models of three patients (retroversion/normal version/anteversion) were manipulated to simulate different  $\alpha$  angles (no cam/mild cam/severe cam).

**Table II.** CT-based measurements of femoral version among the four definitions for femoral version of the study population (42 patients (50 hips)).

Methods	Mean femoral version, ° (SD; 95% CI)
Lee et al <sup>14</sup>	14 (12; 11 to 18)
Reikerås et al <sup>15</sup>	18 (12; 15 to 21)
Tomczak et al <sup>16</sup>	30 (12; 26 to 33)
Murphy et al <sup>17</sup>	33 (14; 29 to 36)

CI, confidence interval; SD, standard deviation.

of the femoral neck with the greater trochanter, followed by the method of Reikerås et al<sup>15</sup> with an anatomical landmark at the level of the femoral neck, and the method Tomczak et al<sup>16</sup> at the level of the base of the femoral neck. The method of Murphy et al<sup>17</sup> is the method with the most distal definition at the level of the lesser trochanter. Excellent agreement for interobserver reliability with intraclass correlation coefficient (ICC), ranging from 0.96 for the method of Murphy et al<sup>17</sup> to 0.97 for the method of Lee et al,<sup>14</sup> have been reported for measurement of femoral version in patients with DDH and FAI using

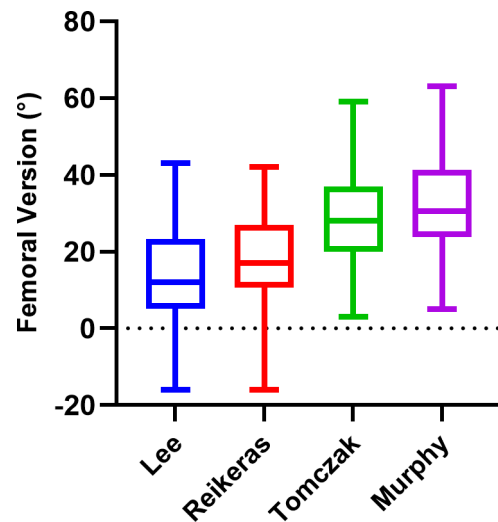


Fig. 4

Mean femoral version measurements of 50 symptomatic patients with hip pain using different methods.

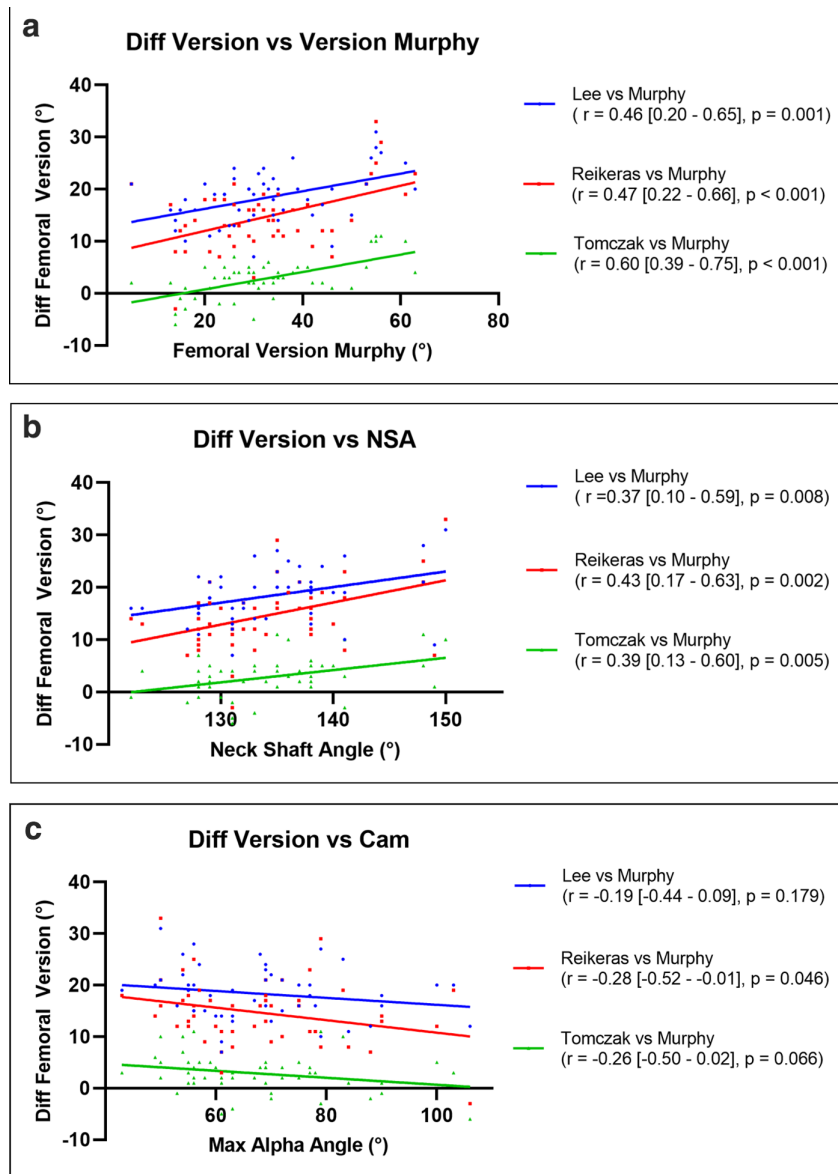
the abovementioned methods.<sup>11</sup> To evaluate how femoral malalignment (varus or valgus deformity) or abnormal proximal femoral anatomy (presence of cam deformity) affect different femoral version measurements methods, neck-shaft angle (NSA) and  $\alpha$  angle were measured on coronal and radial reformatted CT images according to established techniques.<sup>18,19</sup>

**3D parametric manipulation of the proximal femur.** To systematically evaluate the effect of NSA and  $\alpha$  angle on femoral version measurements, CT scans of two patients with isolated femoral malversion, and one patient without any other osseous deformities of the femur ( $125^\circ < \text{NSA} < 135^\circ$  and  $\alpha$  angle  $< 60^\circ$ ),<sup>18,20</sup> were selected based on the Murphy et al<sup>17</sup> method ( $< 0^\circ$  femoral retroversion model, 10 to 25° normal femoral version model,  $> 25^\circ$

**Table III.** Multiple comparison with analysis of variance with Tukey's adjustment of the four measurement methods (differences in degrees).

Methods	Lee et al	Reikerås et al	Tomczak et al	Murphy et al
Lee et al <sup>14</sup>	-	4 (2 to 5)	16 (14 to 17)	18 (16 to 20)
Reikerås et al <sup>15</sup>	< 0.001	-	12 (10 to 13)	15 (12 to 17)
Tomczak et al <sup>16</sup>	< 0.001	< 0.001	-	3 (1 to 4)
Murphy et al <sup>17</sup>	< 0.001	< 0.001	< 0.001	-

Data are presented as mean and 95% confidence intervals in brackets. In the upper right-hand corner, the values represent the mean difference of femoral version with 95% confidence intervals in parentheses; in the lower left-hand corner, the values represent the level of significance for each comparison.

**Fig. 5**

The correlation between method-related differences in femoral version and a) femoral version, b) neck-shaft angle (NSA), and c)  $\alpha$  angle of 50 patients are shown.

femoral anteversion model). Accordingly, femoral version was  $-7^\circ$  in the hip with femoral retroversion,  $20^\circ$  in the hip with normal femoral version, and  $30^\circ$  in the hip with femoral anteversion. The selected CT scans were then

manually segmented using commercial image processing software (Mimics v. 17.0; Materialise, Belgium). The segmented masks were then used to develop 3D models of the proximal femur. To simulate different degrees of

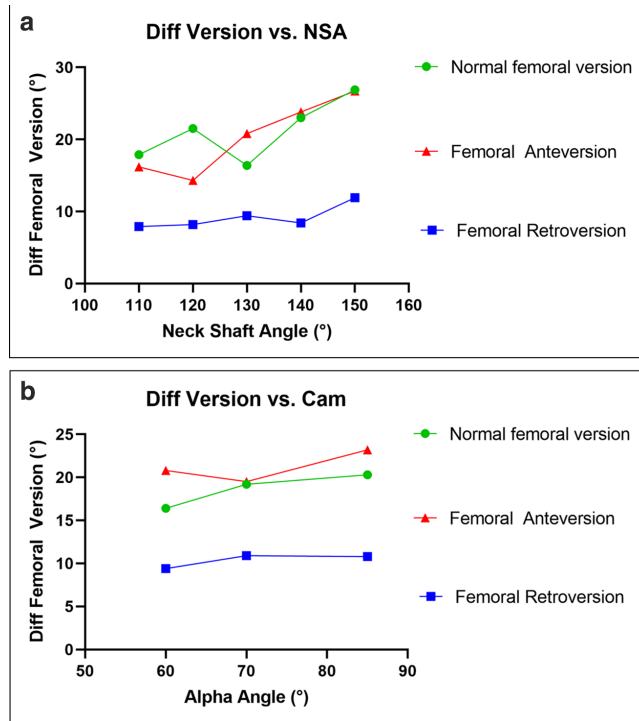


Fig. 6

The changes in method-related differences ((Diff) Lee et al<sup>14</sup> and Murphy et al<sup>17</sup>) in femoral version in the 3D parametric analysis depending on a) neck-shaft angle (NSA) and b)  $\alpha$  angle. In a), the biggest increase in differences of femoral version was seen for femoral anteversion with an increase of 11° (from 16° to 27°) with increasing NSA from 110° to NSA 150°. This effect was less pronounced in b), with an increase in differences of femoral version of 4° (from 16° to 20°) with increasing  $\alpha$  angle from 60° to 85° in normal femoral version.

varus/valgus and cam deformities, each model was manually manipulated to change the NSA (110°, 120°, 130°, 140°, 150°; Figure 2) and  $\alpha$  angle (no cam:  $\alpha$  angle < 60°, moderate/ severe cam:  $\alpha$  angle 70°/ 85°; Figure 3). This resulted in eight models per hip and a total of 24 3D models of the proximal femur.

Before the 3D models were used for analysis, we ensured that each of the final models exclusively represented the desired manipulation, i.e. only varus/valgus correction using multiplanar image reformatting. If necessary, further refinements were made. Manipulated models were used to generate 2D masks of the proximal femur, which were then used to quantify femoral version following the aforementioned four femoral version measurements. The model development and manipulation steps are presented in Figures 2 and 3. The model development and manipulation were done by a member of the team with more than ten years of experience in 3D imaging analysis and modelling (AMK). All measurements of femoral version were performed by two expert readers (FS and MKM) to assess interobserver reliability. One expert reader (MKM) repeated all measurements after eight weeks to assess intraobserver reliability.

**Statistical analysis.** Statistical analysis was performed using GraphPad Prism (Version 9.1, GraphPad, USA). Demographic characteristics are presented as percentages or means and SDs. Femoral version measurements were compared between different techniques using repeated measures analysis of variance (ANOVA) with Tukey's post-hoc adjustment for multiple pairwise comparisons. Differences between version measurement techniques were calculated for each hip (e.g. Lee – Murphy) and reported as mean with 95% confidence intervals (CIs). Pearson's correlation was used to determine the associations between method-related differences in femoral version measurements and  $\alpha$  angle or NSA. Interobserver reliability of the measurement methods in the 3D manipulation analysis was assessed via ICC. All p-values are two-sided and statistically significant at  $p < 0.05$ .

## Results

**Method-related differences in femoral version.** Femoral version was significantly different between all measurement methods (overall and pairwise comparisons,  $p < 0.001$ ; Tables II and III). Increasing values of femoral version were found using methods with more distal references of the femoral neck axis. Comparing the different measurement methods for femoral version, the lowest values were found for the method of Lee et al<sup>14</sup> (mean 14° (SD 12°)), followed by the method of Reikerås et al<sup>15</sup> (mean 18° (SD 12°)) and of Tomczak et al<sup>16</sup> (mean 30° (SD 12°)). Highest values were found for the method of Murphy et al<sup>17</sup> with a mean version of 33° (SD 14°). This resulted in mean differences (all  $p < 0.001$ ) ranging from 3° (95% CI 1° to 4°) when comparing the methods of Murphy et al<sup>17</sup> and Tomczak et al<sup>16</sup> to 18° (95% CI 16° to 20°) when comparing the most proximal (Lee et al<sup>14</sup>) and most distal (Murphy et al<sup>17</sup>) measurements (Figure 4, Table III).

**Association between method-related differences in femoral version and femoral anatomy.** Increased femoral version (using the Murphy et al<sup>17</sup> method as reference) was associated with greater differences in femoral version measurement between all methods ( $r > 0.46$ ;  $p \leq 0.001$ ; Figure 5a). Similarly, higher degrees of NSA were associated with higher differences of femoral version measurement between all methods ( $r > 0.37$ ;  $p = 0.008$ ; Figure 5b). Larger  $\alpha$  angles correlated with smaller differences in femoral version only for the differences between the methods of Murphy et al<sup>17</sup> and Reikerås et al<sup>15</sup> ( $r = -0.28$ ;  $p = 0.046$ ; Figure 5c). By contrast, there was no significant correlation between larger  $\alpha$  angles and smaller differences in femoral version between the methods of Murphy et al<sup>17</sup> and Tomczak et al<sup>16</sup> methods ( $r = -0.26$ ;  $p = 0.066$ ; Figure 5c). Similarly, there were no correlations between  $\alpha$  angle and difference in femoral version between Murphy et al<sup>17</sup> and Lee et al<sup>14</sup> method ( $r = -0.19$ ;  $p = 0.179$ ; Figure 5c).



**Table IV.** Interobserver reliability presented as intraclass correlation coefficient of 3D manipulation analysis.

Technique	Intraobserver reliability (95% CI)	Interobserver reliability (95% CI)
Lee et al <sup>14</sup>	0.998 (0.971 to 0.995)	0.969 (0.926 to 0.987)
Reikerås et al <sup>15</sup>	0.969 (0.928 to 0.987)	0.914 (0.9803 to 0.964)
Tomczak et al <sup>16</sup>	0.965 (0.920 to 0.985)	0.926 (0.829 to 0.969)
Murphy et al <sup>17</sup>	0.976 (0.944 to 0.990)	0.963 (0.913 to 0.985)

CI, confidence interval.

**3D parametric manipulation analysis of proximal femur.** In the parametric 3D manipulation analysis, the highest differences were seen with femoral anteversion and high NSA. In models femoral anteversion and normal femoral version, an isolated increase in NSA from 110° to 150° resulted in an increase of 11° (from 16° to 27°) and 9° (from 18° to 27°) between most proximal (Lee et al<sup>14</sup>) and most distal (Murphy et al<sup>17</sup>) measurement methods of femoral version, respectively (Figure 6a). By contrast, this method-related difference was less pronounced with a 4° increase in the model with femoral retroversion (Figure 6a).

An isolated increase in  $\alpha$  angle from 60° to 85° resulted in an increase of 3°, 4°, and 2° in the models with femoral anteversion, normal femoral version, and retroversion, respectively, between most proximal (Lee et al<sup>14</sup>) and most distal (Murphy et al<sup>17</sup>) measurement methods (Figure 6b). Detailed results about femoral version can be found in Supplementary Figures a and b.

High agreement was found for measurement of femoral version in the 3D manipulation analysis with an ICC ranging from 0.97 for the method of Tomczak et al<sup>16</sup> to 0.99 to the method of Lee et al<sup>14</sup> (Table IV).

## Discussion

Our findings indicate substantial differences in femoral version (up to 18°) based on the measurement technique, supporting our first hypothesis. Our findings also show significant associations between method-related differences in femoral version and femoral morphology (i.e. femoral version, NSA, and  $\alpha$  angle), supporting our second hypothesis. These findings highlight the importance of measurement technique and proximal femur morphology in treatment planning for surgical correction of femoral version abnormalities.

In general, we observed smaller femoral version in methods using proximal definition of landmarks (i.e. Lee et al<sup>14</sup>) compared to measurement methods with more distal landmark definition such as the method described by Murphy et al<sup>17</sup>. Our findings are in line with previous studies investigating femoral retroversion in slipped capital femoral epiphysis, and in patients with FAI and DDH.<sup>11,21</sup> In these studies, maximum mean differences between proximal and distal measurement methods were as high as 17° (SD 5°) in slipped capital femoral epiphysis and 19° (SD 7°) in FAI and DDH, respectively.<sup>11,21</sup> Considering that surgical correction in femoral derotational osteotomy is usually

aimed in the range of 10° to 25°,<sup>7,9,10</sup> these method-related differences are therefore clinically relevant and highlight the importance of reporting femoral version in a standardized manner. In order to facilitate communication among physicians, and to ensure transparency of clinical studies on femoral version, the applied measurement methods should be reported precisely.

A significant association between femoral malalignment and method-related differences in femoral version measurement was observed. Increasing femoral version (using the Murphy et al<sup>17</sup> method as reference) was significantly associated with greater differences in femoral version between the measurement methods. Although indications are still evolving, femoral derotational osteotomies are currently mainly performed in the setting of hip instability and extra-articular impingement in adult patients with excessive abnormalities of femoral version. In this patient cohort, it is crucial to determine the degree of the rotational deformity for planning of the surgical correction supporting the use of more distal measurement methods.

Interestingly, we observed direct associations between NSA and method-related differences in femoral version, which was further confirmed using a 3D parametric analysis. An isolated increase of NSA from 110° to 150° resulted in an 11° and 9° increase in difference of femoral version measurements between the method of Lee et al<sup>14</sup> and Murphy et al<sup>17</sup> in patients with femoral anteversion/normal femoral version. These findings are in agreement with those by Liu et al,<sup>22</sup> who showed that a varus/valgus osteotomy results in decreased/increased femoral version, respectively. These observations highlight the importance of varus/valgus alignment in surgical correction of femoral malversion to avoid over- or under-correction of femoral version. In contrast to the effect of NSA, impact of cam deformity on differences in femoral version measurements was less pronounced and only observed in one of three comparisons (Reikerås et al<sup>15</sup> vs Murphy et al<sup>17</sup>) (Figure 5c). Results of the 3D parametric analysis showed a similar tendency, however the small increase of 3° to 5° might fall within the range of measurement error.

Overall, there is controversy as to which measurement method best reflects femoral malalignment. Murphy et al<sup>17</sup> investigated different CT-based measurement methods of femoral version in cadavers, and concluded that more proximal methods which use the greater trochanter (similar to Lee et al<sup>14</sup>) or the femoral neck axis (similar to Reikerås

et al<sup>15</sup> as reference) consistently underestimated femoral version by a mean of 10° (7° to 18°) relative to true femoral version. The authors proposed an alternative measurement method, using the level of the lesser trochanter as anatomical reference (i.e. the Murphy et al<sup>17</sup> method), which minimized this bias to ± 1° in cadaveric femora.<sup>17</sup> Accordingly, measurement methods which take the entire proximal femur into account by using distal landmarks such as the Murphy et al method<sup>17</sup> may produce more sensitive measurements of these differences. However, future studies with clinical outcome data are necessary to show the benefit of applying different measurement methods for surgical decision-making.

This may be especially important in patients with valgus and femoral anteversion, who are eligible for femoral osteotomies for combined or isolated derotation and angular correction.<sup>3</sup>

This study has a number of limitations. First, this is an imaging-based study only without clinical outcome data, precluding any conclusions regarding clinical outcome. Second, only three patients were included in the 3D manipulation study, leading to a small sample size of 24 3D models. However, the 3D manipulation analysis was performed additionally to reproduce findings of the study population with a sufficient sample size (n = 50). Finally, despite being increasingly used to measure femoral version, we did not include MRI scans in this study.<sup>23</sup> This is related to the fact that 3D manipulation of femoral models is more complicated and cumbersome with MRI.

In conclusion, measurement of femoral version angles differs depending on the method used to almost 20°, which is in the range of the aimed surgical correction in derotation femoral osteotomy, and thus can be considered clinically relevant. Differences between proximal and distal measurement methods further increase by increasing femoral version, NSAs, and to a lesser degree decrease by smaller α angles. Accordingly, measurement methods based on distal anatomical methods (i.e. Murphy et al),<sup>17</sup> which take into account the entire proximal femur, may better reflect overall malignment in patients considered for femoral osteotomies.



### Take home message

- Measurement of femoral version angles differs depending on the method used to almost 20°, which is in the range of the aimed surgical correction in derotation femoral osteotomy, and thus can be considered clinically relevant.
- Differences between proximal and distal measurement methods further increase by increasing femoral version, increasing neck shaft angles, and to a lesser degree decrease by smaller alpha angles.
- Accordingly, measurement methods based on distal anatomical methods, which take into account the entire proximal femur, may better reflect overall malignment in patients considered for femoral osteotomies.

### Supplementary material



Figures displaying the neck shaft angle and alpha angle-associated changes in femoral version in the parametric analysis depending on the model with femoral anteversion, normal femoral version, and femoral retroversion.

### References

1. **Lerch TD, Todorski IAS, Steppacher SD, et al.** Prevalence of femoral and acetabular version abnormalities in patients with symptomatic hip disease: a controlled study of 538 hips. *Am J Sports Med.* 2018;46(1):122–134.
2. **Lerch TD, Boschung A, Todorski IAS, et al.** Femoroacetabular impingement patients with decreased femoral version have different impingement locations and intra- and extraarticular anterior subspine FAI on 3D-CT-based impingement simulation: implications for hip arthroscopy. *Am J Sports Med.* 2019;47(13):3120–3132.
3. **Siebenrock KA, Steppacher SD, Haefeli PC, Schwab JM, Tannast M.** Valgus hip with high antetorsion causes pain through posterior extraarticular FAI. *Clin Orthop Relat Res.* 2013;471(12):3774–3780.
4. **Fabricant PD, Fields KG, Taylor SA, Magennis E, Bedi A, Kelly BT.** The effect of femoral and acetabular version on clinical outcomes after arthroscopic femoroacetabular impingement surgery. *J Bone Joint Surg Am.* 2015;97-A(7):537–543.
5. **Chaharbhakshi EO, Hartigan DE, Perets I, Domb BG.** Is hip arthroscopy effective in patients with combined excessive femoral anteversion and borderline dysplasia? Response. *Am J Sports Med.* 2019;47(11):62–NP63.
6. **Rigling D, Zingg PO, Dora C.** Subtrochanteric rotational osteotomy for young adults with hip pain due to femoral malrotation. *Hip Int.* 2021;31(6):797–803.
7. **Lerch TD, Schmaranzer F, Steppacher SD, Ziebarth K, Tannast M, Siebenrock KA.** Most of patients with femoral derotation osteotomy for posterior extraarticular hip impingement and high femoral version would do surgery again. *Hip Int.* 2022;32(2):253–264.
8. **Mastel MS, El-Bakoury A, Parkar A, Sharma R, Johnston KD.** Outcomes of femoral de-rotation osteotomy for treatment of femoroacetabular impingement in adults with decreased femoral anteversion. *J Hip Preserv Surg.* 2020;7(4):755–763.
9. **Buly RL, Sosa BR, Poultsides LA, Caldwell E, Rozbruch SR.** Femoral derotation osteotomy in adults for version abnormalities. *J Am Acad Orthop Surg.* 2018;26(19):e416–e425.
10. **Hatem M, Khoury AN, Erickson LR, Jones AL, Martin HD.** Femoral derotation osteotomy improves hip and spine function in patients with increased or decreased femoral torsion. *Arthroscopy.* 2021;37(1):111–123.
11. **Schmaranzer F, Lerch TD, Siebenrock KA, Tannast M, Steppacher SD.** Differences in femoral torsion among various measurement methods increase in hips with excessive femoral torsion. *Clin Orthop Relat Res.* 2019;477(5):1073–1083.
12. **Lerch TD, Steppacher SD, Liechti EF, Tannast M, Siebenrock KA.** One-third of hips after periacetabular osteotomy survive 30 years with good clinical results, no progression of arthritis, or conversion to THA. *Clin Orthop Relat Res.* 2017;475(4):1154–1168.
13. **Steppacher SD, Anwander H, Zurmühle CA, Tannast M, Siebenrock KA.** Eighty percent of patients with surgical hip dislocation for femoroacetabular impingement have a good clinical result without osteoarthritis progression at 10 years. *Clin Orthop Relat Res.* 2015;473(4):1333–1341.
14. **Lee YS, Oh SH, Seon JK, Song EK, Yoon TR.** 3D femoral neck anteversion measurements based on the posterior femoral plane in ORTHODOC system. *Med Biol Eng Comput.* 2006;44(10):895–906.
15. **Reikerås O, Bjerkreim I, Kolbenstvedt A.** Anteversion of the acetabulum and femoral neck in normals and in patients with osteoarthritis of the hip. *Acta Orthop Scand.* 1983;54(1):18–23.
16. **Tomczak RJ, Guenther KP, Rieber A, Mergo P, Ros PR, Brambs HJ.** MR imaging measurement of the femoral antetorsional angle as a new technique: comparison with CT in children and adults. *AJR Am J Roentgenol.* 1997;168(3):791–794.
17. **Murphy SB, Simon SR, Kijewski PK, Wilkinson RH, Griscom NT.** Femoral anteversion. *J Bone Joint Surg Am.* 1987;69-A(8):1169–1176.
18. **Boese CK, Jostmeier J, Oppermann J, et al.** The neck shaft angle: CT reference values of 800 adult hips. *Skeletal Radiol.* 2016;45(4):455–463.
19. **Sutter R, Dietrich TJ, Zingg PO, Pfirrmann CWA.** How useful is the alpha angle for discriminating between symptomatic patients with cam-type femoroacetabular impingement and asymptomatic volunteers? *Radiology.* 2012;264(2):514–521.

20. **Mascarenhas VV, Castro MO, Rego PA, et al.** The Lisbon Agreement on femoroacetabular impingement imaging-part 1: overview. *Eur Radiol.* 2020;30(10):5281–5297.
21. **Schmaranzer F, Kallini JR, Ferrer MG, et al.** How common is femoral retroversion and how is it affected by different measurement methods in unilateral slipped capital femoral epiphysis? *Clin Orthop Relat Res.* 2021;479(5):947–959.
22. **Liu RW, Toogood P, Hart DE, Davy DT, Cooperman DR.** The effect of varus and valgus osteotomies on femoral version. *J Pediatr Orthop.* 2009;29(7):666–675.
23. **Schmaranzer F, Kallini JR, Miller PE, Kim Y-J, Bixby SD, Novais EN.** The effect of modality and landmark selection on MRI and CT femoral torsion angles. *Radiology.* 2020;296(2):381–390.

#### Author information:

- F. Schmaranzer, MD, PhD, Resident
- T. D. Lerch, MD, PhD, Resident  
Department of Diagnostic, Interventional and Pediatric Radiology, Inselspital, Bern University Hospital, University Bern, Bern, Switzerland.
- M. K. Meier, MD, Resident
- A. Hecker, MD, Orthopedic Surgeon
- S. D. Steppacher, MD, Orthopedic Surgeon  
Department of Orthopaedic Surgery and Traumatology, Inselspital, Bern University Hospital, University Bern, Bern, Switzerland.
- E. N. Novais, MD, Orthopedic Surgeon
- A. M. Kiapour, PhD, Assistant Professor  
Department of Orthopaedic Surgery, Boston Children's Hospital, Harvard Medical School, Boston, Massachusetts, USA.

#### Author contributions:

- F. Schmaranzer: Conceptualization, Data curation, Methodology, Project administration, Supervision, Writing – original draft, Writing – review & editing.
  - M. K. Meier: Data curation, Formal analysis, Methodology, Visualization, Writing – original draft, Writing – review & editing.
  - T. D. Lerch: Data curation, Methodology, Writing – original draft, Writing – review & editing.
  - A. Hecker: Methodology, Writing – original draft, Writing – review & editing.
  - S. Steppacher: Conceptualization, Methodology, Supervision, Writing – original draft, Writing – review & editing.
  - E. N. Novais: Conceptualization, Methodology, Supervision, Writing – original draft, Writing – review & editing.
  - A. Kiapour: Conceptualization, Data curation, Methodology, Supervision, Writing – original draft, Writing – review & editing.
- F. Schmaranzer and M. K. Meier contributed equally to this work.
- F. Schmaranzer and M. K. Meier are joint first authors.

#### Funding statement:

- The authors received no financial or material support for the research, authorship, and/or publication of this article.

#### Ethical review statement:

- The study was approved by the local ethics committee.

#### Open access funding

- The authors confirm that the open access fee for this study was provided by the University of Bern.

© 2022 Author(s) et al. This is an open-access article distributed under the terms of the Creative Commons Attribution Non-Commercial No Derivatives (CC BY-NC-ND 4.0) licence, which permits the copying and redistribution of the work only, and provided the original author and source are credited. See <https://creativecommons.org/licenses/by-nc-nd/4.0/>