



■ INFECTION

Negative pressure wound therapy does not diminish efficacy of topical antibiotic powder in a preclinical contaminated wound model

AN ANIMAL STUDY

**S. M. Shiels,
N. M. Sgromolo,
J. C. Wenke**

From U.S. Army Institute of Surgical Research, San Antonio, Texas, USA

Aims

High-energy injuries can result in multiple complications, the most prevalent being infection. Vancomycin powder has been used with increasing frequency in orthopaedic trauma given its success in reducing infection following spine surgery. Additionally, large, traumatic injuries require wound coverage and management by dressings such as negative pressure wound therapy (NPWT). NPWT has been shown to decrease the ability of antibiotic cement beads to reduce infection, but its effect on antibiotic powder is not known. The goal of this study was to determine if NPWT reduces the efficacy of topically applied antibiotic powder.

Methods

Complex musculoskeletal wounds were created in goats and inoculated with a strain of *Staphylococcus aureus* modified to emit light. Six hours after contaminating the wounds, imaging, irrigation, and debridement and treatment application were performed. Animals received either vancomycin powder with a wound pouch dressing or vancomycin powder with NPWT.

Results

There were no differences in eradication of bacteria when vancomycin powder was used in combination with NPWT (4.5% of baseline) compared to vancomycin powder with a wound pouch dressing (1.7% of baseline) ($p = 0.986$), even though approximately 50% of the vancomycin was recovered in the NPWT exudate canister.

Conclusion

The antimicrobial efficacy of the vancomycin powder was not diminished by the application of NPWT. These topical and locally applied therapies are potentially effective tools that can provide quick, simple treatments to prevent infection while providing coverage. By reducing the occurrence of infection, the recovery is shortened, leading to an overall improvement in quality of life.

Cite this article: *Bone Joint Res* 2021;10(2):149–155.

Keywords: Local antibiotic therapy, Musculoskeletal infection, Topical antibiotic, Orthopaedic trauma

Correspondence should be sent to Stefanie M. Shiels; email: stefanie.m.shiels.civ@mail.mil

doi: 10.1302/2046-3758.102.BJR-2020-0171.R1

Bone Joint Res 2021;10(2):149–155.

Article focus

■ This study aimed to determine whether the effectiveness of topical vancomycin powder would be diminished by the application of a negative pressure wound dressing.

Key messages

- Negative pressure wound therapy (NPWT) did not decrease the antimicrobial efficacy of topical vancomycin powder.
- Approximately 50% of the vancomycin powder was collected in the exudate

canister, emphasizing the need for sufficient antibiotic powder when using NPWT.

Strength and limitations

- By using a large animal model, the antimicrobial effectiveness of vancomycin powder was evaluated in a wound of similar clinical size.
- Although this study demonstrated limited influence of NPWT on the effectivity of vancomycin powder, the sample size was small.

Introduction

High-energy open fractures, such as those from road traffic crashes, pose a treatment challenge to emergency medicine providers and orthopaedic surgeons. Tibia fractures are the most common, accounting for approximately 11% of all open fractures.¹ Due to minimal soft tissue coverage, limited blood supply, and the severity of concomitant injury typically incurred to the surrounding soft tissue envelope, these fractures are plagued with complications including nonunion, compartment syndrome, and infection.² Despite a standard of care regimen which includes antibiotics, irrigation, serial debridement, and delayed wound closure, infection rates remain high (between 11% and 28%).^{3,4} Providers continue to explore new advances in surgery and medicine to decrease infection in these complex injuries.

Local antibiotics provide higher concentrations of drug at the wound site with less potential for toxicity from prolonged systemic use.⁵⁻⁷ Antibiotic-loaded polymethylmethacrylate (PMMA) is a fundamental depot-style device for local delivery of antibiotics.⁸⁻¹⁰ PMMA, however, involves back-table preparation and cure-time, has low elution rates, and requires subsequent removal procedures.¹¹⁻¹³ Alternatively, topically applied vancomycin powder is gaining popularity as it has demonstrated efficacy in reducing surgical site infections when used prophylactically in spinal surgery, decreasing infection rates from 2.6% to 0.2% while dramatically reducing surgical costs by approximately \$3,000.^{14,15} Despite this, there is little to no evidence for its use in a trauma scenario. In a preclinical model of musculoskeletal infection, Tennent et al¹⁶ demonstrated the efficacy of vancomycin powder when applied early after injury. Vancomycin powder does not require antibiotic elution as with antibiotic-loaded PMMA beads and can be easily spread throughout the entire wound aiding in antibiotic diffusion into the surrounding soft tissues.¹⁷⁻¹⁹ While local antibiotics could reduce wound infection, wound coverage is still a necessity in many traumatic wounds.

Initially developed to improve closure of chronic, non-healing wounds, negative pressure wound therapy (NPWT) is regularly used by the trauma and orthopaedic community in management of acute, open, contaminated wounds.²⁰⁻²² NPWT is commonly used after initial debridement to effectively manage open

wounds by providing coverage and promoting healthy wound beds.^{23,24} Despite widespread usage, its efficacy in reducing wound infection rates remains under debate. There is some empirical evidence for its potential to reduce infection following open fractures, decreasing infection rates to 6% to 8% versus 20% to 28% when standard dressing is applied.^{3,4,25} Other analyses indicate that NPWT either has no anti-infective benefit compared to standard dressings or even causes worse outcomes.^{23,26} In general, current data indicate that patients who received NPWT were less likely to develop a clinical infection, less likely to have culture-positive wounds, and less likely to develop osteomyelitis.

Considering the positive effects of both local antibiotics and NPWT as independent therapies, the coapplication of NPWT with local antibiotics has had mixed outcomes. The use of NPWT decreases the antimicrobial efficacy of vancomycin-loaded PMMA beads.^{27,28} As a depot for antibiotics, the drug must slowly elute out of the bead and diffuse throughout the wound to be effective. The NPWT removes the antibiotic-laden exudate from the wound before the drug levels can accumulate to a concentration sufficient to exert an antimicrobial effect. However, NPWT does not alter the antimicrobial effect when combined with an antibiotic-loaded chitosan sponge.²⁸ The sponge covers the entire wound bed, contacting all the tissues and providing a steady delivery of drug to the injury site. Since it is a delivery device instead of a depot, it is effective even with NPWT applied. The effect NPWT has on the antimicrobial efficacy of vancomycin powder is not known. Conceptually, the topical powder may be effective even with NPWT because it is placed throughout the entire wound, but the possibility exists that solubilized antibiotic may be removed from the wound bed by NPWT before a therapeutic concentration or contact duration is achieved. The goal of this study is to determine whether NPWT reduces the effectiveness of topical vancomycin powder in a contaminated musculoskeletal wound.

Methods

This research was conducted in compliance with the Animal Welfare Act, the implementing Animal Welfare Regulations,²⁹ and the principles of the Guide for the Care and Use of Laboratory Animals, National Research Council.³⁰ The Institutional Animal Care and Use Committee approved all research conducted in this study. The facility where this research was conducted is fully accredited by AAALAC. This study is reported under the guidance of the ARRIVE guidelines.

Under general anaesthesia, eight castrated male, Spanish Boer goats (mean 38.1 kg (SD 1.6); K Bar Livestock LLC, Sabinal, Texas, USA) received a complex polytraumatic musculoskeletal wound on their left hind limb as previously described.³¹ Briefly, under general anaesthesia, a wound was created by excising a full thickness skin flap, removing a portion of the tibialis anterior, and creating a 12 mm unicortical defect within the anterior

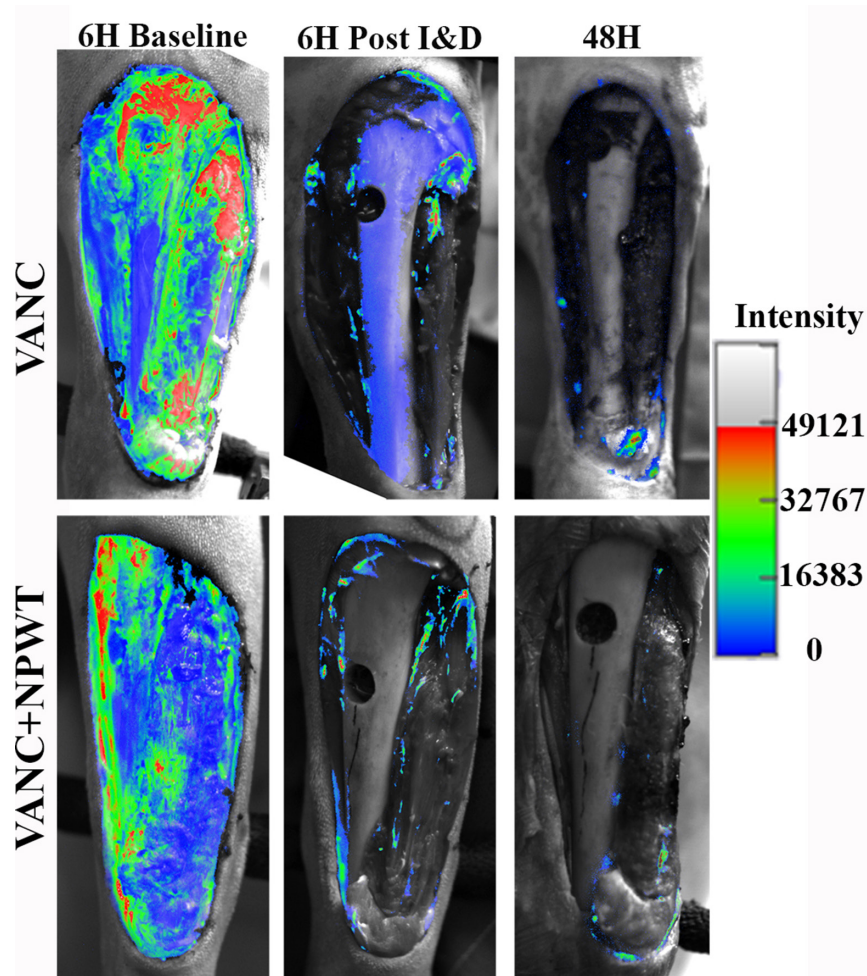


Fig. 1

Bacterial luminescent data represented as percentage of six-hour baseline (before irrigation and debridement (I&D)). There was no difference detected between groups at the 48-hour study endpoint ($p = 0.986$, generalized linear model adjusting for post I&D). NPWT, negative pressure wound therapy; VANC, vancomycin powder placed directly on wound; VANC+NPWT, vancomycin powder placed directly on wound with NPWT application.

aspect of the tibia. It was completed with a freeze injury and thermal burn to the bone and soft tissues. Following wound creation, each wound was inoculated with 4.4×10^8 ($\pm 1.1 \times 10^7$) colony-forming units (CFUs) of Xen36 (Perkin Elmer, Akron, Ohio, USA), a *Staphylococcus aureus* isolate modified to emit light when metabolically active. This strain has a high luminescent output and allows for noninvasive, in vivo imaging.³² The wounds were dressed in standard fashion with wrap dressing and the animals allowed to move freely for a period of six hours.

Six hours following injury and inoculation, each animal was again anaesthetized and the wounds were imaged via a charge-coupled device (CCD) photon-counting camera (C9100-24B; Hamamatsu, Hamamatsu, Japan) (Supplementary Figure a). An initial black and white image was acquired to delineate wound borders and individual features. A second image was acquired to identify and count the light-emitting bacteria within the wound (six hours from the baseline image). Following initial imaging, the wound was debrided, irrigated with

9 l normal saline, and imaged again (six hours post irrigation and debridement (I&D)). Each animal was randomly placed into one of two treatment groups: vancomycin powder alone with a wound pouch dressing (VANC; $n = 4$) or vancomycin powder combined with NPWT (VANC + NPWT; $n = 4$). The VANC animals received 1 g vancomycin powder (Alvogen, Pine Brook, New Jersey, USA) spread uniformly over the wound and covered by a wound pouch composed of saline-soaked gauze with a semi-permeable wrap dressing. The VANC + NPWT animals received 1 g vancomycin powder spread uniformly over the wound and covered by gauze followed by a negative pressure dressing. NPWT was run (EZCare system, Smith and Nephew, Memphis, Tennessee, USA) at a continuous suction of -80 mmHg. At the time of vancomycin placement, the wound size was 34.2 cm² (SD 2.7). Then, 48 hours after initial inoculation, luminescent imaging was again performed immediately following animal euthanization (48 hours).

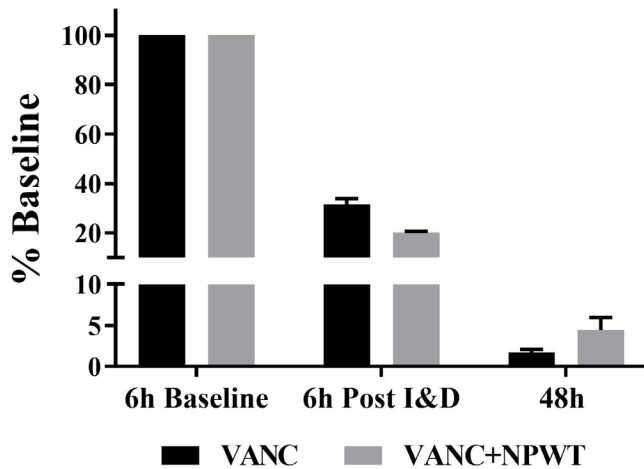


Fig. 2

Representative images acquired with charge-coupled device camera showing bacterial colonization six hours after initial inoculation, before (six-hour baseline) and after irrigation and debridement (six hours post I&D), and the 48-hour endpoint. NPWT, negative pressure wound therapy; VANC, vancomycin powder placed directly on wound; VANC+NPWT, vancomycin powder placed directly on wound with NPWT application.

Statistical analysis. Data represented are normalized to six-hour baseline levels (six hours after inoculation, immediately prior to I&D) or mean and standard error of the mean (SEM). Six-hour post I&D and 48-hour luminescent counts were normalized to the six-hour baseline luminescent counts. A generalized linear model (GLM) was applied to the 48-hour ratios adjusting for six-hour post I&D to determine differences in photon reduction. A p-value of ≤ 0.05 was considered statistically significant. Statistical analysis was conducted using SAS 9.4 (SAS Institute, Cary, North Carolina, USA).

Results

There were no statistical differences detected in the reduction of bacterial burden when vancomycin powder was used in combination with NPWT ($4.5\% \pm 1.5\%$ of baseline) when compared to vancomycin powder within a wound pouch alone ($1.7\% \pm 0.3\%$ of baseline) (Figure 1, $p = 0.986$, GLM). For reference, a wound in a similar model, treated with I&D, and covered with a standard wet-to-dry dressing, had a bacterial rebound of over 500% from baseline.³¹ Images of the wounds corroborate the photon count results where debridement removed the majority of the bacteria present and vancomycin powder, both with and without NPWT, further reduced the amount of bacterial contamination (Figure 2). A mean total of 507.8 mg (SEM 88.7) vancomycin at 2.9 mg/ml (SEM 0.4) in exudate was recovered in the NPWT wound canister, representing approximately 50% of the total vancomycin placed into the wound. No gross differences were observed in the wound at euthanasia.

One animal from each group expired prior to study completion. One was from aspiration pneumonia and

the other from an unknown reason; their data were excluded from the data analysis.

Discussion

Open fractures remain fraught with complication, and multiple combined therapy methods are often employed to decrease the risk of infection and improve outcomes. Thorough surgical debridement and irrigation continue to be the primary course of treatment. Following surgical care, treatment methods such as topical antibiotic delivery and NPWT can be applied to improve outcomes. Our study indicates that the coapplication of both NPWT and topical vancomycin powder did not diminish the efficacy of the antibiotic. This may help manage severe, highly contaminated soft tissue injuries in the future.

Local antibiotics, particularly antibiotic-loaded PMMA beads, are commonly used to provide high concentrations of antibiotic to the wound with little risk of systemic toxicity.^{5,7,8,33,34} However, the use of antibiotic beads accrue additional cost of the PMMA and require time to prepare. Premade antibiotic beads are not approved by the USA Food and Drug Administration and are only available in Europe at a substantial cost and in limited supply.^{35,36} In addition, PMMA beads have poor elution characteristics, require a subsequent surgery for removal, and if left in place for too long can become a nidus for bacterial biofilm formation.^{27,28} A variety of other local antibiotic approaches have been examined by varied potential and success. These include vancomycin- and tobramycin-loaded gels, silver dressings, antibiotic-loaded calcium-based bone substitutes, and antibiotic-loaded chitosan sponges.^{37–42} Over the past decade, the prophylactic use of vancomycin powder has become an effective tool in reducing surgical site infection, particularly in spinal surgery. When vancomycin powder is placed in the surgical site of a spine fusion, there is a four-fold decrease in infection.¹⁵ Since its use in spinal surgery, the interest in vancomycin powder has expanded to other fields including trauma surgery and the management of open musculoskeletal injuries. The trauma community has become interested in topical vancomycin powder for its ease of application, efficacy, and low cost. In a preclinical model of musculoskeletal trauma, we demonstrated that when vancomycin powder was used within six hours, it was more effective in reducing bacterial bioburden than when treatment was delayed beyond 24 hours.¹⁶ Clinically, the use of vancomycin powder in the residual limb of combat amputees resulted in a 13% decrease in infection risk.⁴³ There are ongoing clinical trials which will strengthen the level of evidence for the effectiveness of vancomycin powder in reducing infection associated with orthopaedic trauma (VANCO NCT02227446 and POWDER NCT03765567). The information gained from these studies could lead to changes and updates to best practices. The ease of application along with

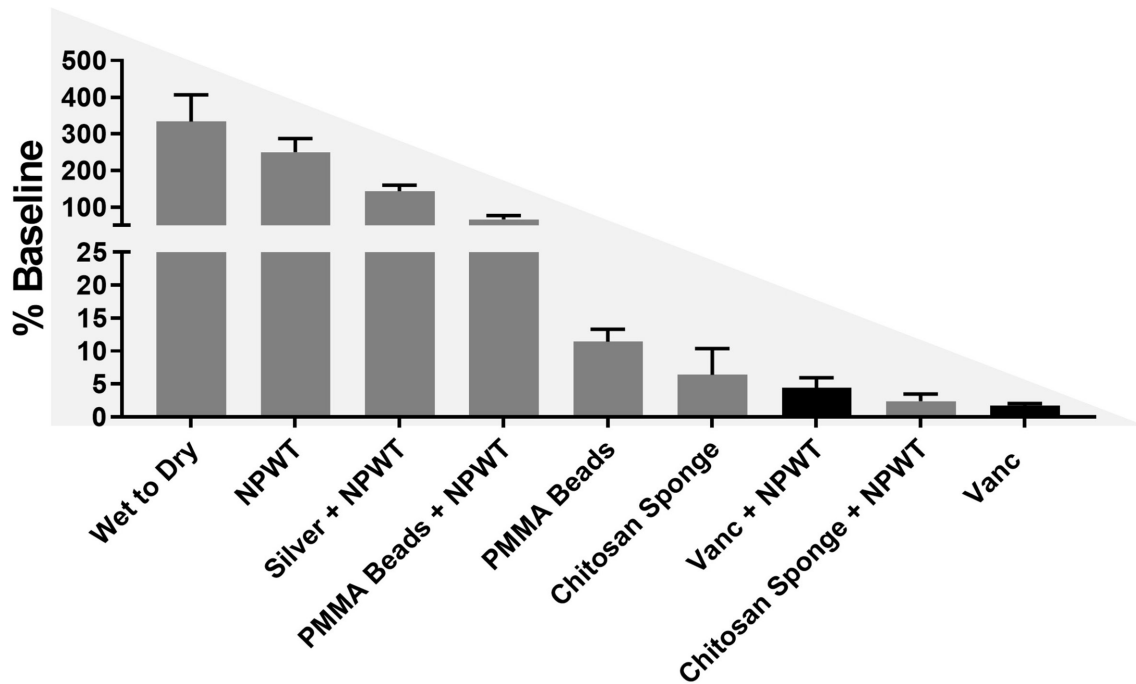


Fig. 3

Representative effectiveness of local wound therapies. The same large animal model was used to identify the effectivity of each of these therapies after two days of use. The dark grey colour represents previously published results.^{27,28,31,53,54} The black bars are from the current study. Wet to Dry, a standard dressing changed twice daily; NPWT, continuous negative pressure application; Silver + NPWT, a silver dressing placed directly on wound with NPWT application; polymethylmethacrylate (PMMA) Beads + NPWT, vancomycin-loaded PMMA beads placed directly on wound with NPWT application; PMMA beads, vancomycin-loaded PMMA beads placed directly on wound with semipermeable membrane application; Chitosan Sponge, vancomycin-loaded chitosan sponge placed directly on wound with a semipermeable membrane application; Chitosan Sponge + NPWT, vancomycin-loaded chitosan sponge placed directly on wound with NPWT application. Vanc + NPWT, vancomycin powder placed directly on wound with NPWT application; Vanc, vancomycin powder placed directly on wound.

the therapeutic benefit makes vancomycin powder an attractive topical therapy.

Since its commercialization, NPWT has been used for a variety of injury applications including wound coverage, healing aide, graft bolster, and infection control.^{44–46} Early NPWT application facilitates earlier primary closure by preparing a healthier wound bed.⁴⁴ Additionally, NPWT is attributed with enhancing neovascularization of skin grafts.⁴⁵ NPWT has reportedly reduced infection rates compared to standard dressings.⁴ Stannard et al⁴ identified an infection rate reduction from 28% to 5% when NPWT was used in open fractures, in conjunction with serial surgical debridement and irrigation. As with any treatment, proper use and operation dictates the successful outcomes. For example, although common NPWT uses -125 mmHg, which is within the recommended -50 mmHg to -150 mmHg range, we chose to use -80 mmHg subatmospheric pressure because previous use (unpublished) shows loss of continual suction and filter/tube clogging in this model, which has the unit placed more than 5 ft above a mobile animal.⁴⁷ Additionally, there are concerns that increased suction could lead to ischaemia of vascular flaps.^{48,49} Finally, there are also concerns that loss of NPWT suction could result in increased infection.⁵⁰ The incorporation of an antibiotic with the

NPWT dressing could not only treat the wound in its current form but also protect the wound from infection in the rare case of NPWT failure.^{51,52}

To further improve outcomes, it has been suggested that NPWT can be combined with local antibiotics. Our group has demonstrated that antibiotic vehicle choice is a defining factor of successful combination of local antibiotics with NPWT. With the use of a large animal model, our group has previously evaluated different local antibiotic delivery systems with and without the combined use of NPWT with varied success (Figure 3). Unfortunately, NPWT decreased the antimicrobial efficacy of antibiotic beads, which is an antibiotic depot.²⁷ It is believed that antibiotic eluted from the bead was removed by the NPWT before it could diffuse throughout the wound and accumulate at therapeutic concentrations. Alternatively, the effectiveness of an antibiotic-loaded chitosan sponge was not diminished by use of the NPWT.²⁸ The continuous and direct contact of the chitosan sponge with the wound bed is thought to allow this antibiotic delivery device to be effective even when used with NPWT. As demonstrated in the current study, vancomycin powder substantially reduced the amount of bacterial bioburden within the wound both with and without NPWT.

Our study, like all other preclinical translational studies, had several limitations. First, our number of study subjects was small and we only compared the vancomycin powder pouch to vancomycin powder in conjunction with NPWT. That being said, the effectiveness of local antibiotics is robust compared to historical control and treatment data and highly reproducible with both therapies.^{27,28,31,53,54} Additionally, only one dose of antibiotic was investigated. Most therapies have a dose-response curve, and if we used lower amounts of antibiotic, it is plausible that we may have detected a difference between groups. It is worth noting, however, that we demonstrated that 1 g of vancomycin powder was effective for wounds that are approximately 35 cm² (for reference, a playing card is 57 cm²) regardless of losing about half of the antibiotic to the negative pressure. This may inform dosing of complex wounds. Next, we investigated only a single infecting pathogen, which may limit this study's clinical applicability. However, this animal model was chosen to most closely resemble human anatomy and represent the primary infecting pathogen, *S. aureus*. It is worth noting that we have previously demonstrated that treating polymicrobial (*S. aureus* and *Pseudomonas aeruginosa*) infection with both vancomycin and tobramycin is extremely effective in the same preclinical model.⁵⁵

In summary, despite previous evidence demonstrating the reduced efficacy of local antibiotic delivery in the case of antibiotic beads combined with NPWT, our study demonstrates that vancomycin powder has similar efficacy with or without the use of NPWT. This was despite losing nearly 50% of the antibiotic placed within the wound to the wound exudate canister. Vancomycin and other antibiotic powders continue to represent a valuable addition in treating high-energy fractures, and may represent the optimal method of local antibiotic delivery for immediate tissue contact and infection treatment. Future efforts need to focus on broad-spectrum antimicrobial therapies that work against both Gram-positive and Gram-negative organisms and do not promote antibiotic resistance.

Supplementary material



A diagram of the study timeline, and the relevant ARRIVE guidelines.

References

1. Court-Brown CM, Bugler KE, Clement ND, Duckworth AD, McQueen MM. The epidemiology of open fractures in adults. A 15-year review. *Injury*. 2012;43(6):891–897.
2. Papakostidis C, Kanakaris NK, Pretel J, Faour O, Morell DJ, Giannoudis PV. Prevalence of complications of open tibial shaft fractures stratified as per the Gustilo-Anderson classification. *Injury*. 2011;42(12):1408–1415.
3. Blum ML, Esser M, Richardson M, Paul E, Rosenfeldt FL. Negative pressure wound therapy reduces deep infection rate in open tibial fractures. *J Orthop Trauma*. 2012;26(9):499–505.
4. Stannard JP, Volgas DA, Stewart R, McGwin G, Alonso JE. Negative pressure wound therapy after severe open fractures: a prospective randomized study. *J Orthop Trauma*. 2009;23(8):552–557.
5. Hake ME, Young H, Hak DJ, Stahel PF, Hammerberg EM, Mauffrey C. Local antibiotic therapy strategies in orthopaedic trauma: practical tips and tricks and review of the literature. *Injury*. 2015;46(8):1447–1456.
6. Carver DC, Kuehn SB, Weinlein JC. Role of systemic and local antibiotics in the treatment of open fractures. *Orthop Clin North Am*. 2017;48(2):137–153.
7. Morgenstern M, Vallejo A, McNally MA, et al. The effect of local antibiotic prophylaxis when treating open limb fractures: a systematic review and meta-analysis. *Bone Joint Res*. 2018;7(7):447–456.
8. Calhoun JH, Mader JT. Antibiotic beads in the management of surgical infections. *Am J Surg*. 1989;157(4):443–449.
9. Klemm KW. Antibiotic bead chains. *Clin Orthop Relat Res*. 1993;295:63–76.
10. Joseph TN, Chen AL, Di Cesare PE. Use of antibiotic-impregnated cement in total joint arthroplasty. *J Am Acad Orthop Surg*. 2003;11(1):38–47.
11. Wilson KJ, Cierny G, Adams KR, Mader JT. Comparative evaluation of the diffusion of tobramycin and cefotaxime out of antibiotic-impregnated polymethylmethacrylate beads. *J Orthop Res*. 1988;6(2):279–286.
12. Howlin RP, Brayford MJ, Webb JS, Cooper JJ, Aiken SS, Stoodley P. Antibiotic-loaded synthetic calcium sulfate beads for prevention of bacterial colonization and biofilm formation in periprosthetic infections. *Antimicrob Agents Chemother*. 2015;59(1):111–120.
13. McLaren AC, Nelson CL, McLaren SG, DeClerk GR. The effect of glycine filler on the elution rate of gentamicin from acrylic bone cement: a pilot study. *Clin Orthop Relat Res*. 2004;427:25–27.
14. Lemans JVC, Wijdicks SPJ, Boot W, et al. Intrawound treatment for prevention of surgical site infections in instrumented spinal surgery: a systematic comparative effectiveness review and meta-analysis. *Global Spine J*. 2019;9(2):219–230.
15. Sweet FA, Roh M, Sliva C. Intrawound application of vancomycin for prophylaxis in instrumented thoracolumbar fusions: efficacy, drug levels, and patient outcomes. *Spine*. 2011;36(24):2084–2088.
16. Tennent DJ, Shiels SM, Sanchez CJ, et al. Time-Dependent Effectiveness of Locally Applied Vancomycin Powder in a Contaminated Traumatic Orthopaedic Wound Model. *J Orthop Trauma*. 2016;30(10):531–537.
17. Hafeman AE, Zienkiewicz KJ, Carney E, et al. Local delivery of tobramycin from injectable biodegradable polyurethane scaffolds. *J Biomater Sci Polym Ed*. 2010;21(1):95–112.
18. Theologis AA, Demirkiran G, Callahan M, Pekmezci M, Ames C, Deviren V. Local intrawound vancomycin powder decreases the risk of surgical site infections in complex adult deformity reconstruction: a cost analysis. *Spine*. 2014;39(22):1875–1880.
19. Li B, Brown KV, Wenke JC, Guelcher SA. Sustained release of vancomycin from polyurethane scaffolds inhibits infection of bone wounds in a rat femoral segmental defect model. *J Control Release*. 2010;145(3):221–230.
20. Dedmond BT, Kortesis B, Punger K, et al. The use of negative-pressure wound therapy (NPWT) in the temporary treatment of soft-tissue injuries associated with high-energy open tibial shaft fractures. *J Orthop Trauma*. 2007;21(1):11–17.
21. Schlatterer DR, Hirschfeld AG, Webb LX. Negative pressure wound therapy in grade IIIB tibial fractures: fewer infections and fewer flap procedures? *Clin Orthop Relat Res*. 2015;473(5):1802–1811.
22. Rezzadeh KS, Nojan M, Buck A, et al. The use of negative pressure wound therapy in severe open lower extremity fractures: identifying the association between length of therapy and surgical outcomes. *J Surg Res*. 2015;199(2):726–731.
23. Liu DSH, Sofiadellis F, Ashton M, MacGill K, Webb A. Early soft tissue coverage and negative pressure wound therapy optimises patient outcomes in lower limb trauma. *Injury*. 2012;43(6):772–778.
24. Agarwal P, Kukrele R, Sharma D. Vacuum assisted closure (VAC)/negative pressure wound therapy (NPWT) for difficult wounds: A review. *J Clin Orthop Trauma*. 2019;10(5):845–848.
25. Virani SR, Dahapute AA, Bava SS, Muni SR. Impact of negative pressure wound therapy on open diaphyseal tibial fractures: a prospective randomized trial. *J Clin Orthop Trauma*. 2016;7(4):256–259.
26. Parrett BM, Matros E, Pribaz JJ, Orgill DP. Lower extremity trauma: trends in the management of soft-tissue reconstruction of open tibia-fibula fractures. *Plast Reconstr Surg*. 2006;117(4):1315–1322.
27. Stinner DJ, Hsu JR, Wenke JC. Negative pressure wound therapy reduces the effectiveness of traditional local antibiotic depot in a large complex musculoskeletal wound animal model. *J Orthop Trauma*. 2012;26(9):512–518.

28. **Rand BCC, Wenke JC.** An Effective Negative Pressure Wound Therapy-Compatible Local Antibiotic Delivery Device. *J Orthop Trauma.* 2017;31(12):631–635.
29. **USDA National Agricultural Library.** Animal welfare act. US Department of Agriculture. <https://www.nal.usda.gov/awic/animal-welfare-act> (date last accessed 12 January 2021).
30. **National Research Council.** *Guide for the care and use of laboratory animals.* Eighth ed. Washington (DC: National Academies Press (US), 2011. <https://www.ncbi.nlm.nih.gov/books/NBK54050/>
31. **Lalliss SJ, Stinner DJ, Waterman SM, Branstetter JG, Masini BD, Wenke JC.** Negative pressure wound therapy reduces *Pseudomonas* wound contamination more than *Staphylococcus aureus*. *J Orthop Trauma.* 2010;24(9):598–602.
32. **Pribaz JR, Bernthal NM, Billi F, et al.** Mouse model of chronic post-arthroplasty infection: noninvasive in vivo bioluminescence imaging to monitor bacterial burden for long-term study. *J Orthop Res.* 2012;30(3):335–340.
33. **Hedström SA, Lidgren L, Törholm C, Onnerfält R.** Antibiotic containing bone cement beads in the treatment of deep muscle and skeletal infections. *Acta Orthop Scand.* 1980;51(6):863–869.
34. **Hanssen AD, Osmon DR, Patel R.** Local antibiotic delivery systems: where are we and where are we going? *Clin Orthop Relat Res.* 2005;437:111–114.
35. **Gordon WT, Petrides MG, Gunn PA, Howard M.** Use of sterile pre-fabricated antibiotic beads in the combat hospital setting. *Mil Med.* 2013;178(3):330–333.
36. **Nelson CL.** The current status of material used for depot delivery of drugs. *Clin Orthop Relat Res.* 2004;427:72–78.
37. **Penn-Barwell JG, Murray CK, Wenke JC.** Local antibiotic delivery by a bioabsorbable gel is superior to PMMA bead depot in reducing infection in an open fracture model. *J Orthop Trauma.* 2014;28(6):370–375.
38. **Rand BCC, Penn-Barwell JG, Wenke JC.** Combined local and systemic antibiotic delivery improves eradication of wound contamination: an animal experimental model of contaminated fracture. *Bone Joint J.* 2015;97-B(10):1423–1427.
39. **Mackey D, Varlet A, Debeaumont D.** Antibiotic loaded plaster of Paris pellets: an in vitro study of a possible method of local antibiotic therapy in bone infection. *Clin Orthop Relat Res.* 1982;167:263–268.
40. **Noel SP, Courtney H, Bumgardner JD, Haggard WO.** Chitosan films: a potential local drug delivery system for antibiotics. *Clin Orthop Relat Res.* 2008;466(6):1377–1382.
41. **Zhou J, Zhou XG, Wang JW, Zhou H, Dong J.** Treatment of osteomyelitis defects by a vancomycin-loaded gelatin/β-tricalcium phosphate composite scaffold. *Bone Joint Res.* 2018;7(1):46–57.
42. **Stravinskas M, Nilsson M, Vitkauskienė A, Tarasevicius S, Lidgren L.** Vancomycin elution from a biphasic ceramic bone substitute. *Bone Joint Res.* 2019;8(2):49–54.
43. **Pavey GJ, Formby PM, Hoyt BW, Wagner SC, Forsberg JA, Potter BK.** Intrawound antibiotic powder decreases frequency of deep infection and severity of heterotopic ossification in combat lower extremity amputations. *Clin Orthop Relat Res.* 2019;477(4):802–810.
44. **Anghel EL, Kim PJ.** Negative-Pressure Wound Therapy: A Comprehensive Review of the Evidence. *Plast Reconstr Surg.* 2016;138(3 Suppl):129S–137S.
45. **Huang C, Leavitt T, Bayer LR, Orgill DP.** Effect of negative pressure wound therapy on wound healing. *Curr Probl Surg.* 2014;51(7):301–331.
46. **Glass GE, Murphy GF, Esmaeili A, Lai L-M, Nanchahal J.** Systematic review of molecular mechanism of action of negative-pressure wound therapy. *Br J Surg.* 2014;101(13):1627–1636.
47. **Birke-Sorensen H, Malmso J, Rome P, et al.** Evidence-based recommendations for negative pressure wound therapy: treatment variables (pressure levels, wound filler and contact layer)—steps towards an international consensus. *J Plast Reconstr Aesthet Surg.* 2011;64 Suppl:S1–S16.
48. **Hanasono MM, Skoracki RJ.** Securing skin grafts to microvascular free flaps using the vacuum-assisted closure (VAC) device. *Ann Plast Surg.* 2007;58(5):573–576.
49. **Calderon WL, Llanos S, Leniz P, Danilla S, Vielma R, Calderon D.** Double negative pressure for seroma treatment in trochanteric area. *Ann Plast Surg.* 2009;63(6):659–660.
50. **Collinge C, Reddix R.** The incidence of wound complications related to negative pressure wound therapy power outage and interruption of treatment in orthopaedic trauma patients. *J Orthop Trauma.* 2011;25(2):96–100.
51. **Pollak AN, Powell ET, Fang R, Cooper EO, Ficke JR, Flaherty SF.** Use of negative pressure wound therapy during aeromedical evacuation of patients with combat-related blast injuries. *J Surg Orthop Adv.* 2010;19(1):44–48.
52. **Fang R, Dorlac WC, Flaherty SF, et al.** Feasibility of negative pressure wound therapy during intercontinental aeromedical evacuation of combat casualties. *J Trauma.* 2010;69 Suppl 1(1):S140–S145.
53. **Stinner DJ, Noel SP, Haggard WO, Watson JT, Wenke JC.** Local antibiotic delivery using tailorable chitosan sponges: the future of infection control? *J Orthop Trauma.* 2010;24(9):592–597.
54. **Stinner DJ, Waterman SM, Masini BD, Wenke JC.** Silver dressings augment the ability of negative pressure wound therapy to reduce bacteria in a contaminated open fracture model. *J Trauma.* 2011;71(1 Suppl):S147–S150.
55. **Tennent DJ, Shiels SM, Jennings JA, Haggard WO, Wenke JC.** Local control of polymicrobial infections via a dual antibiotic delivery system. *J Orthop Surg Res.* 2018;13(1):53.

Author information:

- S. M. Shiels, PhD, Research Scientist
- J. C. Wenke, PhD, Research Physiologist
Orthopaedic Trauma Research Department, U.S. Army Institute of Surgical Research, San Antonio, Texas, USA.
- N. M. Sgromolo, MD, Surgical Resident, Research Resident, Orthopaedic Trauma Research Department, U.S. Army Institute of Surgical Research, San Antonio, Texas, USA; Department of Orthopaedic Surgery, Brooke Army Medical Center, San Antonio, Texas, USA.

Author contributions:

- S. M. Shiels: Contributed to the project concept, Designed and carried out the study, Analyzed the data, Drafted the manuscript.
- N. M. Sgromolo: Contributed to the project concept, Designed the study, Drafted the manuscript.
- J. C. Wenke: Contributed to the project concept, Designed the study, Analyzed the data, Drafted the manuscript.

Funding statement:

- No benefits in any form have been received or will be received from a commercial party related directly or indirectly to the subject of this article. This study was partially funded by the Combat Casualty Care Research Program.

ICMJE COI statement:

- S. M. Shiels and N. M. Sgromolo report an institutional grant from the Combat Care Casualty Research Program, related to the study.

Acknowledgements:

- The authors would like to thank the Orthopaedic Trauma Research Department and the Veterinary Support Group for their support.

© 2021 Author(s) et al. This is an open-access article distributed under the terms of the Creative Commons Attribution Non-Commercial No Derivatives (CC BY-NC-ND 4.0) licence, which permits the copying and redistribution of the work only, and provided the original author and source are credited. See <https://creativecommons.org/licenses/by-nc-nd/4.0/>.