

Corrections

Bobak P, Wroblewski BM, Siney PD, Fleming PA, Hall R. Charnley low-friction arthroplasty with an autograft of the femoral head for developmental dysplasia of the hip.

J Bone Joint Surg [Br] 2000;82-B:508-11.

On page 510 of this article the caption to Figures 1a and 1b should have identified the illustrations as Hartofilikadis type-B hips.

Rohlmann A, Bergmann G, Graichen F, Weber U. Changes in the loads on an internal spinal fixator after iliac-crest autograft.

J Bone Joint Surg [Br] 2000;82-B:445-9.

Figure 2, printed on page 447 of this article, was incomplete; the entire figure and caption are printed below.

Patel VR, Menon DK, Pool RD, Simonis RB. Nonunion of the humerus after failure of surgical treatment.

J Bone Joint Surg [Br] 2000;82-B:977-83.

In reference 10 of this paper, the first authors name was inadvertently spelt McKnee; this should have read McKee.

Kivioja A, Ervasti H, Kinnunen J, Kaitila I, Wolf M, Böhling WT. Chondrosarcoma in a family with multiple hereditary exostoses.

J Bone Joint Surg [Br] 2000;82-B:261-6.

The order of authors for this paper should be Kivioja A, Wolf M, Ervasti H, Kinnunen J, Böhling WT, Kaitila I.

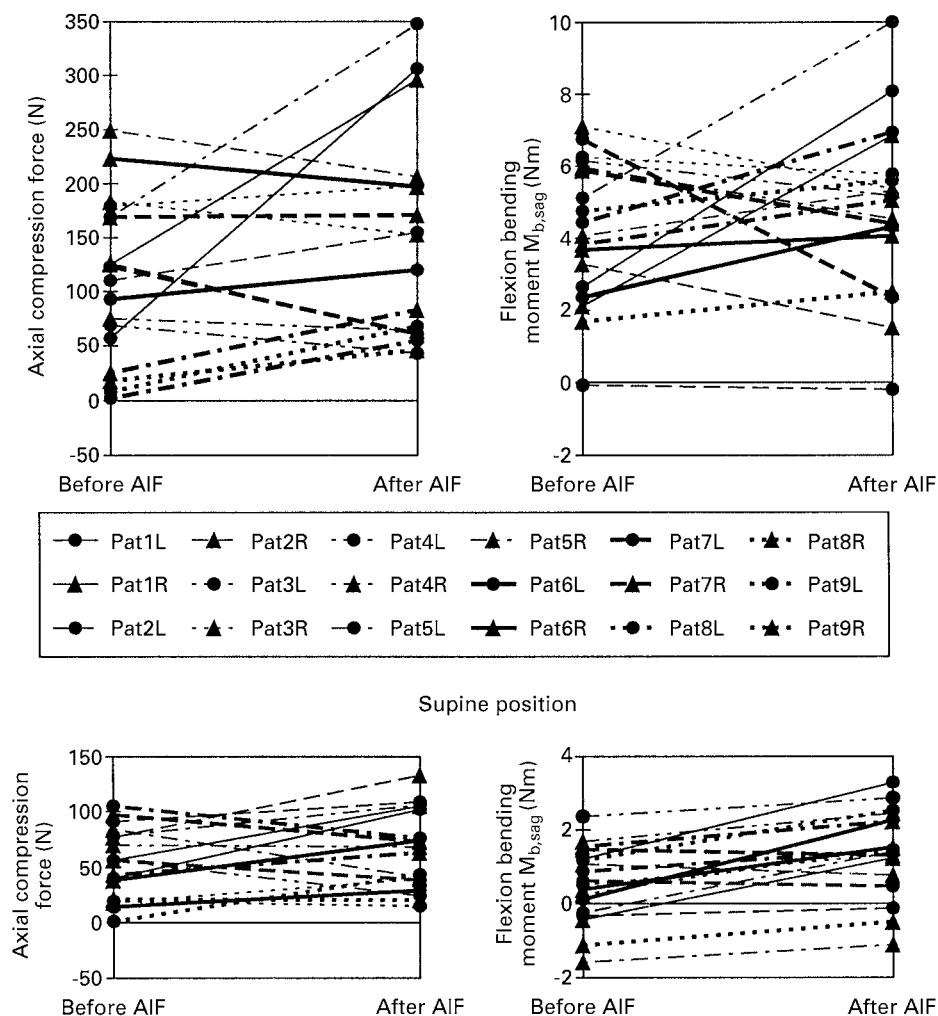


Fig. 2

Axial compression forces (left) and flexion bending moments in the sagittal plane (right) measured before and after AIF. The loads are given for the left and right fixators of nine patients measured for walking (top) and lying supine (bottom).