

## ■ SHOULDER & ELBOW

# A new method for evaluating radial neck fractures based on Judet classification

Y. C. Wang,  
J. J. Song,  
T. T. Li,  
D. Yang,  
Z. B. Lv,  
Z. Y. Wang,  
Z. M. Zhang,  
Y. Luo

From Shanghai  
Children's Hospital,  
Shanghai Jiao Tong  
University School of  
Medicine, Shanghai,  
China

### Aims

To propose a new method for evaluating paediatric radial neck fractures and improve the accuracy of fracture angulation measurement, particularly in younger children, and thereby facilitate planning treatment in this population.

### Methods

Clinical data of 117 children with radial neck fractures in our hospital from August 2014 to March 2023 were collected. A total of 50 children (26 males, 24 females, mean age 7.6 years (2 to 13)) met the inclusion criteria and were analyzed. Cases were excluded for the following reasons: Judet grade I and Judet grade IVb ( $> 85^\circ$  angulation) classification; poor radiograph image quality; incomplete clinical information; sagittal plane angulation; severe displacement of the ulna fracture; and Monteggia fractures. For each patient, standard elbow anteroposterior (AP) view radiographs and corresponding CT images were acquired. On radiographs, Angle P (complementary to the angle between the long axis of the radial head and the line perpendicular to the physis), Angle S (complementary to the angle between the long axis of the radial head and the midline through the proximal radial shaft), and Angle U (between the long axis of the radial head and the straight line from the distal tip of the capitellum to the coronoid process) were identified as candidates approximating the true coronal plane angulation of radial neck fractures. On the coronal plane of the CT scan, the angulation of radial neck fractures (CTa) was measured and served as the reference standard for measurement. Inter- and intraobserver reliabilities were assessed by Kappa statistics and intraclass correlation coefficient (ICC).

### Results

Angle U showed the strongest correlation with CTa ( $p < 0.001$ ). In the analysis of inter- and intraobserver reliability, Kappa values were significantly higher for Angles S and U compared with Angle P. ICC values were excellent among the three groups.

### Conclusion

Angle U on AP view was the best substitute for CTa when evaluating radial neck fractures in children. Further studies are required to validate this method.

Cite this article: *Bone Joint J* 2024;106-B(9):964–969.

### Introduction

Radial neck fractures are relatively uncommon, accounting for 1% of all children's fractures and ranging from 5% to 10% of elbow fractures.<sup>1,2</sup> For children with radial neck fractures with angulation  $> 30^\circ$  or displacement exceeding half of the width of the radial neck, anatomical reduction is desirable, but not when it requires open reduction in younger children.<sup>3,4</sup>

In 1962, Judet et al<sup>5</sup> proposed a classification for radial neck fractures to assess their severity

and guide treatment. In this classification grade I indicates a undisplaced fracture; grade II,  $< 30^\circ$  angulation and  $< 50\%$  displacement; grade III,  $30^\circ$  to  $60^\circ$  angulation and  $< 100\%$  displacement; grade IVa,  $60^\circ$  to  $80^\circ$  angulation and  $> 100\%$  displacement; and grade IVb,  $80^\circ$  to  $90^\circ$  angulation and  $> 100\%$  displacement. In 1965, O'Brien,<sup>6</sup> building upon Judet et al's<sup>5</sup> work, introduced his own classification and measurement system for angulation. In clinical practice, there is typically a  $10^\circ$  to  $15^\circ$  external rotation angle between the radial head

Correspondence should be sent to Y. Luo; email: luoy@shchildren.com.cn

© 2024 Wang et al.  
doi:10.1302/0301-620X.106B9.  
BJJ-2023-0986.R2 \$2.00

*Bone Joint J*  
2024;106-B(9):964–969.

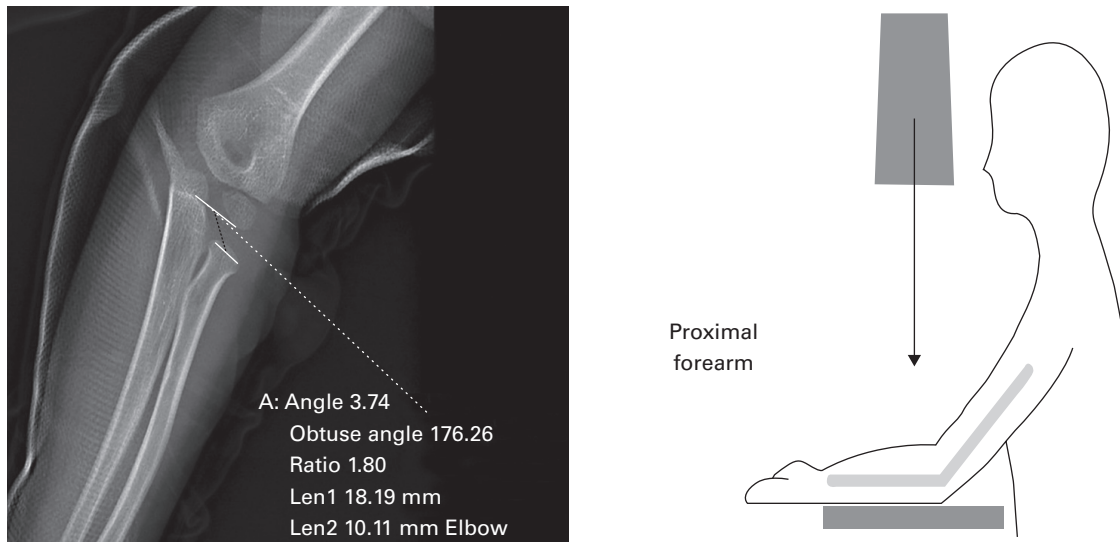


Fig. 1

Anteroposterior radiograph of a male patient aged three years and ten months. Position: elbow partially flexed, forearm parallel to image receptor.

and the radial shaft, with the radial tuberosity as the apex. This indicates that O'Brien's method tends to yield larger angulation measurements than the true angulation. Radial neck fracture angulation is defined as the angle between two lines: line 1 is the axis of the radial shaft (Angle S) and line 2 is parallel to the radial neck (perpendicular to the long axis of the radial head).<sup>6</sup>

Measurement of angulation often involves locating and drawing Angle P (complementary to the angle between the long axis of the radial head and the line perpendicular to the physis). There can be differences of opinion about the appropriate way to draw Angle P.<sup>7,8</sup> As radial neck fractures often affect the physis and the distal part of a fracture is usually shortened and curved, it is difficult to use as an anatomical landmark when measuring radiographs. To reduce error we applied indirect measurement using the angulation between the long axis of the radial head and the straight line through the epiphyseal plate of the capitellum (the axis of the elbow joint) (Figure 1).

The axis line of the elbow joint (Angle U) is the line connecting the radioulnar joint and the humeroulnar joint.<sup>9</sup> We proposed a new method by measuring the angulation between the long axis of the radial head and the straight line from the distal tip of the capitellum to the coronoid process in order to determine the angulation of a radial neck fracture. This study compared Angle U with Angle P and Angle S in terms of the difference to the angulation of radial neck fractures on the coronal plane of the CT scan (CTa).

## Methods

The clinical data of 117 children following the diagnosis of radial neck fracture in our hospital from August 2014 to March 2023 were retrospectively studied.

Inclusion criteria: 1) standard elbow anteroposterior (AP) radiograph, AP elbow (partially flexed), forearm parallel to image receptor (IR);<sup>4,10</sup> 2) CT imaging; and 3) the fracture angulation is on the coronal plane according to the CT.

Exclusion criteria: 1) Judet grade I; 2) improper quality of AP view or CT; 3) Type IV Monteggia fracture as radial neck displacement is associated with severe ulnar displacement;<sup>4</sup> and 4) congenital deformity of the ulna. A total of 50 patients (26 males and 24 females) with a mean age 7.6 years (2 to 13), involving 31 right-sided fractures and 19 left-sided fractures, met the inclusion criteria. The other 67 cases were excluded for the following considerations: 39 cases were Judet grade I; four cases were Judet grade IVb ( $> 85^\circ$ ); six had poor image quality, making assessment impossible; seven had incomplete clinical information; six had sagittal plane angulation; four had severe displacement of the ulnar fracture; and there was one Monteggia fracture. The ethics committee of our hospital approved the study.

Two senior paediatric orthopaedic surgeons (YCW, YL) and one senior radiologist (TTLi), blinded to this study, carried out the measurements in a picture archiving and communication system (Winning Health, China). The angulations of three measurements were drawn on each radiograph, as shown in Figure 2. Angulations of radial neck fracture were measured on CT coronal view and set as the reference value. The angulation between the long axis of the radial head and the straight line through the epiphyseal plate of the capitellum constituted the CT value (Figure 3). The three observers performed the measurements twice with the mean recorded as the actual value. Lateral views are not within the scope of this study.

**Statistical analysis.** Statistical analysis was performed using SPSS v. 25 (IBM, USA). All data were described as mean and SD. The statistical significance was set at a p-value  $< 0.05$  with a 95% CI. First, we used ggplot for visualization and compared the differences in angles between the three methods and the reference standard CTa. Using the R programming language (R Foundation for Statistical Computing, Austria), we created a plot to depict these differences. Second, we compared the deviation of the three methods to CT angulations. Not all quantitative

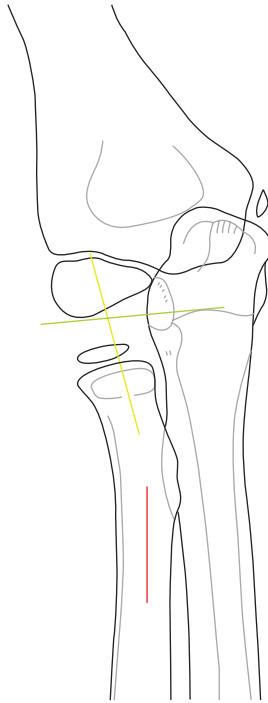


Fig. 2

Elbow joint anteroposterior view: angle P complementary to the angle between the the long axis of radial head and the straight line (yellow line) perpendicular to the articular surface of capitellum, angle S complementary to the angle between the the long axis of radial head and the straight line (red line) through proximal radial shaft, and angle U between the the long axis of radial head and the straight line (green line) from distal tip of capitellum to coronoid process.

data in different groups passed the normality test of the Shapiro-Wilk or Kolmogorov-Smirnov test. Therefore, the Wilcoxon signed-rank test was used to analyze the non-parametric data. Third, inter- and intraobserver reliabilities were assessed. For Kappa statistics, the Judet classification was used for grouping. Fleiss's Kappa ( $n = 3$ ) for interobserver reliability and Cohen's Kappa ( $n = 2$ ) were applied for intraobserver reliability. In addition, the intraclass correlation coefficient (ICC) was calculated. Both Fleiss's Kappa and ICC values were expressed as measurements with 95% CI.

## Results

A total of 150 angulations (Angle P, Angle S, and Angle U) were evaluated on radiographs. Angle U exhibited the strongest mean correlation and smallest differences with the CTa ( $1.00^\circ$  (SD  $2.12^\circ$ )) compared with the CTa of Angle P ( $7.90^\circ$  (SD  $4.24^\circ$ )) and Angle S ( $5.23^\circ$  (SD  $3.22^\circ$ )). Angle U approximates most closely to the standard CT measurements (Figure 4).

The absolute differences between the three measurements and the CTa were compared. The results indicated a significant difference between the three measurements ( $p < 0.001$ , Mann-Whitney U test). Angle U, which had the largest 95% CIs and the smallest intergroup error, was identified as the optimal method (Figure 5).

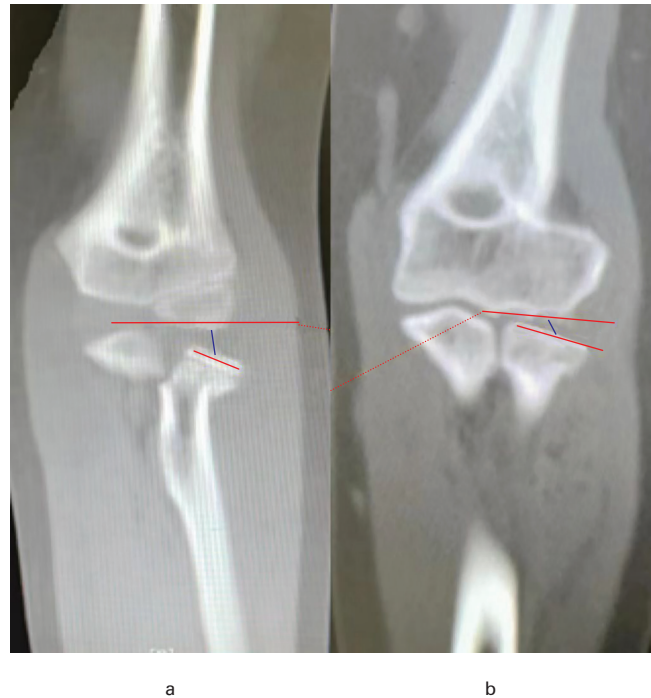

Fig. 3

Angulations of radial neck fracture were measured on CT coronal view, by measuring the angulation between the long axis of the radial head and the straight line through the epiphyseal plate of the capitellum. a) Eight-year-old male. b) 14-year-old female.

The interobserver reliability for the Judet classification was higher when using Angles S and U, reaching excellent agreement but only good agreement when using Angle P (Table I). Based on 95% CI, there were significant increases in reliability for Angles S and U compared with Angle P (Table I). Furthermore, the ICC values of the three groups were excellent, and there was a significant increase in reliability for Angle U compared with Angle P (Table II).

When analyzing the intraobserver reliability, it was observed that the three evaluators exhibited comparable mean Kappa values (0.856, 0.827, and 0.756) throughout, indicative of a reliability level ranging from substantial to almost perfect. The observers, when using Angles S and U, achieved a relatively higher mean Kappa value (Table III) compared with Angle P, however this did not reach statistical significance. Regarding the ICC analysis, the three observers exhibited comparable mean ICC values (0.987, 0.987, and 0.975) throughout the analysis, indicative of an excellent reliability level. The other ICC results were similar to the Kappa results (Table IV).

## Discussion

Paediatric radial neck fracture is uncommon in children. It occurs by two main mechanisms: one involves pronating the forearm with internal rotation, while the other results from indirect forces transmitted from a fall on the outstretched hand. Both lead to compression on the joint between the radius and humerus, causing radial neck fractures.<sup>11</sup> The prognosis depends on the ability to achieve an acceptable reduction

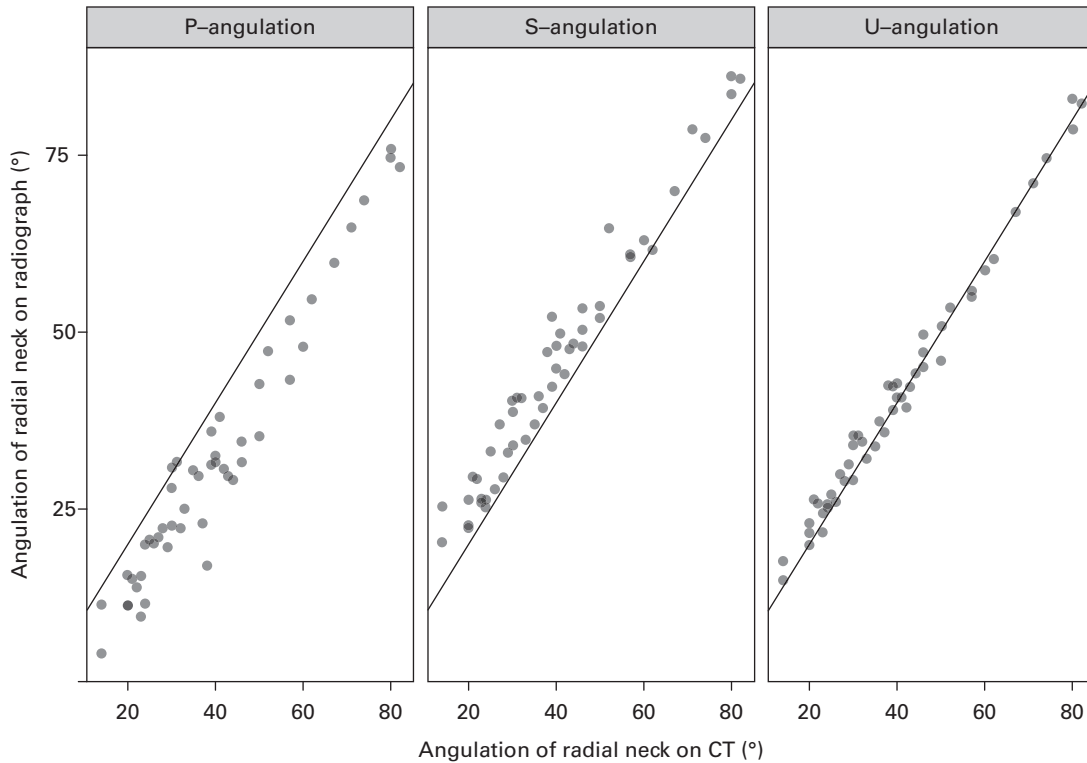


Fig. 4

Scatter plots displaying the correlation between the three methods and CT angulation.

**Table I.** Kappa coefficients for interobserver reliability when using three distinct methods.

Evaluation method	K (95% CI)	Z
P-angulation	0.750 (0.746 to 0.754)	11.791
S-angulation	0.892 (0.889 to 0.896)	16.564
U-angulation	0.886 (0.882 to 0.890)	14.842

K, kappa measure; Z, zeta score.

**Table II.** Intraclass correlation coefficient for interobserver reliability when using the three distinct methods.

Evaluation method	ICC (95% CI)	F
P-angulation	0.967 (0.947 to 0.980)	92.681
S-angulation	0.986 (0.977 to 0.991)	218.345
U-angulation	0.991 (0.986 to 0.995)	342.912

F, Fisher value; ICC, intraclass correlation coefficient.

without opening the fracture and preferably without internal fixation. However, there is still a significant risk of unsatisfactory functional outcomes, with an overall complications rate of 15% to 33%.<sup>12,13</sup> The literature shows that the prognosis and functional recovery of radial neck fractures in children are influenced by various factors, including age, fracture type, and timing of surgery.<sup>14-16</sup> Accurate measurement of the fracture angulation, and classification of the fracture displacement, facilitate providing the most appropriate treatment for favourable outcomes and minimizing long-term sequelae.

The inclination of the epiphyseal plate of the radial neck in young children, which is curved at the proximal metaphysis of the radius, makes it difficult for assessors to bisect it accurately and can lead to poor stability of the Angle P identification.<sup>17</sup> In addition, these fractures often involve the physis, making it more difficult to use the line perpendicular to the physis (Angle P) as a reference. Additionally, the extent of elbow flexion and angulation of the x-ray beam will influence the projection of Angle P. For very young patients, the capitellum is not fully ossified, but the semi-flexed elbow with the x-ray beam either

perpendicular to the forearm or the humerus, the line between the shadow of the capitellum and the coronoid process is close to parallel to the long axis of the radial head.<sup>18</sup> A fully extended AP view of the elbow could result in an over-measured Angle U. Fortunately, most radial neck fractures occur in children between the age of seven and 12 years,<sup>19</sup> when the ossification of the capitellum is already stable, resulting in a reliable U value. Therefore, Angle U measurement may be more dependable than that obtained by Angle P. This is consistent with the differences in intragroup and intergroup Kappa values calculated in our study. Because of a 10° to 15° external rotation angle between the radial head and the radial shaft, Angle U may be closer to the real angulation of the bone fracture than Angle S. Further studies are needed to validate the practicality of Angle U measurement.

In clinical practice, patients often have an angulation > 30° and a translation < 50%, or an angulation > 60° and a translation < 100%. This can greatly impact the clinical decision-making process. Therefore, minimizing angular measurement errors to the smallest possible range is of great importance.

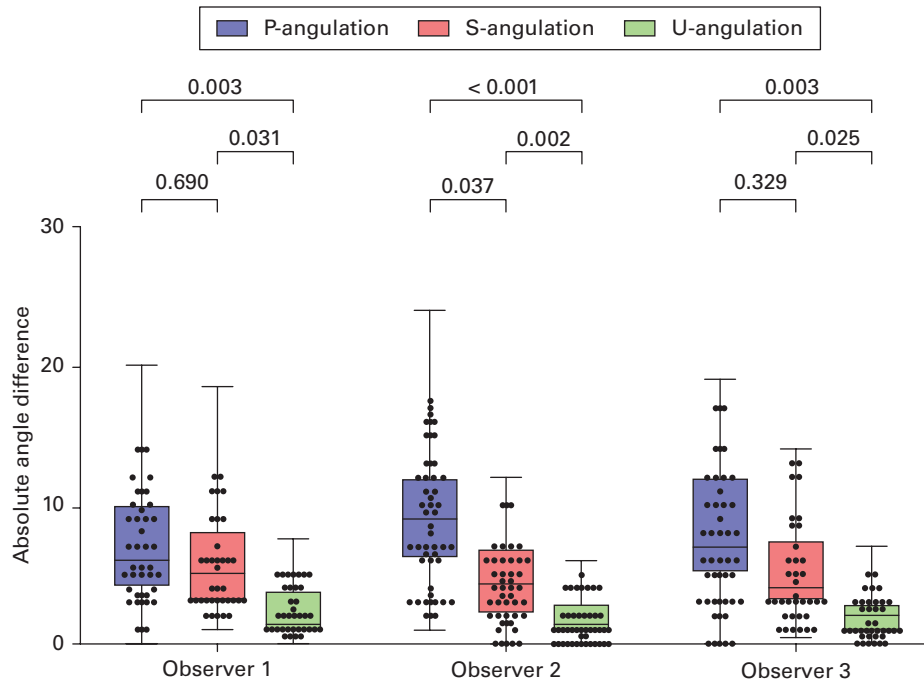


Fig. 5

P-angulation, S-angulation, and U-angulation in comparison to CT, measured by three different observers.

**Table III.** Kappa coefficients for intraobserver reliability when using the three distinct methods.

Evaluation method	Observer (K)			Mean (SD)
	OB1	OB2	OB3	
P-angulation	0.769	0.789	0.505	0.688 (0.159)
S-angulation	0.934	0.902	0.834	0.890 (0.051)
U-angulation	0.864	0.790	0.929	0.861 (0.070)
Mean (SD)	0.856 (0.083)	0.827 (0.064)	0.756 (0.223)	0.813 (0.131)

K, kappa measure; OB, observer.

**Table IV.** Intraclass correlation coefficient for intraobserver reliability when using the three distinct methods.

Evaluation method	Observer (ICC)			Mean (SD)
	OB1	OB2	OB3	
P-angulation	0.980	0.980	0.949	0.970 (0.002)
S-angulation	0.990	0.990	0.985	0.988 (0.002)
U-angulation	0.993	0.991	0.991	0.992 (0.001)
Mean (SD)	0.987 (0.007)	0.987 (0.006)	0.975 (0.002)	0.983 (0.013)

ICC, intraclass correlation coefficient; OB, observer.

The use of Angle U improves determining whether reduction is necessary for children with radial neck fractures between Judet II and Judet III grades. When the angulation of fracture falls within the range of 25° to 35° and < 50% displacement, further examinations such as CT or MRI may be required for accurate measurement. CT scans are expensive and raise concerns about higher radiation exposure. MRI typically requires sedation, especially for young patients. In another situation when assessing the feasibility of closed reduction under sedation in the emergency department (between Judet III and Judet IV fractures), some researchers have suggested that closed reductions for children with angulation > 60° and < 100% displacement have a lower success rate when performed under emergency sedation.<sup>6</sup> Accuracy in measuring angulation also helps determine the need for open reduction during surgery and postoperative functional recovery (between Judet III and Judet IV). Closed reduction with an angle greater than 60° has a high likelihood of failure. The prognosis of these cases is relatively poor, and some patients may experience severe joint dysfunction, which can even lead to litigation.<sup>20-22</sup> For patients with an angle greater than 60° and < 100% displacement, it is

important to provide them with sufficient preoperative information regarding an unfavourable prognosis. Through Angle U, we can reduce the variation of the angulation measurement to within 5°. This method is convenient to perform, and allows junior doctors to obtain actual angulation directly from radiographs and to develop appropriate treatment plans. This also obviates the need for CT scans and MRI, sparing the child from radiation exposure or sedation.

Our study has some limitations. First, further validation and confirmation of our findings are needed with a larger sample size. Second, there is still some deviation between the angle measured by CT values and the actual angulation, although the CT angle is regarded as the standard. Third, the Angle U measurement requires a standard radiograph in a neutral position. Theoretically, pronation or supination may lead to inaccuracy in the measurement.

Angle U offers clinicians a new method for assessing the angulation of radial neck fractures. This measurement facilitates accurate clinical classification of radial neck fracture introduced by Judet et al<sup>5</sup> on plain radiographs, without the need for CT or MRI. Additional studies are required to demonstrate its utility.



### Take home message

- The results of this study offer clinicians a new method to assess radial neck fractures in clinical practice, guiding treatment decisions and ultimately improving patient outcomes.

### References

1. Bither N, Gupta P, Jindal N. Pediatric displaced radial neck fractures: retrospective results of a modified Metaizeau technique. *Eur J Orthop Surg Traumatol*. 2015;25(1):99–103.
2. Gutiérrez-de la Iglesia D, Pérez-López LM, Cabrera-González M, Knörr-Giménez J. Surgical techniques for displaced radial neck fractures: predictive factors of functional results. *J Pediatr Orthop*. 2017;37(3):159–165.
3. Çevik N, Cansabuncu G, Akalın Y, Otuzbir A, Öztürk A, Özkan Y. Functional and radiological results of percutaneous K-wire aided Métaizeau technique in the treatment of displaced radial neck fractures in children. *Acta Orthop Traumatol Turc*. 2018;52(6):428–434.
4. Staheli LT. *Practice of Pediatric Orthopedics*. Philadelphia, Pennsylvania, USA: Lippincott Williams & Wilkins, 2006.
5. Judet J, Judet R, Lefranc J. Fracture of the radial head in the child. *Ann Chir*. 1962;16:1377–1385.
6. O'Brien PI. Injuries involving the proximal radial epiphysis. *Clin Orthop Relat Res*. 1965;41:51–58.
7. Fader LM, Laor T, Eismann EA, Cornwall R, Little KJ. Eccentric capitellar ossification limits the utility of the radiocapitellar line in young children. *J Pediatr Orthop*. 2016;36(2):161–166.
8. Ramirez RN, Ryan DD, Williams J, et al. A line drawn along the radial shaft misses the capitellum in 16% of radiographs of normal elbows. *J Pediatr Orthop*. 2014;34(8):763–767.
9. Goldfarb CA, Patterson JMM, Sutter M, Krauss M, Steffen JA, Galatz L. Elbow radiographic anatomy: measurement techniques and normative data. *J Shoulder Elbow Surg*. 2012;21(9):1236–1246.
10. Bontrager KL, Lampignano J. *Workbook for Textbook of Radiographic Positioning and Related Anatomy-E-Book*. Elsevier Health Sciences, 2013.
11. Monson R, Black B, Reed M. A new closed reduction technique for the treatment of radial neck fractures in children. *J Pediatr Orthop*. 2009;29(3):243–247.
12. Schmittenebecher PP, Haevernick B, Herold A, Knorr P, Schmid E. Treatment decision, method of osteosynthesis, and outcome in radial neck fractures in children: a multicenter study. *J Pediatr Orthop*. 2005;25(1):45–50.
13. Kalbitz M, Lackner I, Perl M, Pressmar J. Radial head and neck fractures in children and adolescents. *Front Pediatr*. 2022;10:988372.
14. Nicholson LT, Skaggs DL. Proximal radius fractures in children. *J Am Acad Orthop Surg*. 2019;27(19):e876–e886.
15. Garcia-Alvarez F, Gil-Albarova J, Bello ML, Bueno AL, Seral F. Results in displaced radial neck fractures in children. Metaizeau technique versus arthrotomy. *Chir Organi Mov*. 2001;86(3):211–217.
16. Kumar S, Mishra A, Odak S, Dwyer J. Treatment principles, prognostic factors and controversies in radial neck fractures in children: a systematic review. *J Clin Orthop Trauma*. 2020;11:S456–S463.
17. Fader LM, Laor T, Eismann EA, Cornwall R, Little KJ. MR imaging of capitellar ossification: a study in children of different ages. *Pediatr Radiol*. 2014;44(8):963–970.
18. Pace JL, Wiater B, Schmale G, Jinguji T, Bompadre V, Krengel W. Baumann angle and radial-ulnar overlap: a radiographic study to control for the angle of the x-ray beam. *J Pediatr Orthop*. 2012;32(5):467–472.
19. Lovell WW, Winter RB, Morrissy RT, Weinstein SL. *Lovell and Winter's Pediatric Orthopaedics*. Philadelphia, Pennsylvania, USA: Lippincott Williams & Wilkins, 2006.
20. D'souza S, Vaishya R, Klenerman L. Management of radial neck fractures in children: a retrospective analysis of one hundred patients. *J Pediatr Orthop*. 1993;13(2):232–238.
21. Zimmerman RM, Kalish LA, Hresko MT, Waters PM, Bae DS. Surgical management of pediatric radial neck fractures. *J Bone Joint Surg Am*. 2013;95-A(20):1825–1832.
22. Fowles JV, Kassab MT. Observations concerning radial neck fractures in children. *J Pediatr Orthop*. 1986;6(1):51–57.

### Author information:

Y. C. Wang, MD, Orthopaedic Surgeon  
D. Yang, PhD, Orthopaedic Surgeon  
Z. Y. Wang, PhD, Orthopaedic Surgeon  
Z. M. Zhang, MD, Orthopaedic Surgeon  
Y. Luo, MD, Orthopaedic Surgeon  
Department of Orthopedics, Shanghai Children's Hospital, Shanghai Jiao Tong University School of Medicine, Shanghai, China.

J. J. Song, PhD, Research Assistant, Teaching Office, Shanghai Children's Hospital, Shanghai Jiao Tong University School of Medicine, Shanghai, China.

T. T. Li, PhD, Radiologist, Department of Radiology, Shanghai Children's Hospital, Shanghai Jiao Tong University School of Medicine, Shanghai, China.

Z. B. Lv, MD, Pediatric General Surgeon, Department of General Surgery, Shanghai Children's Hospital, Shanghai Jiao Tong University School of Medicine, Shanghai, China.

### Author contributions:

Y. C. Wang: Resources, Writing – original draft, Writing – review & editing.  
J. J. Song: Data curation, Formal analysis, Methodology, Software.  
T. T. Li: Resources, Software, Visualization.  
D. Yang: Validation, Visualization, Funding acquisition.  
Z. B. Lv: Conceptualization, Project administration.  
Z. Y. Wang: Formal analysis, Software.  
Z. M. Zhang: Conceptualization, Data curation, Project administration, Writing – original draft.  
Y. Luo: Data curation, Visualization, Writing – original draft, Writing – review & editing.

Y. C. Wang and J. J. Song are joint first authors.

Z. M. Zhang and Y. Luo are joint senior authors.

### Funding statement:

The authors disclose receipt of the following financial or material support for the research, authorship, and/or publication of this article: the present study was supported by the National Natural Science Foundation of China (no. 82002839), Shanghai Sailing Program (No. 20YF1440800).

### ICMJE COI statement:

D. Yang reports that the study was supported by the National Natural Science Foundation of China (no. 82002839), Shanghai Sailing Program (No. 20YF1440800). The authors declare that they have no competing interests. All authors declare that they have no financial and personal relationships with other people or organizations that could inappropriately influence their work. There are no conflicts of interest regarding employment, consultancies, stock ownership, honoraria, paid expert testimony, patent applications/registrations, and grants or other funding.

### Data sharing:

All the data used in the article can be obtained from the medical record information system of Shanghai Children's Hospital. Any questions or enquiries regarding the present study can be directed to the corresponding author.

### Ethical review statement:

The Medical Ethical Commission of the Shanghai Children's Hospital approved this study. The participants signed an informed consent form before participation.

### Open access funding:

The open access fee for this article was self-funded.

### Open access statement:

This article is distributed under the terms of the Creative Commons Attribution (CC BY 4.0) licence (<https://creativecommons.org/licenses/by/4.0/>), which permits unrestricted use, distribution, and reproduction in any medium or format, provided the original author and source are credited.

This article was primary edited by G. Scott.