



## ■ GENERAL ORTHOPAEDICS

## Analysis of retrieved STRYDE nails

**H. Hothi,  
S. Bergiers,  
J. Henckel,  
A. D. Iliadis,  
W. D. Goodier,  
J. Wright,  
J. Skinner,  
P. Calder,  
A. J. Hart**

From The Royal  
National Orthopaedic  
Hospital, London, UK

**Aims**

The aim of this study was to present the first retrieval analysis findings of PRECICE STRYDE intermedullary nails removed from patients, providing useful information in the post-market surveillance of these recently introduced devices.

**Methods**

We collected ten nails removed from six patients, together with patient clinical data and plain radiograph imaging. We performed macro- and microscopic analysis of all surfaces and graded the presence of corrosion using validated semiquantitative scoring methods. We determined the elemental composition of surface debris using energy dispersive x-ray spectroscopy (EDS) and used metrology analysis to characterize the surface adjacent to the extendable junctions.

**Results**

All nails were removed at the end of treatment, having achieved their intended lengthening (20 mm to 65 mm) and after regenerate consolidation. All nails had evidence of corrosion localized to the screw holes and the extendable junctions; corrosion was graded as moderate at the junction of one nail and severe at the junctions of five nails. EDS analysis showed surface deposits to be chromium rich. Plain radiographs showed cortical thickening and osteolysis around the junction of six nails, corresponding to the same nails with moderate – severe junction corrosion.

**Conclusion**

We found, in fully united bones, evidence of cortical thickening and osteolysis that appeared to be associated with corrosion at the extendable junction; when corrosion was present, cortical thickening was adjacent to this junction. Further work, with greater numbers of retrievals, is required to fully understand this association between corrosion and bony changes, and the influencing surgeon, implant, and patient factors involved.

**Cite this article:** *Bone Jt Open* 2021;2-8:599–610.

**Keywords:** Limb lengthening, STRYDE nail, Retrieval analysis, PRECICE lengthening nail

**Introduction**

The concept of using osteoclasts to perform limb lengthening is now an established orthopaedic procedure.<sup>1-3</sup> Traditionally this has been achieved using external fixators however these have been associated with complications including pin site infections, long treatment times, and joint stiffness. The PRECICE (NuVasive Specialised Orthopaedics (NSO), USA) intramedullary nail overcame these limitations by being fully implantable in the patient.<sup>4-9</sup> Lengthening was achieved using an external magnetic remote controller which interacted with magnets within the nail, which in turn activated the internal

lengthening mechanism. The PRECICE nail, made of a titanium alloy casing, is permitted for use with partial weight-bearing in patients with a maximum weight of 57 kg to 114 kg, depending on the limb being treated, the nail diameter, and the specific PRECICE model used.<sup>10</sup>

The PRECICE STRYDE (NSO) nail system, CE-marked in February 2019, has a number of design modifications and is made of a tougher Biodur 108 stainless steel alloy, making it between 1.3 and 2.5 times stronger than previous PRECICE nails in terms of its four point bending and fatigue loads and distraction torque.<sup>11</sup> The STRYDE nail is permitted

Correspondence should be sent to  
Harry Hothi; email:  
h.hothi@ucl.ac.uk

doi: 10.1302/2633-1462.28.BJO-  
2021-0126

*Bone Jt Open* 2021;2-8:599–610.



Fig. 1

Macroscopic images of all ten nails examined in this study. There are no indications of gross mechanical damage and macroscopically discolouration of the surface is observed around the junction of the housing tube and distraction rod, the distraction rod itself, and the screw holes.

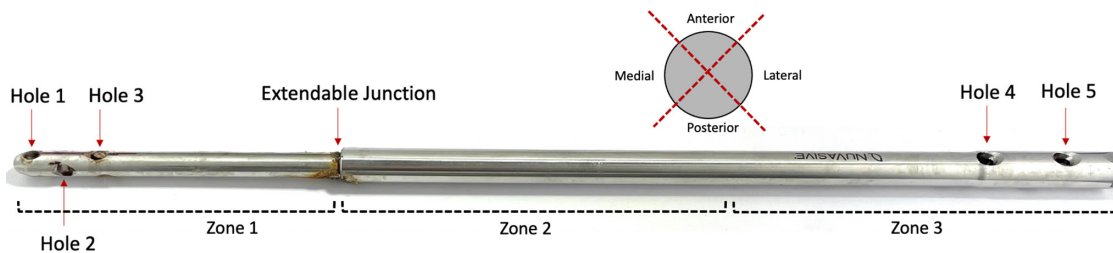


Fig. 2

The presence and severity of surface damage was graded for each nail, separated visually into their anterior, posterior, medial, and lateral sides and into their extendable and housing sections. Corrosion grading was performed for each screw hole and the extendable junction of the nails, as labelled.

for use with weight-bearing in patients weighing up to 69 kg to 114 kg, depending on the limb, STRYDE model, and nail diameter. In accordance with ASTM F2229,<sup>12</sup> the constituent elements of Biodur 108 include manganese (21% to 24% (mass/mass)) and chromium (19% to 23% (mass/mass)).

STRYDE nails serve to stabilize bone while they are magnetically lengthened at a typical rate of 1 mm/day until the desired lengthening has been achieved; the nails have a maximum lengthening stroke of 5 cm, 6.5 cm, and 8 cm, depending on the size of nail used.<sup>11</sup> The nails are retained until the regenerate has fully formed and strengthened, after which time they are routinely removed.

On 20 January 2021, NSO issued a voluntary recall and suspension of supply of all their PRECICE systems implants in the UK, while safety concerns raised by the UK Medicines and Healthcare products Regulatory Agency (MHRA) are addressed.<sup>13</sup> This was due, in part, to concerns raised by our unit with the MHRA regarding osteolysis, periosteal reactions, and/or cortical hypertrophy in patients implanted with STRYDE nails.<sup>14</sup> Similar evidence of these bony reactions has now been seen

elsewhere, which may be associated with potential corrosion of the nail.<sup>15</sup>

The aim of this study was to present retrieval analysis findings of STRYDE nails removed from patients, providing useful information in the post-market surveillance of these recently introduced devices.

## Methods

This was a retrieval study involving the analysis of ten STRYDE nails (six femoral and four tibial) removed by two surgeons from six female patients (Figure 1).

Four out of the six patients were lengthened bilaterally for cosmetic reasons: two of these patients had a short stature of unknown origin, one patient had spondyloepiphyseal dysplasia, and one patient had achondroplasia. Two patients were implanted with unilateral femoral nails to correct leg length discrepancies (LLDs) of 40 mm and 30 mm.

The patients were aged 14, 18 ( $n = 2$ ), 19, 44, and 64 years at the time of implantation. We collected data on the time to removal of each nail, the reason for removal, and associated clinical information including symptoms,

examination findings, microbiological data, plain radiological imaging, and blood metal ion measures.

**Plain radiographs.** We collected immediate postimplantation and prerule plain radiographs for each patient, in order to determine if bone union had been achieved and if any other bony changes were evident. All patients provided informed consent for their implants and associated clinical data to be investigated at our implant centre. This research was approved by London-Riverside REC: Implant Study - 07/Q0401/25.

**Radiograph imaging.** All retrieved nails underwent radiograph imaging using a medical radiograph scanner at 60 kV and 4 mA, in order to visualize the state of their internal mechanism.

**Surface damage.** The nails were macroscopically analyzed in order to determine the extent and location of any surface damage present. Regions in which damage or other surface changes were found to occur were photographed using a Canon EOS 6D DSLR Camera and a Canon 100 mm macro L lens (Canon, Japan). A Keyence VHX-700F optical microscope was used to further investigate regions of damage identified macroscopically, using imaging magnifications of between  $\times 20$  and  $\times 50$ .

The presence and severity of six damage features was then graded based on previous definitions used in implant retrieval analysis:<sup>16</sup> scratching, discolouration, cracking, galling, pitting, and fretting. Grading was performed on scale of 0 to 3; a score of 0 indicated no evidence of the damage feature in question; a score of 1 indicated < 25% of the surface area was affected; a score of 2 indicated between 25% and 75% of the area was affected; and a score of 3 indicated > 75% of the area affected by the damage feature. To assist with damage grading, each nail was separated visually into three different zones, with zone 1 covering the extendable section of the nail, and zones 2 and 3 bisecting the housing tube of the nail (Figure 2). The nails were further subdivided along their length, into their anterior, posterior, medial, and lateral sides (Figure 2); a total of 12 different sections were therefore defined for each nail and each section graded separately.

**Corrosion scoring.** The presence and severity of visually evident corrosion was evaluated at each of the screw-nail junctions and at the junction of the extendable region of the nails. Corrosion grading was performed using the Goldberg scoring criteria, which was first developed to evaluate hip stem-head junctions.<sup>17</sup> This is a semiquantitative grading classification method which has proven repeatability and reproducibility.<sup>18</sup>

Each junction was graded with a score of between 1 (indicating no evidence of corrosion) and 4 (evidence of severe corrosion). In the tibial nails, there were six nail-screw hole junctions (three either side of the extendable junction) and five screw holes in the femoral nails (Figure 2).

**Energy dispersive x-ray spectroscopy.** Energy dispersive x-ray spectroscopy (EDS) analysis was performed on surface deposits on five nails that were visually evaluated as having evidence of severe corrosion, using a Carl Zeiss EVO25 scanning electron microscope (SEM; Carl Zeiss, Germany). This analysis was used to identify the chemical composition of the deposits, in order to confirm that corrosion had occurred.

**Metrology analysis.** We used a Talyrond 365 (Taylor Hobson, UK) roundness measuring machine with a 5-micron diamond tipped stylus to capture 5 mm linear surface traces emanating from the junction of the housing tube and distraction rod of each nail. Traces were captured on the region around the junction that was visually identified as having the greatest surface changes; line scans were recorded every 2° around the nail, to a total of 150°. The line scans were combined to generate a surface damage map for each nail.

## Results

The planned lengthening amount of 50 mm, 50 mm, 65 mm, 50 mm, 34 mm, and 20 mm was achieved for patients 1 to 6, respectively; the regenerate had consolidated in all cases. All nails were removed as planned after having been implanted for between nine and 16 months. Table I summarizes the clinical variables that were collected for each patient. Table II presents that measures of blood metal ion levels (titanium, cobalt, and chromium) that were captured prior to removal of the nails.

Prior to removal, Patient 1 experienced severe pain in their left tibia and mild pain in their right. Patient 2 had no symptoms of pain. Patient 3 reported bilateral mid-thigh pain. Patient 4 experienced tibial pain and erythema at six months postimplantation, which resolved with Flucloxacillin and removal of the distal locking screws. Patients 5 and 6 also reported thigh pain.

**Plain radiographs.** Figure 3 presents the plain radiographs captured for each patient following implantation of the nails and prior to their removal. These showed evidence of cortical thickening where bone union had occurred, as expected. Cortical thickening and osteolysis was also observed distally, localized to the bony regions around the extendable junction, in the left tibia of Patient 1, right femur of Patient 2, both femora of Patient 3, and in the right and left femora of Patients 5 and 6 respectively.

### Microbiological and histological findings

**Patient 1.** Tissue samples taken from the right tibia at the time of nail removal grew *Staphylococcus aureus*. Samples taken from the left tibia grew *Staphylococcus epidermidis* and *Paenibacillus Sordellii*. Histology showed no evidence of acute infection or inflammation.

**Patient 2.** There was no growth from microbiology specimens taken at the time of nail removal. The histology

**Table I.** Summary of the clinical data associated with these retrieved nails.

Variable	Patient 1	Patient 2	Patient 3	Patient 4	Patient 5	Patient 6
Site	Tibia	Femur	Femur	Tibia	Femur	Femur
Nails, n	2	2	2	2	1 (right)	1 (left)
Sex	Female	Female	Female	Female	Female	Female
Reason for implantation	Cosmetic due to short stature	Cosmetic due to short stature	Cosmetic due to short stature	Cosmetic due to short stature	Correct LLD	Correct LLD
Age at implantation, yrs	14	18	44	18	19	64
Planned lengthening, mm	50	50	50 to 65	50	34	20
Achieved lengthening, mm	50	50	65	50	24	20
Time to removal of left nail, mths	11	13	16	10	N/A	10
Time to removal of right nail, mths	11	13	16	10	11	N/A
Bone union achieved (left)	Yes	Yes	Yes	Yes	N/A	Yes
Bone union achieved (right)	Yes	Yes	Yes	Yes	Yes	N/A
Reason for removal (left)	Planned	Planned	Planned	Planned	Planned	Planned
Reason for removal (right)	Planned	Planned	Planned	Planned	Planned	Planned
Radiological observations (left)	Cortical thickening at extendable junction	No unexpected bony changes	Cortical thickening at extendable junction	No unexpected bony changes	N/A	Slight cortical thickening at extendable junction of nail
Radiological observations (right)	No unexpected bony changes	Cortical thickening at extendable junction	Cortical thickening at extendable junction	No unexpected bony changes	Cortical thickening at extendable junction of nail	N/A
Symptoms (left)	Severe pain	No symptoms of pain	Significant mid-thigh pain	No symptoms of pain	N/A	Mild thigh pain
Symptoms (right)	Mild pain	No symptoms of pain	Significant mid-thigh pain	Mild pain	Significant thigh pain	N/A

LLD, leg length discrepancy; N/A, not applicable.

report suggested periprosthetic reaction to wear debris with no evidence of acute infection.

**Patient 3.** There was no growth from microbiology specimens taken at the time of nail removal. The histology report showed a non-specific chronic histiocytic reaction to wear debris with no evidence of acute inflammation.

**Patient 4.** Microbiology specimens at nail removal grew *Staphylococcus capitis*, however there was no clinical evidence of infection. Histology showed no evidence of acute infection.

**Patients 5 and 6.** No microbiology or histological findings.

**Plain radiograph imaging of retrieved nails.** Plain radiograph imaging of the retrieved nails did not reveal any apparent damage to their internal mechanism. Figure 4 presents an example of the images obtained for the tibial nails.

**Assessment of surface damage.** Table III presents a summary of the surface damage scores that were graded for each nail using macroscopic and microscopic analysis. Surface changes, where present, were predominately localized to around the screw holes on the nails and around the extendable junction (Figure 5). There was minimal surface damage found at other regions along the length of the nails, mainly presenting as light scratching and a discolouration of the surface.

Damage within the screw holes was predominately observed in holes 1 to 3 (as labelled in Figure 2) for the tibial nail patient (Patient 1) and one of the femoral

**Table II.** Summary of the blood metal ion values that were captured prior to nail removal for patients 1 to 4. Data for patients 5 and 6 are unavailable.

Patient no.	Ti, ppb	Co, ppb	Cr, ppb
1	0.14	0.59	1.66
2	0.24	0.59	1.56
3	N/A	0.59	6.14
4	0.77	N/A	0.68

N/A, not available.

nail patients (Patient 2); i.e. on the extending component of the nail. Patients 3 and 4 showed evidence of surface damage across all screw-nail holes in both nails, and Patient 3 had considerable surface damage at both extendable junctions. Patients 5 and 6 had evidence of surface damage at both the proximal and distal screw holes, as well as the extendable junction.

The main mechanism of damage in the holes and at the extendable junction appeared to be corrosion, with evidence of significant black surface deposits (Figures 6 and 7). Patients 1 and 2 had evidence of severe corrosion at the extendable junction of one nail while the other nail showed minimal unexpected surface damage (Figure 6).

**Corrosion scoring.** Table IV presents the corrosion scores graded for each nail. All nails showed evidence of corrosion to some extent. The grading showed a contrast in the evidence of severe corrosion at the

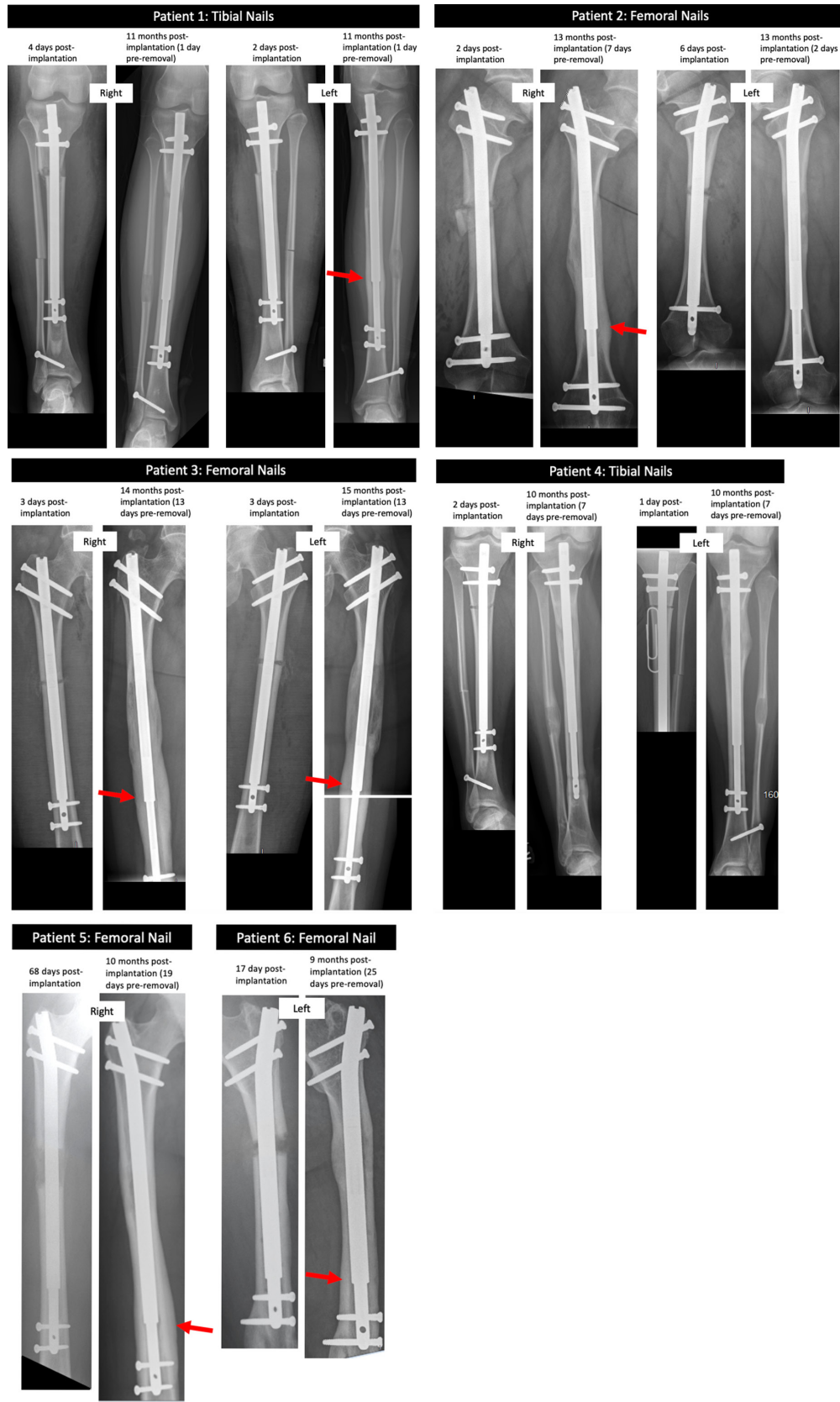


Fig. 3

Plain radiographs captured of each patient post-implantation of each nail, and pre-removal. Patients 1, 2, 3, 5, and 6 showed evidence of cortical thickening and osteolysis preremoval in bony regions aligned with the extendable junction of the nails (red arrows).

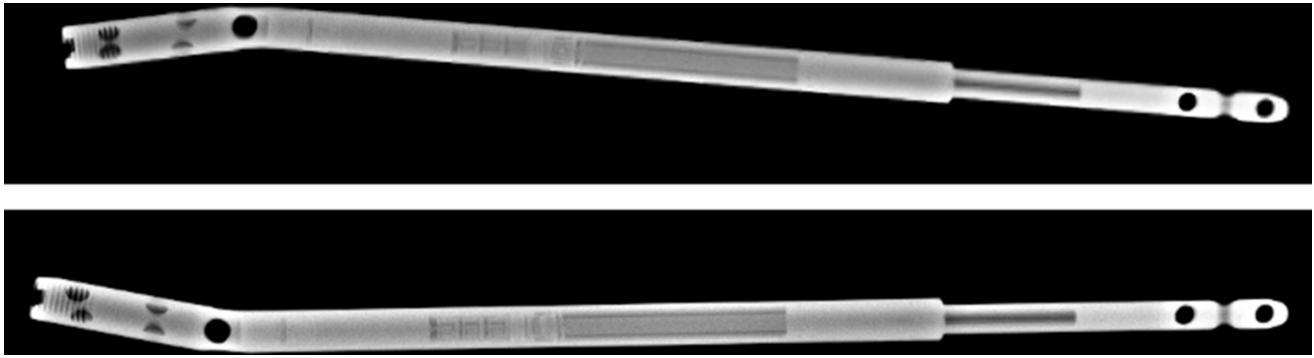


Fig. 4

Radiograph imaging did not reveal any apparent damage to the internal mechanism of the nails

**Table III.** Summary of the total surface damage grading scores that were obtained for each damage feature, for each nail, using a grading scale of 0 to 3. The sum of the scores for the different features is provided for each nail (total damage), graded out of a possible maximum score of 216.

Variable	Patient 1		Patient 2		Patient 3		Patient 4		Patient 5	Patient 6
	Left	Right	Left	Right	Left	Right	Left	Right	Right	Left
Scratching	2	5	1	6	4	1	6	3	5	3
Discolouration	6	5	13	14	13	14	9	8	8	4
Cracking	0	0	0	0	0	0	0	0	0	0
Galling	4	4	4	4	5	4	4	4	4	3
Pitting	0	0	0	0	0	0	0	0	0	0
Surface deposits	0	0	4	8	5	9	5	4	7	6
Total damage	12	14	22	32	27	28	24	19	24	16




Fig. 5

Macroscopic images of damage patterns localized to screw holes and the extendable junction of the nails. Example shown is of the left tibial nail retrieved from Patient 1 after 11 months in situ. This patient experienced severe pain in their left tibia and there was evidence of cortical thickening around the site of the junction.

extendable junction of one nail compared with mild to no corrosion in the opposite nail for both patients 1 and

2. Patient 3 was graded as having had severe corrosion around the extendable junction of both nails. Patient 4




Fig. 6

Microscopic images of the extendable junctions of the femoral nails retrieved from patient 2 after 13 months in situ. The left image is of the left nail, showing minimal unexpected surface damage. The right image is of the right nail, showing evidence of severe corrosion (Goldberg score 4). The left image also shows black marks and slight galling, corresponding to the incremental lengthening of the nails. The patient had no symptoms of pain; however, there was evidence of cortical thickening at the extendable junction of the right nail.

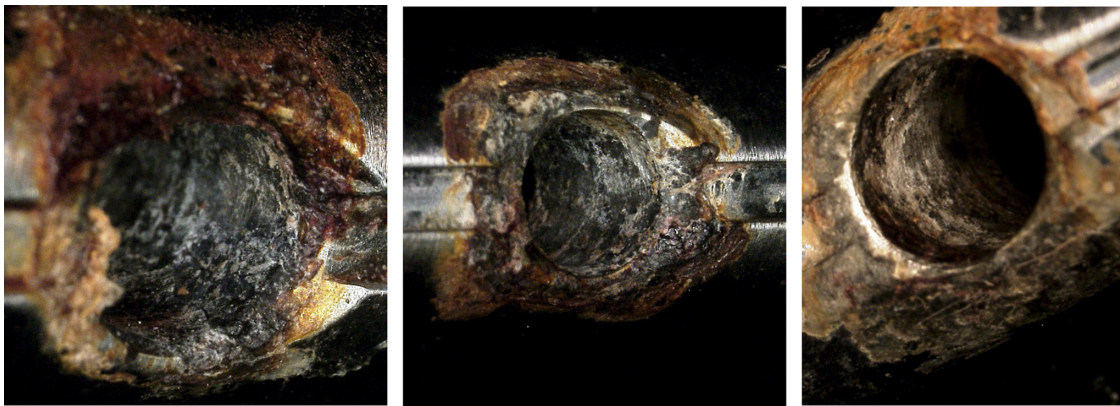


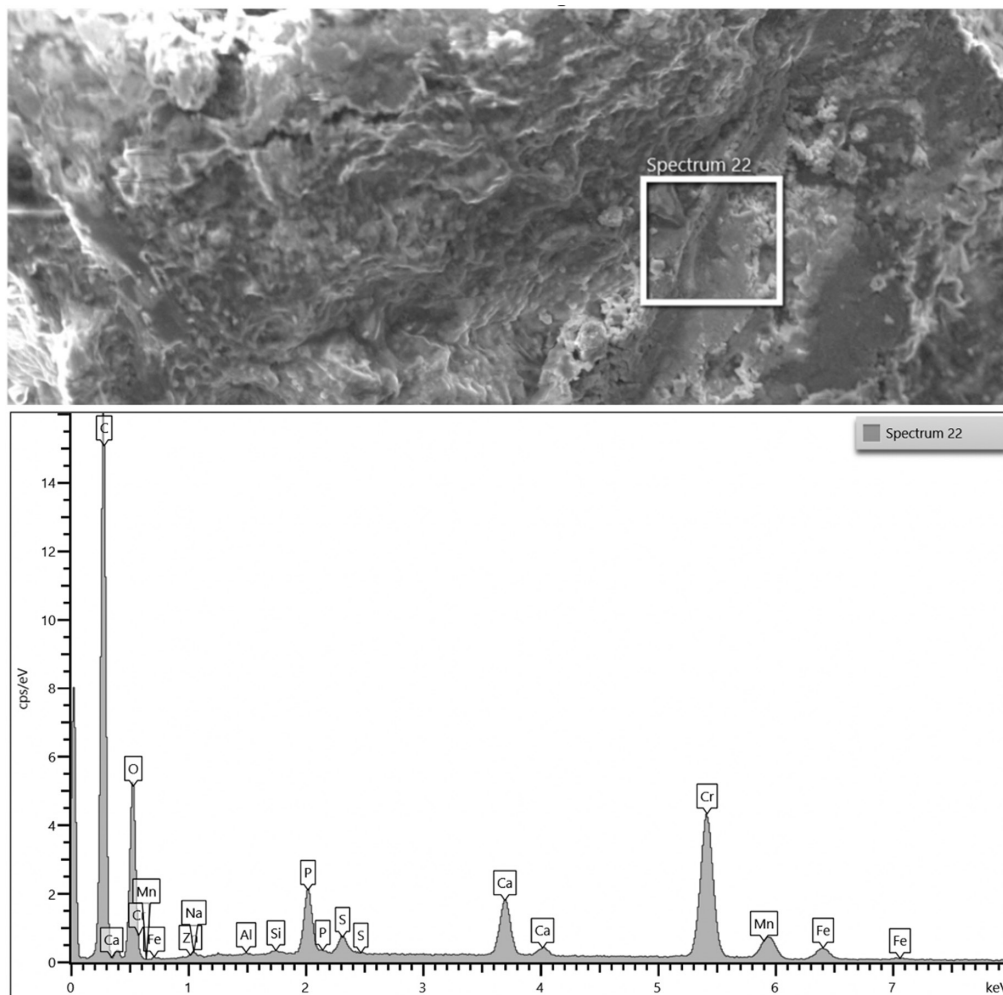
Fig. 7

Microscopic images showing evidence of severe corrosion (Goldberg score 4) within the nail-screw junction holes. This was observed in ten out of the 54 screw holes examined.

**Table IV.** Summary of the Goldberg corrosion scores for the nail-screw hole junctions and the extendable junction.

Patient	Hole 1	Hole 2	Hole 3	Extendable junction	Hole 4	Hole 5	Hole 6
<b>Patient 1</b>							
Left	2	1	4	4	1	1	1
Right	2	1	1	2	1	1	1
<b>Patient 2</b>							
Left	1	1	4	1	2	1	N/A
Right	4	1	2	4	1	1	N/A
<b>Patient 3</b>							
Left	3	1	3	4	4	2	N/A
Right	3	2	4	4	3	1	N/A
<b>Patient 4</b>							
Left	3	1	3	2	3	3	3
Right	1	1	2	1	4	2	1
<b>Patient 5</b>							
Right	3	1	3	4	4	4	N/A
<b>Patient 6</b>							
Left	3	1	4	3	4	1	N/A

N/A, not applicable.



**Fig. 8**

Elemental composition of black surface deposits present on the retrieved nails, as determined using energy dispersive x-ray spectroscopy analysis. The example shown here is of a spectrum from debris around the extendable junction of the left nail from Patient 3. There was evidence of chromium, phosphorous, sulphur, oxides, and chromium, along with the other constituent elements in this alloy.

had mild to no corrosion at the extendable junction and moderate to severe corrosion at the screw-nail holes. Patient 5 had severe corrosion at the extendable junction, while Patient 6 had moderate (Goldberg score 3) corrosion at this interface.

**EDS.** EDS analysis of the black surface deposits on the nails showed these to be rich in chromium, carbon, and oxygen. Figure 8 presents an example of the elemental composition that was determined during analysis.

**Metrology analysis.** Figure 9 presents the damage maps that were generated at the region of the extendable junction for each nail. These showed peaks of surface deposits up to 0.4 mm in height, which were localized adjacent to the point of contact between the extendable rod and the housing tube. Fewer surface deposits were detected as the scan lines emanated away from this junction. We found minimal evidence of mechanical damage in surface regions not impacted by corrosive mechanisms; the

linear depth of any deviations below the surface of the nail was less than 1.5  $\mu\text{m}$  in all cases.

**Comparison with clinical imaging.** Analysis of radiographs prior to nail removal showed evidence of cortical thickening and osteolysis in some cases, which was localized around the extendable junction. Patient 2 showed clear evidence of cortical thickening around their right nail (Figure 10), while this was not evident around their left nail (Figure 11). Comparison with retrieval findings showed that patients with cortical thickening around the extendable junction, also had severe corrosion (Goldberg score 4) around the junction; patients without cortical thickening had mild or no corrosion around this junction (Goldberg scores 1 to 2; (Figure 12)).

## Discussion

This study reports findings from the analysis of retrieved STRYDE nails. This provides useful information for the



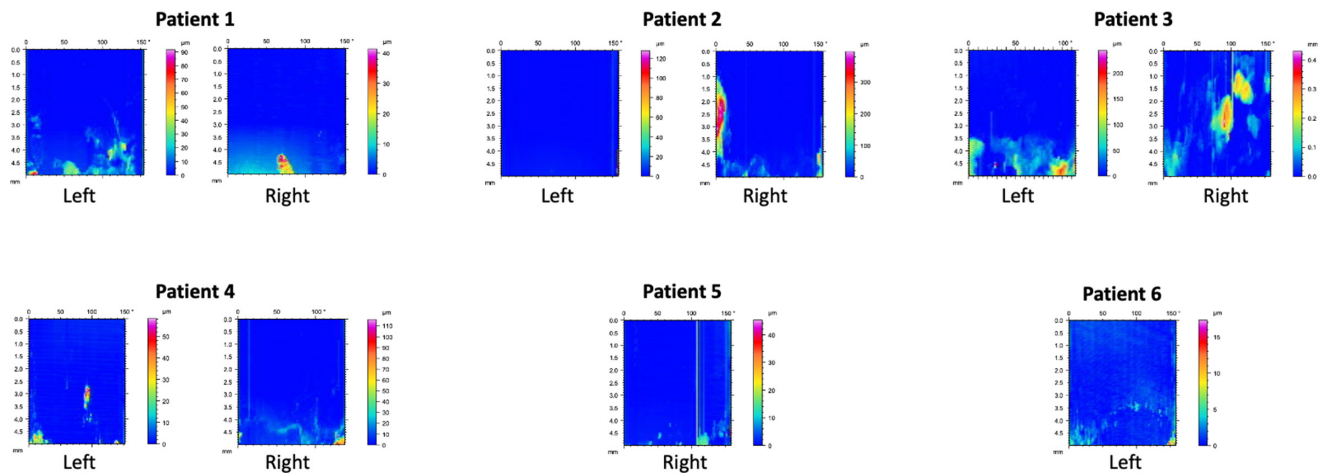


Fig. 9

Damage maps generated from line scans captured on each nail. The base of each map corresponds to the region adjacent to the point of contact between the housing tube and distraction rod.

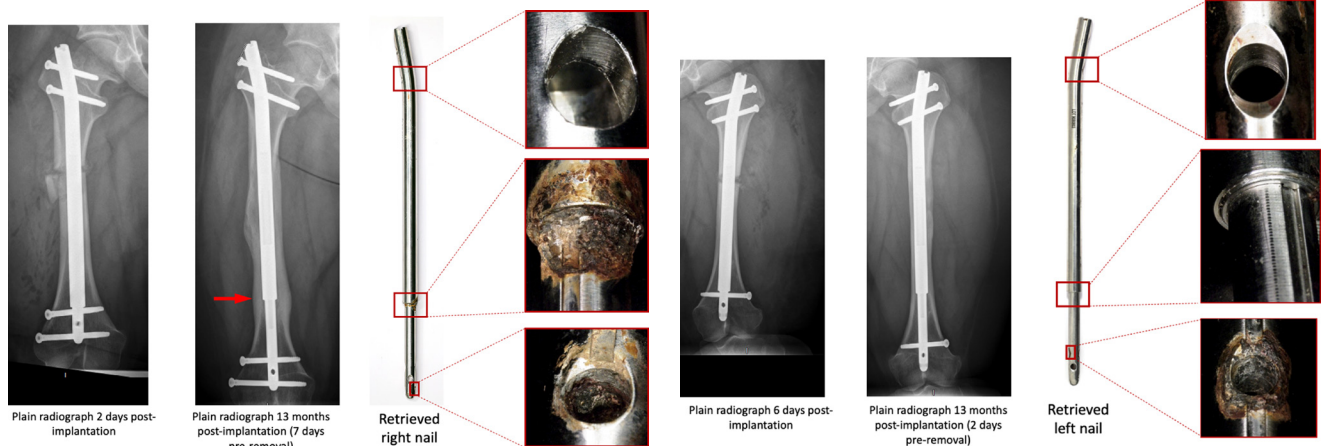


Fig. 10

Images showing immediate postimplantation and preremoval plain radiographs of Patient 2 implanted with a right femoral nail, removed after 13 months. There is evidence of clear cortical thickening around the extendable junction on the pre-removal radiograph (right arrow). This corresponds with retrieval evidence of severe corrosion at this junction, as well as at the most distal nail-screw junction.

Fig. 11

Images showing immediate postimplantation and preremoval plain radiographs of Patient 2 implanted with a left femoral nail, removed after 13 months. The cortical thickening observed around the right nail junction is not observed here. Retrieval analysis found no evidence of corrosion at the extendable junction of this left nail. However, there was severe corrosion within one of the distal nail-screw junctions.

ongoing post market surveillance of a recently introduced implant, which has been lacking for orthopaedic implants in general over the last century. This aids the surgeon, manufacturer, and regulator when deciding which implant to use for which patient.

Our key retrieval finding was the presence of corrosion localized to the extendable junction of the nails and the locking screw holes. The distal screw holes appeared to be more severely corroded than the proximal screw holes. Four nails had evidence of severe corrosion at the extendable junction while the remaining four nails had either mild or no corrosion at this junction. Plain radiograph imaging of patient femoral/tibial bones revealed unexpected cortical thickening and osteolysis in six bones, which was localized

around the extendable junctions of the nails. There was no evidence of cortical thickening at this region in the other four bones. Comparison with retrieval findings revealed that five of the bones with cortical thickening had been implanted with nails with severe corrosion at the extendable junction; the sixth bone with cortical thickening had a nail that was moderately corroded (Goldberg 3) at the junction. While this study is not powered to draw definitive conclusions, there does appear to be an association between the nail corrosion and the bony changes observed.

Our findings align with those recently reported by Rölfing et al,<sup>15</sup> who observed radiological changes in 21 out of 30 bone segments implanted with STRYDE nails, with evidence of osteolysis, periosteal reaction, and



We acknowledge the limitations of the study. As discussed previously, the number of nails investigated is low however early studies such as ours can help to provide important information in the wider management of these patients. Secondly, the use of radiograph imaging to assess the state of the internal mechanism of these nails is not fully validated and technical defects not visible on radiograph may still be present. All nails in this study were clinically functional in terms of their ability to lengthen, suggesting that the mechanism was intact, however future studies should consider sectioning the nails for more detailed investigation.

A recent study of 106 patients implanted with STRYDE nails reported good clinical outcomes, concluding that immediate full weight-bearing was safe and that there were no biocompatibility issues with the use of Biodur 108.<sup>11</sup> This contrasts with the evidence of bony changes reported in the current study and further points to the need for large-scale studies that are able to fully separate out the multiple factors involved in the performance of these nails.

This study reported clinical engineering findings in retrieved STRYDE nails. We found, in fully united bones, evidence of cortical thickening that appeared to be associated with corrosion at the extendable junction, and when corrosion was present, the cortical thickening was adjacent to this junction. Further work, with greater numbers of retrievals, is required to fully understand this apparent association between corrosion and bony changes, and the influencing surgeon, implant, and patient factors involved.



### Take home message

- All STRYDE nails in this study achieved their intended treatment aim.
- Evidence of cortical thickening and osteolysis adjacent to the extendable junction of the nail was unexpected and likely due to severe corrosion at this junction.

### Twitter

Follow H. Hothi @harryhothi

### References

- Ilizarov GA.** The tension-stress effect on the genesis and growth of tissues. Part I. The influence of stability of fixation and soft-tissue preservation. *Clin Orthop Relat Res.* 1989;238:249–281.
- Ilizarov GA.** The tension-stress effect on the genesis and growth of tissues: Part II. The influence of the rate and frequency of distraction. *Clin Orthop Relat Res.* 1989;239:263–285.
- Paley D.** Current techniques of limb lengthening. *J Pediatr Orthop.* 1988;8(1):73–92.
- Calder PR, Laubscher M, Goodier WD.** The role of the intramedullary implant in limb lengthening. *Injury.* 2017;48:S52–8.
- Calder PR, McKay JE, Timms AJ, Roskrow T, Fugazzotto S, Edel P, et al.** Femoral lengthening using the PRECICE intramedullary limb-lengthening system: Outcome comparison following antegrade and retrograde nails. *Bone Jt J.* 2019;101-B(9):1168–1176.
- Laubscher M, Mitchell C, Timms A, Goodier D, Calder P.** Outcomes following femoral lengthening: An initial comparison of the PRECICE intramedullary lengthening nail and the IRS external fixator monorail system. *Bone Joint J.* 2016;98-B(10):1382–1388.
- Iliadis AD, Palloni V, Wright J, Goodier D, Calder P.** Pediatric lower limb lengthening using the PRECICE nail: Our experience with 50 cases. *J Pediatr Orthop.* 2021;41(1):e44–e49.
- Rozbruch SR, Birch JG, Dahl MT, Herzenberg JE.** Motorized intramedullary nail for management of limb-length discrepancy and deformity. *J Am Acad Orthop Surg.* 2014;22(7):403–409.
- Shabtai L, Specht SC, Standard SC, Herzenberg JE.** Internal lengthening device for congenital femoral deficiency and fibular hemimelia. *Clin Orthop Relat Res.* 2014;472(12):3860–3868.
- No authors listed.** PRECICE System instructions for use. NuVasive. 2021. [https://atlasapi.nuvasive.com/public/ifu/documents/retrieve?get&pVersion=0046&contRep=ZNUVEP1&docId=0050568677011EDB9CDF0046DC5EA12A&compld=LC0046-AD\\_ENGLISH.pdf](https://atlasapi.nuvasive.com/public/ifu/documents/retrieve?get&pVersion=0046&contRep=ZNUVEP1&docId=0050568677011EDB9CDF0046DC5EA12A&compld=LC0046-AD_ENGLISH.pdf) (date last accessed 20 July 2021).
- Robbins C, Paley D.** Stryde Weight-bearing Internal Lengthening Nail. *Tech Orthop.* 2020;35(3):201–208.
- ASTM International.** F2229-21 Standard Specification for Wrought, Nitrogen Strengthened 23Manganese-21Chromium-1Molybdenum Low-Nickel Stainless Steel Alloy Bar and Wire for Surgical Implants (UNS S29108. West Conshohocken, PA: ASTM International. 2021.
- No authors listed.** Device recall and supply suspended to the UK: All PRECICE Systems by NuVasive Specialized Orthopedics Inc. Medicines and Healthcare products Regulatory Agency. 2021. <https://www.boa.ac.uk/uploads/assets/552dea10-c795-4c9f-b1a08177bf9151c1/NuVasive-MHRA-notice.pdf> (date last accessed 21 July 2021).
- Iliadis A, Wright J, Stoddart M, Goodier W, Calder P.** Early results from a single centre's experience with the STRYDE nail. *Bone Joint J.* 2021;103-B(6):1168–1172.
- Röfling JD, Kold S, Nygaard T, Mikuzis M, Brix M, Faergemann C.** Pain, osteolysis and periosteal reaction are associated with the STRYDE limb lengthening nail: a nationwide cross-sectional study. *Acta Orthop.* 2021.
- McKellop HA, Hart A, Park SH, Hothi H, Campbell P, Skinner JA.** A lexicon for wear of metal-on-metal hip prostheses. *J Orthop Res.* 2014;32(9):1221–1233.
- Goldberg JR, Gilbert JL, Jacobs JJ, Bauer TW, Paprosky W, Leurgans S.** A multicenter retrieval study of the taper interfaces of modular hip prostheses. *Clin Orthop Relat Res.* 2002;401:149–161.
- Hothi HS, Matthies AK, Berber R, Whittaker RK, Skinner JA, Hart AJ.** The reliability of a scoring system for corrosion and fretting, and its relationship to material loss of tapered, modular junctions of retrieved hip implants. *J Arthroplasty.* 2014;29(6):1313–1317.
- Thaller PH, Frankenberg F, Degen N, Soo C, Wolf F, Euler E.** Complications and effectiveness of intramedullary limb lengthening: A matched pair analysis of two different lengthening nails. *Strateg Trauma Limb Reconstr.* 2020;15(1):7–12.
- Panagiotopoulou VC, Davda K, Hothi HS, et al.** A retrieval analysis of the PRECICE intramedullary limb lengthening system. *Bone Joint Res.* 2018;7(7):476–484.
- Lehtovirta L, Reito A, Parkkinen J, Hothi H, Henckel J, Hart A, et al.** Analysis of bearing wear, whole blood and synovial fluid metal ion concentrations and histopathological findings in patients with failed ASR hip resurfacings. *BMC Musculoskelet Disord.* 2017;18(1):1–11.
- Berber R, Khoo M, Cook E, Guppy A, Hua J, Miles J.** Muscle atrophy and metal-on-metal hip implants. *Acta Orthopaedica.* 2015;86(3):351–357.
- Swiatkowska I, Mosselmans JFW, Geraki T, Wyles CC, Maleszewski JJ, Henckel J, et al.** Synchrotron analysis of human organ tissue exposed to implant material. *J Trace Elem Med Biol.* 2018;46(October 2017):128–137.

#### Author information:

- H. Hothi, BEng, MSc, PhD, Implant Science Fellow
- S. Bergiers, MEng, PhD, Research Fellow
- J. Henckel, MBBS, MRCS, PhD, Specialist Registrar
- W. D. Goodier, MBBS, FRCS (Orth), Consultant Orthopaedic Surgeon, Complex Trauma and Limb Reconstruction
- J. Skinner, MBBS, FRCS (Eng), FRCS (Orth), Consultant Orthopaedic Surgeon
- P. Calder, MBBS, FRCS (Orth), Consultant Paediatric Orthopaedic and Limb Reconstruction Surgeon
- A. J. Hart, FRCSG (Orth), MD, Professor of Orthopaedic Surgery The Royal National Orthopaedic Hospital, London, UK.
- A. D. Iliadis, MBBS, BSc, FRCS (Tr&Orth), Locum Consultant Orthopaedics and Limb Reconstruction, The Royal London Hospital, Barts Health NHS Trust, London, UK.
- J. Wright, MBBS (Hons), BSc, FRCS (Tr&Orth), Consultant Paediatric Orthopaedic and Limb Reconstruction Surgeon, The Royal National Orthopaedic Hospital, London, UK; The Royal London Hospital, Barts Health NHS Trust, London, UK.

#### Author contributions:

- H. Hothi: Methodology, Investigation, Formal analysis, Writing – original draft.
- S. Bergiers: Investigation, Formal analysis, Writing – original draft.
- J. Henckel: Methodology, Formal analysis, Writing – original draft.

- A. D. Iliadis: Methodology, Resources, Investigation, Formal analysis, Writing – original draft.
- W. D. Goodier: Methodology, Resources, Investigation, Formal analysis, Writing – original draft.
- J. Wright: Resources, Investigation, Formal analysis, Writing – original draft.
- J. Skinner: Methodology, Formal analysis, Writing – original draft.
- P. Calder: Methodology, Resources, Investigation, Formal analysis, Writing – original draft.
- A. J. Hart: Methodology, Formal analysis, Writing – original draft.

**Funding statement:**

- Although none of the authors has received or will receive benefits for personal or professional use from a commercial party related directly or indirectly to the subject of this article, benefits have been or will be received but will be directed solely to a research fund, foundation, educational institution, or other non-profit organization with which one or more of the authors are associated.

**ICMJE COI statement:**

- J. Skinner reports and institutional grant from NuVasive, unrelated to this study. P. Calder reports institutional payments for travel to meetings for from NuVasive,

related to this study. A. Hart reports an institutional grant and personal payments for consulting from NuVasive, related to this study.

**Acknowledgements:**

- We acknowledge the support of Edmond Kinene at the Royal National Orthopaedic Hospital in performing radiographic imaging analysis of the retrieved nails.

**Ethical review statement:**

- All patients provided informed consent for their implants and associated clinical data to be investigated at our implant centre. This research was approved by London-Riverside REC: Implant Study - 07/Q0401/25.

© 2021 Author(s) et al. This is an open-access article distributed under the terms of the Creative Commons Attribution Non-Commercial No Derivatives (CC BY-NC-ND 4.0) licence, which permits the copying and redistribution of the work only, and provided the original author and source are credited. See <https://creativecommons.org/licenses/by-nc-nd/4.0/>