



■ HIP

The effect of calcar femoral neck plating on vascularity of the femoral head and neck

**J. F. Kubik,
T. D. Bornes,
C. E. Klinger,
J. P. Dyke,
D. L. Helfet**

From Hospital for
Special Surgery, New
York, New York, USA

Aims

Surgical treatment of young femoral neck fractures often requires an open approach to achieve an anatomical reduction. The application of a calcar plate has recently been described to aid in femoral neck fracture reduction and to augment fixation. However, application of a plate may potentially compromise the regional vascularity of the femoral head and neck. The purpose of this study was to investigate the effect of calcar femoral neck plating on the vascularity of the femoral head and neck.

Methods

A Hueter approach and capsulotomy were performed bilaterally in six cadaveric hips. In the experimental group, a one-third tubular plate was secured to the inferomedial femoral neck at 6:00 on the clockface. The contralateral hip served as a control with surgical approach and capsulotomy without fixation. Pre- and post-contrast MRI was then performed to quantify signal intensity in the femoral head and neck. Qualitative assessment of the terminal arterial branches to the femoral head, specifically the inferior retinacular artery (IRA), was also performed.

Results

Quantitative MRI revealed a mean reduction of 1.8% (SD 3.1%) of arterial contribution in the femoral head and a mean reduction of 7.1% (SD 10.6%) in the femoral neck in the plating group compared to non-plated controls. Based on femoral head quadrant analysis, the largest mean decrease in arterial contribution was in the inferomedial quadrant (4.0%, SD 6.6%). No significant differences were found between control and experimental hips for any femoral neck or femoral head regions. The inferior retinaculum of Weitbrecht (containing the IRA) was directly visualized in six of 12 specimens. Qualitative MRI assessment confirmed IRA integrity in all specimens.

Conclusion

Calcar femoral neck plating at the 6:00 position on the clockface resulted in minimal decrease in femoral head and neck vascularity, and therefore it may be considered as an adjunct to laterally-based fixation for reduction and fixation of femoral neck fractures, especially in younger patients.

Cite this article: *Bone Jt Open* 2021;2-8:611–617.

Keywords: medial calcar plating, femoral neck plating, vascularity, quantitative MRI, femoral head, femoral neck

Introduction

The treatment of young femoral neck fractures remains a challenge given the high incidence complications that often require reoperation, specifically nonunion and avascular necrosis (AVN).¹ Quality of fracture reduction remains an important predictive factor in treatment success.^{1–3} Although certain fracture patterns are amenable to

closed reduction, others require an open approach to directly visualize and manipulate fracture fragments to achieve reduction. Moreover, an open approach allows application of a femoral neck plate which can aid in reduction and prove biomechanically advantageous to supplement lateral fixation.⁴ In particular, medial calcar plate fixation has recently been suggested to resist high shear

Correspondence should be sent to
David L Helfet; email:
helfetd@hss.edu

doi: 10.1302/2633-1462.28.BJO-
2021-0099.R1

Bone Jt Open 2021;2-8:611–617.

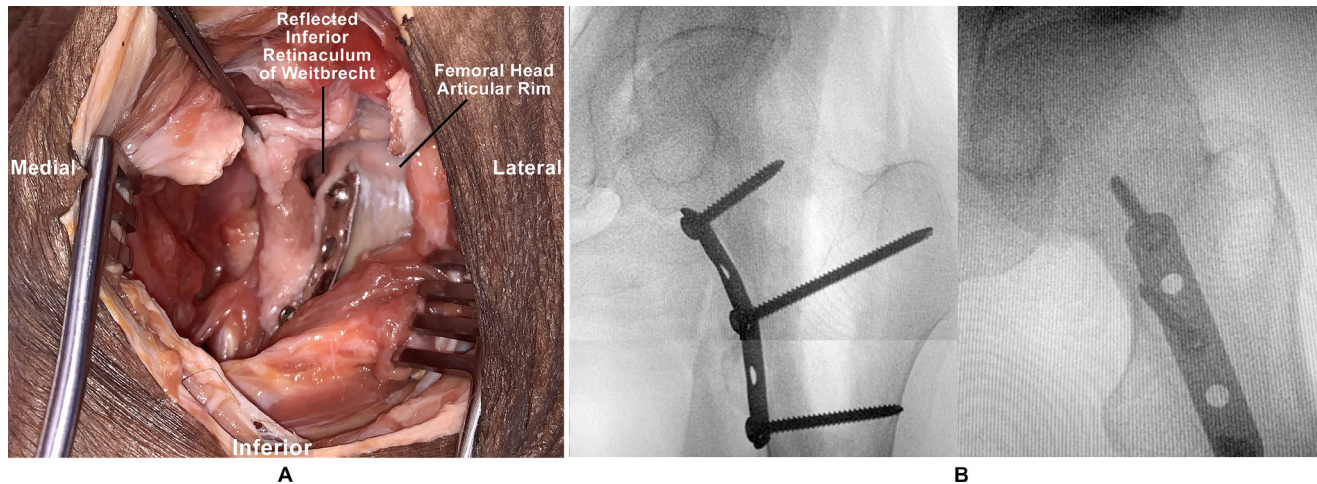


Fig. 1

a) Photograph of a cadaveric left hip following a Hueter approach, capsulotomy, and application of a one-third tubular plate at the 6:00 position on the clockface. b) Corresponding radiographs (AP, lateral) of left hip demonstrating plate positioning along the medial femoral neck calcar at 6:00 on the clockface.

forces through a buttress effect.⁵ The open treatment of femoral neck fractures, however, does not come without the potential risk of damaging the blood supply to the femoral head and neck.⁶⁻⁸

The medial femoral circumflex artery (MFCA) is the primary blood supply to the femoral head.^{7,9,10} Although the superior retinacular artery (SRA) of the MFCA appears to be the dominant vascular supply to the femoral head, its branches are often injured in the fracture setting as they are quite adherent to the femoral neck.¹¹ The inferior retinacular artery (IRA) of the MFCA however, is often preserved.¹¹ Moreover, the IRA has significant vascular contributions to the weight-bearing dome of the femoral head given the extensive intraosseous anastomoses between the superior and inferior systems.¹²⁻¹⁵ As such, the IRA requires particular attention when performing open reduction and internal fixation of the femoral neck.

A recent cadaveric study determined that the IRA courses along the femoral neck between the clockface positions of 7:00 and 8:00,⁸ allowing a theoretical safe-zone for calcar plate application at 6:00. However, it is unclear if an anterior approach, followed by capsular retraction and calcar plating of the femoral neck, compromises the vascularity of the femoral head and neck.¹⁶ Therefore, the purpose of this study was to investigate the effect of calcar femoral neck plating on the regional vascularity of the femoral head and neck.

Methods

Cadaver specimens. After institutional ethics approval, six human cadavers (fresh-frozen, pelvis to bilateral mid-femur) were used (Anatomy Gifts Registry, USA). There were three male and three female specimens (mean age 59.2 years (standard deviation (SD) 9.5; 41 to 68); average BMI 22.8 kg/m² (SD 9.1; 14.0 to 40.0)). Causes

of death were traumatic brain injury (n = 1), stroke (n = 1), leukaemia (n = 1), coronary artery disease (n = 1), drug overdose (n = 1), and complications of dementia (n = 1). No specimen had prior hip trauma nor surgical procedure.

Surgical technique. A Hueter approach¹⁷ with T-shaped capsulotomy along the intertrochanteric ridge was performed bilaterally. The visible terminal branches of the LFCA were ligated. To visualize the inferior femoral neck, the leg was slightly flexed, abducted, and externally rotated while a Hohmann retractor was placed along the inferior neck. Gentle superior retraction was provided with a right-angle retractor. In the experimental group, a five-hole 3.5 mm small fragment one-third tubular plate (DePuy Synthes, USA) was placed along the calcar at the 6:00 position on the clockface, where 12:00 is defined as the superior neck and 3:00 is defined as the anterior neck.⁷ It was secured with three screws placed from inferomedial to superolateral at the neck, intertrochanteric region, and proximal shaft (Figure 1). All implants were then removed to allow for optimal MRI analysis; the capsule was sutured, and a layered closure was performed. The contralateral hip served as a control with surgical approach, capsulotomy, and closure without fixation. The experimental and control limbs were randomly assigned for each cadaveric pair using a randomization computer program (Random Allocation Software, Iran).

Vascular injection. A secondary incision was made along the femoral triangle, and the MFCA was cannulated at its take-off level bilaterally. The LFCA was also cannulated, knowing that its perfusion would be limited by the ligation of visible terminal branches through the anterior hip approach. Following insertion, all vascular cannulae (model 30000; Medtronic, USA) were secured into place using silk sutures (Ethicon Black Braided; Johnson &

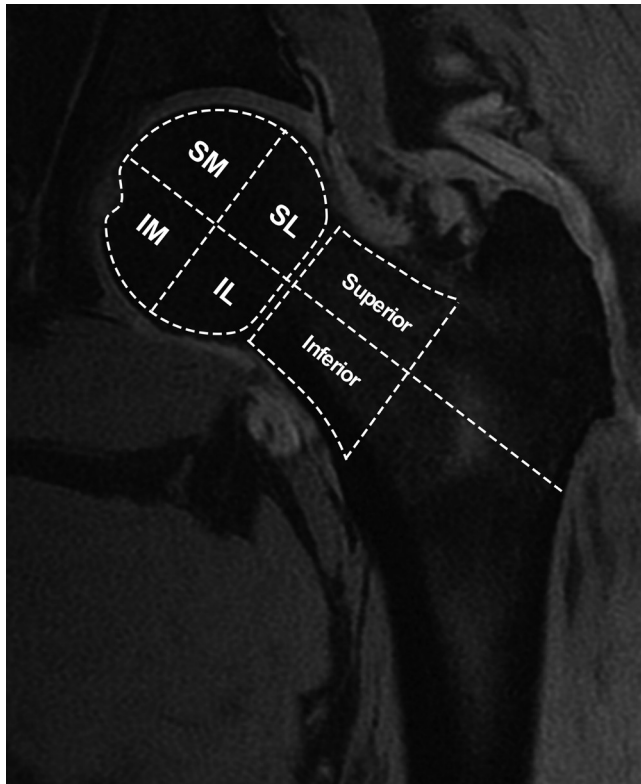


Fig. 2

Representative coronal MRI image of left hip demonstrating regions of interest for quantitative MRI analysis. Four regions in the femoral head (superomedial (SM), superolateral (SL), inferomedial (IM), and inferolateral (IL) quadrants) and two regions in the femoral neck (superior and inferior) were evaluated.

Johnson, USA). This vascular infusion protocol has been previously used to quantitatively assess the arterial contributions to the femoral head with contrast-enhanced MRI and CT.⁹

Quantitative MRI. A 3.0 T MRI was used with a quadrature knee coil (General Electric Healthcare, USA). Study specimens all underwent a quantitative MRI protocol (consisting of a 20 cm field of view, 512 × 384 matrix size, and 2 mm slice thickness), including pre- and post-manual injection of MRI contrast agent solution (Gadolinium-diethylenetriamine pentaacetic acid; Gd-DTPA at a 3:1 saline to Gd-DTPA ratio). A total of 15 ml of contrast solution was infused into the MFCA and 15 ml into the LFCA (total infusion volume of 30 ml) per hip. MRI imaging was reconstructed to a resolution of 0.4 × 0.4 × 1.0 mm. Acquisition parameters consisted of repetition and echo times of 18.6 and 5.3 ms, respectively, and a 35° flip angle.

A previously described and validated method was used for quantitative MRI analysis.^{9,12,14,18-23} Fat-suppressed MRI images were analyzed to reduce signal caused by bone marrow and to optimize Gd-DTPA detail. One study investigator (JPD) used previously designed custom software

based on IDL 6.4 (Exelis, USA) to analyze of specific intraosseous regions of interest (ROI) in the coronal plane of the proximal femur (Figure 2). The following ROIs were defined on multiple coronal MRI image slices: 1) superomedial femoral head; 2) superolateral femoral head; 3) inferomedial femoral head; 4) inferolateral femoral head; 5) superior femoral neck; and 6) inferior femoral neck. Numerous studies have been published using similar MRI methodology for quantitative vascular analysis for multiple anatomical intraosseous sites, including the femoral head and neck, proximal humerus, talus, patella, calcaneus, and distal femur.^{9,12,18-21,23-26}

Each ROI was assessed for signal intensity changes pre- and post-gadolinium injection for all MRI slices. These were also compared to the corresponding contralateral control hip to determine signal intensity changes within the same ROI for each MRI slice. Signal measurements were normalized with a baseline of non-enhancing muscle tissue proximal to the hip joint. Altogether, this yielded a weighted average (per voxel) of signal intensity measurements from both pre- and post-contrast MRI for each ROI in both control and experimental hips.

Statistical analysis. Statistical analysis was performed using SPSS software (version 1.0.0.1461; IBM, USA). As the data were not normally distributed with the Shapiro-Wilk test, Mann-Whitney U tests were used to compare quantitative MRI findings between groups, and p-value < 0.05 was considered statistically significant. The decrease in perfusion of the regions of the femoral head and femoral neck was reported as the mean and SD.

Results

Quantitative MRI revealed a mean reduction of 1.8% (SD 3.1%) of arterial contribution in the femoral head and a mean reduction of 7.1% (SD 10.6%) in the femoral neck in the femoral neck plating group compared to non-plated controls (Table I and Figure 3). The vascularity of the inferomedial quadrant of the femoral head trended towards being more affected than any other femoral head quadrant (mean reduction of 4.0% in arterial contribution as compared to the control limb; SD 6.6%) followed by the superomedial quadrant (2.7% reduction in arterial contribution as compared to the control limb (SD 6.7%)), while minimal reduction was observed in the other femoral head regions. No significant differences were found between control and experimental hips for each region of the femoral head and neck based on the Mann-Whitney U tests. However, a post-hoc power analysis revealed the study was underpowered.

On cadaveric dissection, the inferior retinaculum of Weitbrecht (IRW), which contains the IRA, was directly visualized in six of 12 hips (50%) in its inferiorly-based prolongation of the capsular wall. On qualitative MRI assessment, the IRA was identified and preserved in all 12 hips (100%).

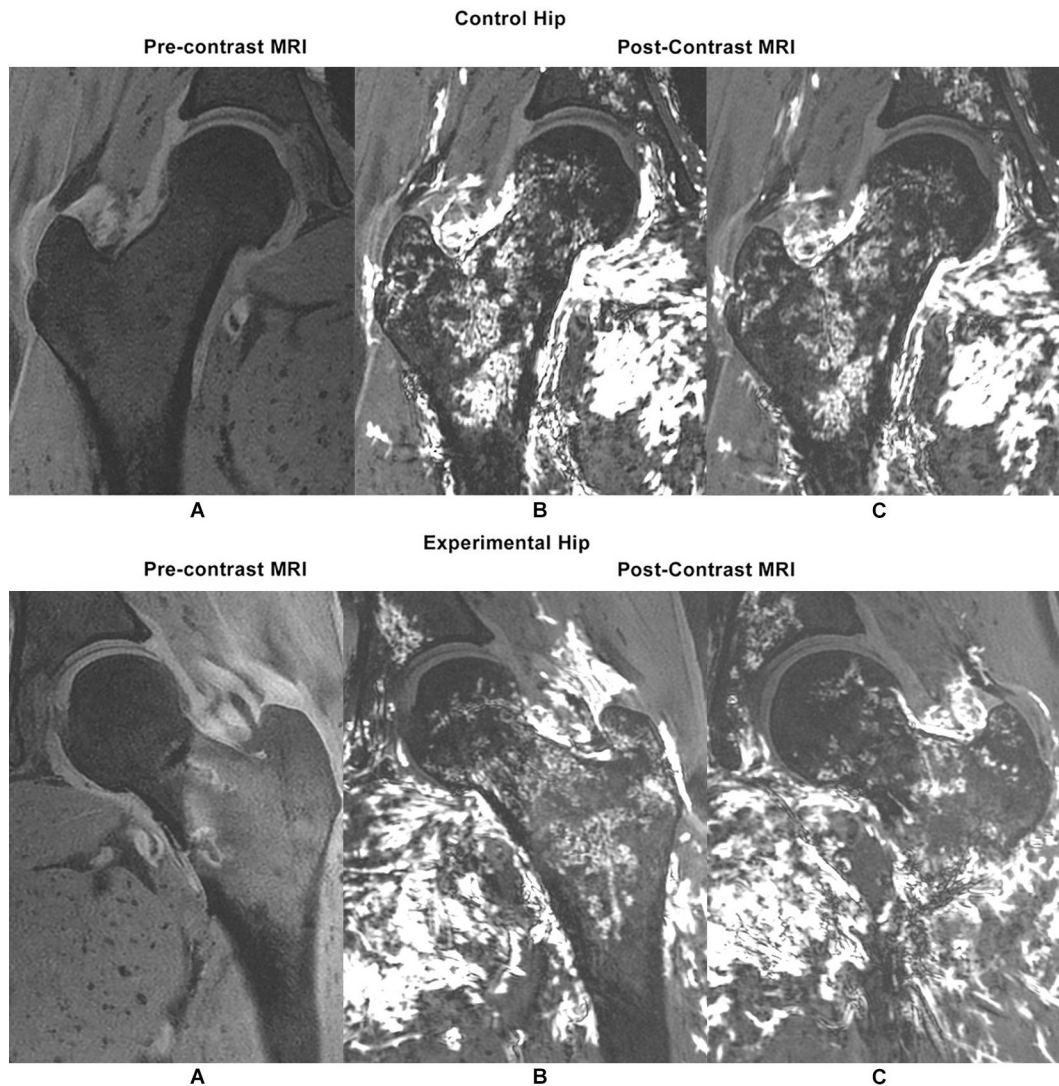


Fig. 3

Representative pre- and post-contrast coronal MRI images of a) control hip, and b) contralateral experimental hip following application of a five-hole one-third tubular plate 6:00 position on the clockface. The arterial contributions to the femoral head and neck, including both inferior and superior retinacular arterial systems, are preserved in the experimental hip.

Discussion

The results of this study demonstrate that calcar femoral neck plate application at the clockface position of 6:00 through a Hueter approach resulted in a mean reduction of 1.8% of arterial contribution in the femoral head and mean reduction of 7.1% in the femoral neck compared to contralateral femora treated with surgical exposure alone without plating. Therefore, femoral neck plating appears to minimally affect the vascularity to the femoral head and neck.

Surgical treatment of young femoral neck fractures remains challenging with severe complications. Anatomical femoral neck reduction is crucial to promote fracture union through primary bone healing given the presence of synovial fluid and lack of cambium periosteal layer in the femoral neck region.²⁷ Stable fixation is also

Table I. Quantitative MRI results; additional arterial contribution in control versus experimental.

Region	Mean (SD)†	p-value*
Femoral head - full	1.8 (3.1)	0.818
Femoral neck - full	7.1 (10.6)	0.699
Femoral head - superomedial	2.7 (6.7)	0.937
Femoral head - inferomedial	4.0 (6.6)	0.818
Femoral head - inferolateral	0.0 (0.0)	1.000
Femoral head - superolateral	0.4 (0.9)	0.937
Femoral neck - superior	9.0 (14.9)	0.937
Femoral neck - inferior	5.2 (6.3)	0.818

*Mann-Whitney U test; significance set at $p < 0.05$.

†Mean regional decreases in quantitative MRI signal enhancement of plated femoral necks compared to non-plated controls.

mandatory, although there is no consensus regarding the optimal fixation construct for these injuries. The

vertically-oriented, high energy, Pauwels type-3 femoral neck fracture requires particular attention given its higher rate of varus collapse and nonunion.³ Although no absolute indications exist for femoral neck calcar plating, it may prove beneficial in these fracture patterns to mitigate high shear forces and promote higher union rates.⁵

Recent biomechanical data have demonstrated that addition of a calcar plate to laterally-based fixation can increase failure loads by 83%⁴ and decrease the rate of significant fracture displacement.²⁸ In a clinical study involving 28 young adults with vertical femoral neck fractures who underwent calcar buttress plating to augment lateral cannulated screw fixation, uncomplicated union was found in 25 patients (89.3%) at one year.¹⁶ There were three cases of nonunion and no cases of AVN. A similar construct was used in a retrospective study of 23 patients.²⁹ There were two cases of early fixation failure but no cases of nonunion or AVN at 20 months follow-up. Further research is required to determine the optimal indications for supplementing laterally-based fixation with calcar femoral neck plating.

Despite early favourable clinical results, several inherent concerns exist regarding the application of a calcar plate for femoral neck fracture. First, it requires an open approach, which has recently been associated with a greater risk of reoperation compared to closed reduction methods.⁶ It is often the case, however, that a displaced femoral neck fracture in a young adult necessitates an open approach to achieve an anatomical reduction. Second, application of the plate can be technically challenging in the setting of a tenuous reduction as it requires “figure 4” leg positioning. Provisional or definitive laterally-based fixation across the fracture can increase fracture stability to permit this leg positioning for calcar plating. Finally, there has been concern that an open approach followed by medial plate fixation compromises the vascularity to the femoral head and neck.⁶

The vascular contributions to the femoral head and neck region have been well studied. The MFCA supplies 82% of the femoral head and 67% of the femoral neck.⁹ Although the extraosseous anastomoses between the MFCA and inferior gluteal artery are well described,³⁰⁻³² there also exists an extensive intraosseous anastomoses between the terminal branches of the MFCA within the femoral head.¹² As such, although the SRA of the MFCA has conventionally been considered as the primary blood supply to the femoral head,^{30,32} the IRA maintains significant vascular contributions to the entire femoral head, including the weightbearing dome, as well.¹²⁻¹⁵ This is particularly important in the setting of a femoral neck fracture as the SRA is often compromised due to its adherence to the superior femoral neck, whereas the IRA is often preserved¹³ as it lies within the IRW (an extrape-riosteal infolding of synovial tissue) that is elevated off the bony surface of the femoral neck.¹³ Knowledge of the

course of the IRA is therefore critical when performing open femoral neck reduction and fixation to avoid further damage to femoral head vascularity.

The IRA branches off the transverse MFCA inferomedially 4 cm from the lesser trochanter and travels 1 cm to then penetrate the capsule at the anterior-inferior neck. It then courses in a posterior-oblique direction within the IRW for 2.4 cm along the inferior femoral neck to then penetrate the head-neck junction to become intraosseous.¹⁰ Relative to the clockface, one study of 14 cadavers with posteriorly-based hip approaches found the IRA inserted into the capsule at the anterior-inferior neck at a mean at 5:54.⁷ Following its posterior-oblique trajectory along the neck, its intraosseous penetration of five terminal branches 4 mm from the articular head-neck junction were found at a mean of 6:45 (4:50 to 8:10). A more recent study⁸ of 30 cadaveric specimens in which anteriorly-based hip approaches were used identified the intracapsular IRA position as slightly more posterior, between the 7:00 and 8:00 positions, but the authors did not report the IRA trajectory. They did highlight, however, that the lesser trochanter can be a useful landmark as it was found approximately 0:30 posterior to the position of the IRA. The slight discrepancy in IRA location between these anatomical studies may be due to the different approaches used, but nonetheless, the IRA seems to course between the 6:00 and 8:00 on the clockface.

Although the IRA was not directly isolated in the current study, it was visualized in half of our specimens at approximately the 6:00 to 7:00 position in the central neck, protected within the IRW. Of note, however, MRI analysis confirmed the presence and integrity of the IRA (within the IRW) in all specimens. As such, the surgeon must recognize that although direct visualization of the vessel is not always feasible, care should be taken to avoid its damage as it is consistently located along the posteroinferior neck. This is possible through hip external rotation, abduction and flexion as the capsule (and thus the IRA) falls away from the femoral neck. The IRA can be further protected by placing a Hohmann retractor on the inferior femoral neck and retracting the capsule and IRW inferiorly. This permits safe application of a femoral neck calcar plate at the 6:00 as it preserves the IRA and the arterial supply to the femoral head (Figure 4). Early clinical studies of femoral neck plating at 6:00 for young femoral neck fracture confirm this finding as no cases of AVN were found.^{16,29}

This study is limited primarily due to its cadaveric design. The model used here does not replicate soft tissue damage associated with femoral neck fracture and will inherently overestimate perfusion. Nonetheless, a robust quantitative MRI protocol was used to address the research question. Plate removal, to facilitate optimal MRI detail, is another important limitation. The

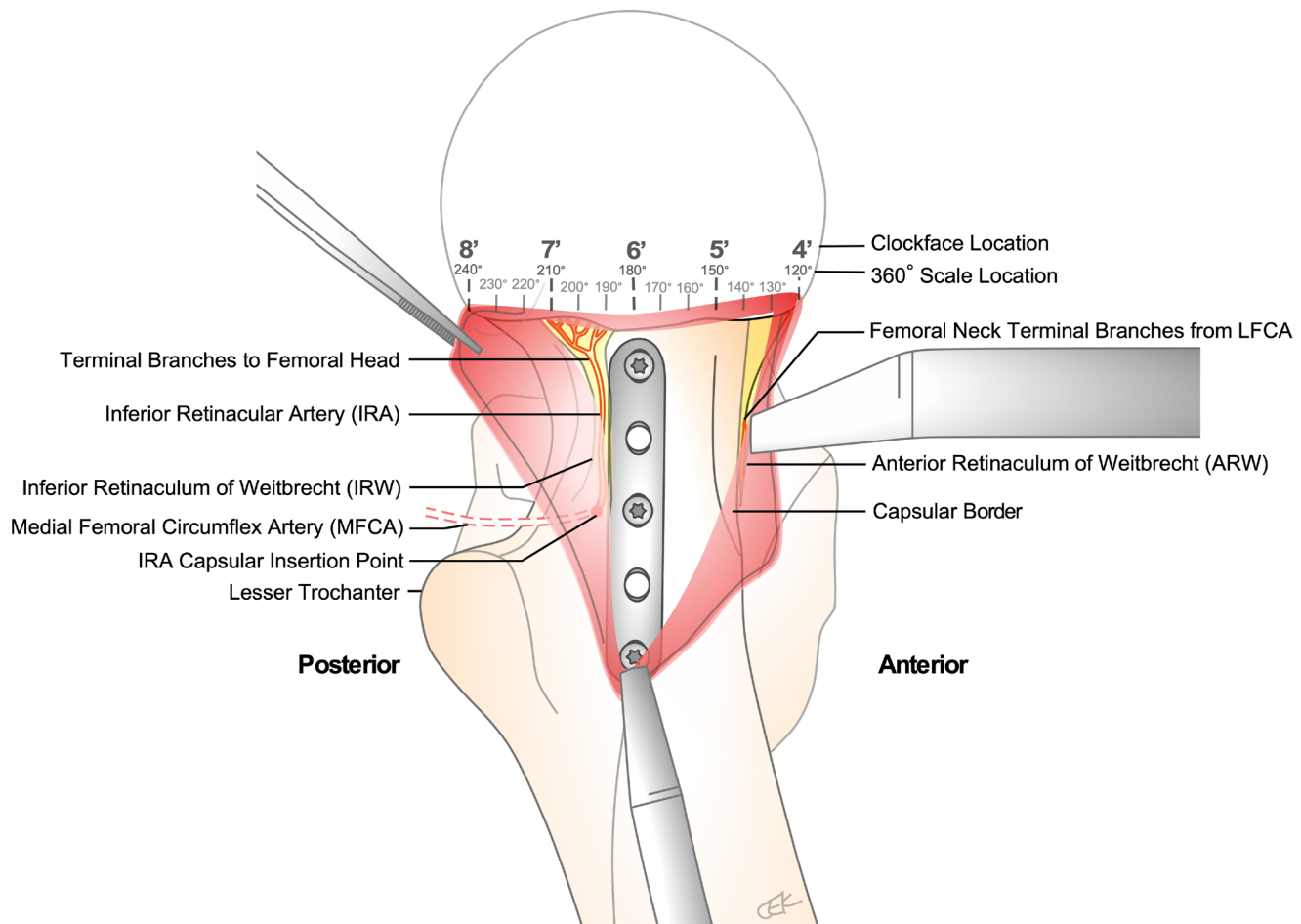


Fig. 4

Schematic of left femoral neck calcar following a Hueter approach, capsulotomy, and application of a one-third tubular plate at the 6:00 position on the clockface, where 12:00 is defined as the superior neck and 3:00 is defined as the anterior neck. The inferior retinacular artery (IRA), a terminal branch of the MFCA, courses along the posteroinferior neck within the inferior retinaculum of Weitbrecht (IRW). It is critical to preserve the IRA, and its vascular supply to the femoral head, while securing a buttress plate along the femoral neck calcar at 6:00. This is done through elevation of the inferior capsule and IRW off bone, placement of a Hohmann retractor along the inferior femoral neck, and hip external rotation with slight flexion.

plate was applied directly to bone in all specimens, and if any tissue was interposed (i.e. IRA), there would only be transient compression of the vessel as the plate was removed. In the clinical setting, however, the plate would be left in-situ and may have a more significant effect on vascularity. There was no lateral fixation applied in the current study, although early clinical studies examining outcomes of calcar plating with lateral constructs have found no detrimental effects to the femoral head blood supply. Finally, the study involved only six cadaver specimens and was underpowered as per a post-hoc analysis. Although young femoral neck fractures remain a relatively rare injury, current multicentre studies⁶ will shed valuable clinical information on the effectiveness and safety of femoral neck calcar plating.

The application of a femoral neck calcar plate at the 6:00 clockface position resulted in a mean reduction of 1.8% of arterial contribution to the femoral head and a mean reduction of 7.1% in the femoral neck compared

to contralateral surgical exposure alone without plating. Therefore, during open reduction and fixation of displaced femoral neck fractures through an anterior approach in young patients, supplemental medial calcar plating may be considered to increase laterally-based construct stability in vertically-oriented or high energy fracture patterns. Careful dissection of the inferior femoral neck should be performed to preserve the IRA by elevating the capsule off bone, regardless of its direct visualization. Further clinical research is required to confirm that the application of a medial femoral neck plate does not lead to increased risk of nonunion or AVN.



Take home message

- Application of a plate along the femoral neck calcar resulted in minimal decrease in vascularity to the femoral head and neck.

References

1. Slobogean GP, Sprague SA, Scott T, McKee M, Bhandari M. Management of young femoral neck fractures: is there a consensus. *Injury*. 2015;46(3):435–440.

2. Haidukewych GJ, Rothwell WS, Jacofsky DJ, Torchia ME, Berry DJ. Operative treatment of femoral neck fractures in patients between the ages of fifteen and fifty years. *J Bone Joint Surg Am.* 2004;86-A(8):1711–1716.
3. Liporace F, Gaines R, Collinge C, Haidukewych GJ. Results of internal fixation of Pauwels type-3 vertical femoral neck fractures. *J Bone Joint Surg Am.* 2008;90-A(8):1654–1659.
4. Kunapuli SC, Schramski MJ, Lee AS, et al. Biomechanical analysis of augmented plate fixation for the treatment of vertical shear femoral neck fractures. *J Orthop Trauma.* 2015;29(3):144–150.
5. Mir H, Collinge C. Application of a medial buttress plate may prevent many treatment failures seen after fixation of vertical femoral neck fractures in young adults. *Med Hypotheses.* 2015;84(5):429–433.
6. Patterson JT, Ishii K, Tornetta P, et al. Open reduction is associated with greater hazard of early reoperation after internal fixation of displaced femoral neck fractures in adults. *J Orthop Trauma.* 2020;34(6):294–301.
7. Lazaro LE, Klinger CE, Sculco PK, Helfet DL, Lorich DG. The terminal branches of the medial femoral circumflex artery: the arterial supply of the femoral head. *Bone Joint J.* 2015;97-B(9):1204–1213.
8. Putnam SM, Collinge CA, Gardner MJ, Ricci WM, McAndrew CM. Vascular anatomy of the medial femoral neck and implications for surface plate fixation. *J Orthop Trauma.* 2019;33(3):111–115.
9. Dewar DC, Lazaro LE, Klinger CE, et al. The relative contribution of the medial and lateral femoral circumflex arteries to the vascularity of the head and neck of the femur. *Bone Joint J.* 2016;98-B(12):1582–1588.
10. Gadinsky NE, Klinger CE, Sculco PK, et al. Femoral head vascularity: implications following trauma and surgery about the hip. *Orthopedics.* 2019;42(5):250–257.
11. Papadakis SA, Segos D, Kouvaras I, et al. Integrity of posterior retinaculum after displaced femoral neck fractures. *Injury.* 2009;40(3):277–279.
12. Boraiah S, Dyke JP, Hettrich C, et al. Assessment of vascularity of the femoral head using gadolinium (Gd-DTPA)-enhanced magnetic resonance imaging: a cadaver study. *J Bone Joint Surg Br.* 2009;91-B(1):131–137.
13. Lazaro LE, Dyke JP, Thacher RR, et al. Focal osteonecrosis in the femoral head following stable anatomic fixation of displaced femoral neck fractures. *Arch Orthop Trauma Surg.* 2017;137(11):1529–1538.
14. Lazaro LE, Sculco PK, Pardee NC, et al. Assessment of femoral head and head-neck junction perfusion following surgical hip dislocation using gadolinium-enhanced magnetic resonance imaging. *J Bone Joint Surg Am.* 2013;95-A(23):e1821:e1822.
15. Zhao D, Qiu X, Wang B, et al. Epiphyseal arterial network and inferior retinacular artery seem critical to femoral head perfusion in adults with femoral neck fractures. *Clin Orthop Relat Res.* 2017;475(8):2011–2023.
16. Ye Y, Chen K, Tian K, et al. Medial buttress plate augmentation of cannulated screw fixation in vertically unstable femoral neck fractures: Surgical technique and preliminary results. *Injury.* 2017;48(10):2189–2193.
17. Rachbauer F, Kain MS, Leunig M. The history of the anterior approach to the hip. *Orthop Clin North Am.* 2009;40(3):311–320.
18. Donders JCE, Klinger CE, Shaffer AD, et al. Quantitative and qualitative assessment of the relative arterial contributions to the calcaneus. *Foot Ankle Int.* 2018;39(5):604–612.
19. Hettrich CM, Boraiah S, Dyke JP, et al. Quantitative assessment of the vascularity of the proximal part of the humerus. *J Bone Joint Surg Am.* 2010;92-A(4):943–948.
20. Miller AN, Prasarn ML, Dyke JP, Helfet DL, Lorich DG. Quantitative assessment of the vascularity of the talus with gadolinium-enhanced magnetic resonance imaging. *J Bone Joint Surg Am.* 2011;93-A(12):1116–1121.
21. Rollick NC, Gadinsky NE, Klinger CE, et al. The effects of dual plating on the vascularity of the distal femur. *Bone Joint J.* 2020;102-B(4):530–538.
22. Schottel PC, Hinds RM, Lazaro LE, et al. The effect of antegrade femoral nailing on femoral head perfusion: a comparison of piriformis fossa and trochanteric entry points. *Arch Orthop Trauma Surg.* 2015;135(4):473–480.
23. Sculco PK, Lazaro LE, EP S, et al. A vessel-preserving surgical hip dislocation through a modified posterior approach: assessment of femoral head vascularity using gadolinium-enhanced MRI. *J Bone Joint Surg Am.* 2016;98-A(6):475–483.
24. Lazaro LE, Nawabi DH, Klinger CE, et al. Quantitative assessment of femoral head perfusion following arthroscopic femoral osteochondroplasty: a cadaveric study. *J Bone Joint Surg Am.* 2017;99-A(24):2094–2102.
25. Jones KJ, Lazaro LE, Taylor SA, et al. Quantitative assessment of patellar vascularity following bone-patellar tendon-bone autograft harvest for ACL reconstruction. *Knee Surg Sports Traumatol Arthrosc.* 2015;24(9):2818–2824.
26. Lazaro LE, Wellman DS, Klinger CE, et al. Quantitative and qualitative assessment of bone perfusion and arterial contributions in a patellar fracture model using gadolinium-enhanced magnetic resonance imaging. *J Bone Joint Surg Am.* 2013;95-A(19):e1401:e140.
27. Allen MR, Burr DB. Human femoral neck has less cellular periosteum, and more mineralized periosteum, than femoral diaphyseal bone. *Bone.* 2005;36(2):311–316.
28. Tianye L, Peng Y, Jingli X, et al. Finite element analysis of different internal fixation methods for the treatment of Pauwels type III femoral neck fracture. *Biomed Pharmacother.* 2019;112:108658.
29. Liu JF, Zhang SD, Huang L, et al. Dynamic limited axial compression yields favorable functional outcomes in the fixation of Pauwels type-3 femoral neck fractures: A retrospective cohort study. *Injury.* 2020;51(8):1851–1857.
30. Gautier E, Ganz K, Krügel N, Gill T, Ganz R. Anatomy of the medial femoral circumflex artery and its surgical implications. *J Bone Joint Surg Br.* 2000;82-B(5):679–683.
31. Grose AW, Gardner MJ, Sussmann PS, Helfet DL, Lorich DG. The surgical anatomy of the blood supply to the femoral head: description of the anastomosis between the medial femoral circumflex and inferior gluteal arteries at the hip. *J Bone Joint Surg Br.* 2008;90-B(10):1298–1303.
32. Kalhor M, Beck M, Huff TW, Ganz R. Capsular and pericapsular contributions to acetabular and femoral head perfusion. *J Bone Joint Surg Am.* 2009;91-A(2):409–418.

Author information:

- J. F. Kubik, MD, FRCSC, Clinical Fellow
- T. D. Bornes, MD, PhD, FRCSC, Clinical Fellow
- C. E. Klinger, BA, Research Coordinator
- D. L. Helfet, MD, Chief Emeritus Orthopaedic Trauma Service, Hospital for Special Surgery, New York Presbyterian Hospital, Weill Cornell Medicine, New York, New York, USA.
- J. P. Dyke, PhD, Associate Professor of Physics Research in Radiology, Citigroup Biomedical Imaging Center and Weill Medical College of Cornell University, New York, New York, USA.

Author contributions:

- J. F. Kubik: Designed the study, Carried out laboratory dissection, data, and MRI acquisition, Analyzed the statistics, Prepared and revised the manuscript.
- T. D. Bornes: Involved in the study design, Carried out laboratory dissection, data, and MRI acquisition, Analyzed the statistics, Prepared and revised the manuscript.
- C. E. Klinger: Involved in the study design, Carried out laboratory dissection, data, and MRI acquisition, Analyzed the MI-ROI and statistics, Prepared and revised the manuscript.
- J. P. Dyke: Involved in the study design, Carried out laboratory dissection, data, and MRI acquisition, Analyzed the MI-ROI and statistics, Prepared and revised the manuscript.
- D. L. Helfet: Involved in the study design, Oversaw the project, Prepared and revised the manuscript.

Funding statement:

- No benefits in any form have been received or will be received from a commercial party related directly or indirectly to the subject of this article.

Open access funding:

- This study was funded through internal departmental funding from of the Orthopaedic Trauma Service of the author's institution.

Acknowledgements:

- The authors gratefully acknowledge the expert assistance of Justin Dufresne and Yael Garcia at the Hospital for Special Surgery Simulation Learning and Training Center (SLTC) during the course of this research investigation.

Ethical review statement:

- This study was approved by our Institutional Review Board (IRB# 2019-1982).

© 2021 Author(s) et al. This is an open-access article distributed under the terms of the Creative Commons Attribution Non-Commercial No Derivatives (CC BY-NC-ND 4.0) licence, which permits the copying and redistribution of the work only, and provided the original author and source are credited. See <https://creativecommons.org/licenses/by-nc-nd/4.0/>