



■ KNEE

Varus-valgus constrained insert with posterior-stabilized femoral components in complex primary total knee arthroplasties

**A. K. Limberg,
C. C. Wyles,
M. J. Taunton,
A. D. Hanssen,
M. W. Pagnano,
M. P. Abdel**

From Mayo Clinic,
Rochester, Minnesota,
USA

Aims

Varus-valgus constrained (VVC) devices are typically used in revision settings, often with stems to mitigate the risk of aseptic loosening. However, in at least one system, the VVC insert is compatible with the primary posterior-stabilized (PS) femoral component, which may be an option in complex primary situations. We sought to determine the implant survivorship, radiological and clinical outcomes, and complications when this VVC insert was coupled with a PS femur without stems in complex primary total knee arthroplasties (TKAs).

Methods

Through our institution's total joint registry, we identified 113 primary TKAs (103 patients) performed between 2007 and 2017 in which a VVC insert was coupled with a standard cemented PS femur without stems. Mean age was 68 years (SD 10), mean BMI was 32 kg/m² (SD 7), and 59 patients (50%) were male. Mean follow-up was four years (2 to 10).

Results

The five-year survivorship free from aseptic loosening was 100%. The five-year survivorship free from any revision was 99%, with the only revision performed for infection. The five-year survivorship free from reoperation was 93%. The most common reoperation was treatment for infection (n = 4; 4%), followed by manipulation under anaesthesia (MUA; n = 2; 2%). Survivorship free from any complication at five years was 90%, with superficial wound infection as the most frequent (n = 4; 4%). At most recent follow-up, two TKAs had non-progressive radiolucent lines about both the tibial and femoral components. Knee Society Scores improved from 53 preoperatively to 88 at latest follow-up (p < 0.001).

Conclusion

For complex primary TKA in occasional situations, coupling a VVC insert with a standard PS femur without stems proved reliable and durable at five years. Longer-term follow-up is required before recommending this technique more broadly.

Cite this article: *Bone Jt Open* 2021;2-11:921–925.

Keywords: Varus-valgus constraint (VVC), Posterior-stabilized (PS), Primary total knee arthroplasty (TKA), Stems, Instability

Introduction

Varus-valgus constrained (VVC) devices were initially designed for use with dedicated revision femoral components and stems to limit the risk of aseptic loosening during revision total knee arthroplasty (TKA).¹⁻⁴ However, VVC devices have become more commonly used in complex primary TKAs, often without the use of adjunctive stem fixation.⁵⁻⁸

In at least one system, the VVC insert is compatible with the primary

posterior-stabilized (PS) femoral component.⁹ Surgeons may be tempted to occasionally pair that VVC insert with a standard, non-stemmed PS femur in unique, complex primary situations (e.g. femur already cemented, abnormal anatomy). With such unconventional use, loosening of components is a concern.⁷

There is a paucity of literature on the use of a PS femoral component without stems with a VVC insert in the setting of primary

Correspondence should be sent to
Matthew P Abdel; email:
abdel.matthew@mayo.edu

doi: 10.1302/2633-1462.211.BJO-
2021-0134.R1

Bone Jt Open 2021;2-11:921–925.

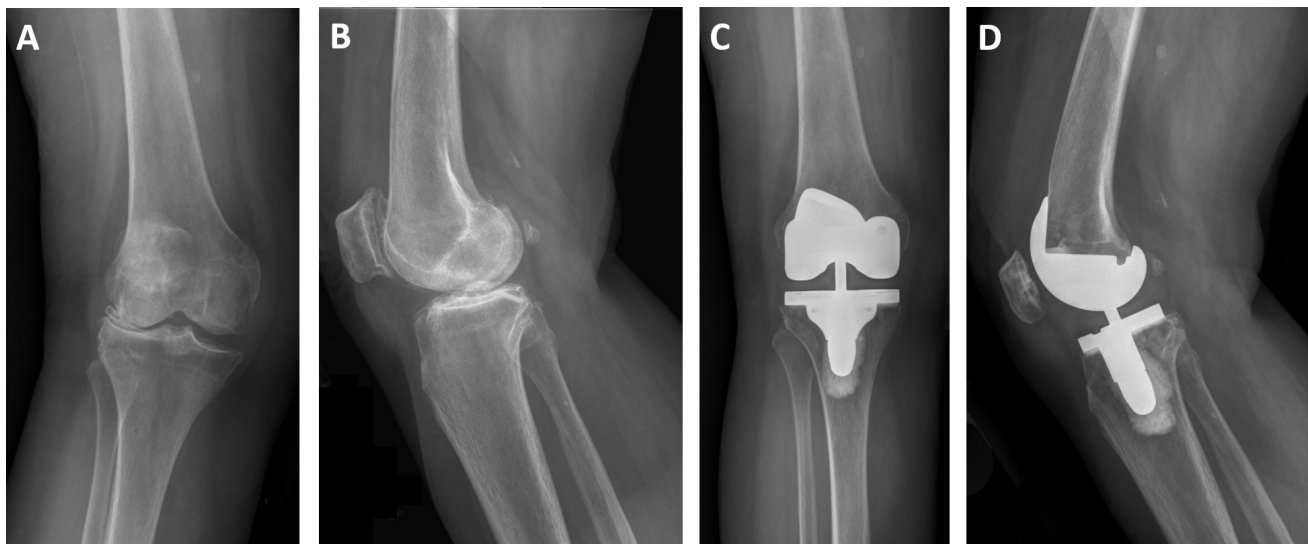


Fig. 1

a) Preoperative anteroposterior b) and lateral radiographs of a patient with a valgus deformity. c) Postoperative anteroposterior d) and lateral radiographs depicting correction of the valgus deformity with the posterior-stabilized femoral component and varus-valgus insert.

TKA.¹⁰ The aims of this study were to determine the implant survivorship, radiological and clinical outcomes, and complications when this VVC insert was coupled with a PS femur without stems in complex primary TKAs.

Methods

Through our institutional total joint registry, we identified 103 patients who underwent 113 primary TKAs performed between 2007 to 2017 in which a VVC insert was coupled with a standard cemented PS femur without stems or other adjuvant fixation (total stabilizing (TS) insert, Triathlon PS femur (Stryker, USA)). Of note, this is an on-label usage of this implant. During the study period, a total of 1,961 Stryker PS femora were used in primary TKAs. Thus, our cohort represents 5.8% of all Stryker PS femora used during the study period. Mean patient age at the time of TKA was 68 years (standard deviation (SD) 10). Mean BMI was 32 kg/m² (SD 7), and 59 of the patients (50%) were male. Prior to study initiation, institutional review board approval was obtained.

All patients had a minimum potential follow-up of two years. Two patients (2%) died prior to reaching two years of follow-up, and 12 patients (12%) had less than two years of follow-up. Mean follow-up was four years (2 to 10) for the remaining patients. In this cohort, 53 patients (47%) had minimum potential follow-up of five years.

Use of a VVC device was used in the setting of a preoperative varus deformity on long leg radiographs in 67 cases (59%) with a mean of 11.6° of varus (standard deviation (SD) 6.0°), a valgus deformity in 43 cases (38%) with a mean of 10.2° of valgus (SD 5.5°; Figure 1), and little or no deformity in three cases (3%).

Statistical analysis. Survivorship was assessed using the Kaplan-Meier method,¹¹ and clinical outcomes were assessed using Knee Society Scores (KSSs).¹²

Data are reported as a mean accompanied by a range for continuous variables and as a count with a percentage for categorical variables. Continuous variables were analyzed using an unpaired t-test. Survivorship was assessed using the Kaplan-Meier method;¹¹ survivorship data are presented with 95% confidence intervals (CIs). Patients who underwent a revision, reoperation, or died were censored at the time of the event. A p-value of 0.05 was considered significant, and all statistical tests were two-sided.

Results

Survivorship. The five-year survivorship free from aseptic loosening was 100%. The five-year survivorship free from any revision was 99% (95% CI 93% to 100%; Figure 2), and the one revision was performed for a chronic periprosthetic joint infection (PJI). This patient was treated with a two-stage exchange protocol.

The five-year survivorship free from any reoperation was 93% (95% CI 82% to 97%; Figure 3). The most common reoperation was for PJI (n = 4: two irrigation and debridements with polyethylene exchange, one two-stage exchange described above, and one irrigation and debridement without polyethylene exchange), followed by manipulation under anaesthesia (MUA; n = 2), and removal of heterotopic ossification (n = 1).

Complications. Survivorship free from any nonoperative complication at five years was 90% (95% CI 76% to 96%). A total of ten complications were identified, including superficial wound infection with no surgical intervention (n

Survivorship Free from Any Revision

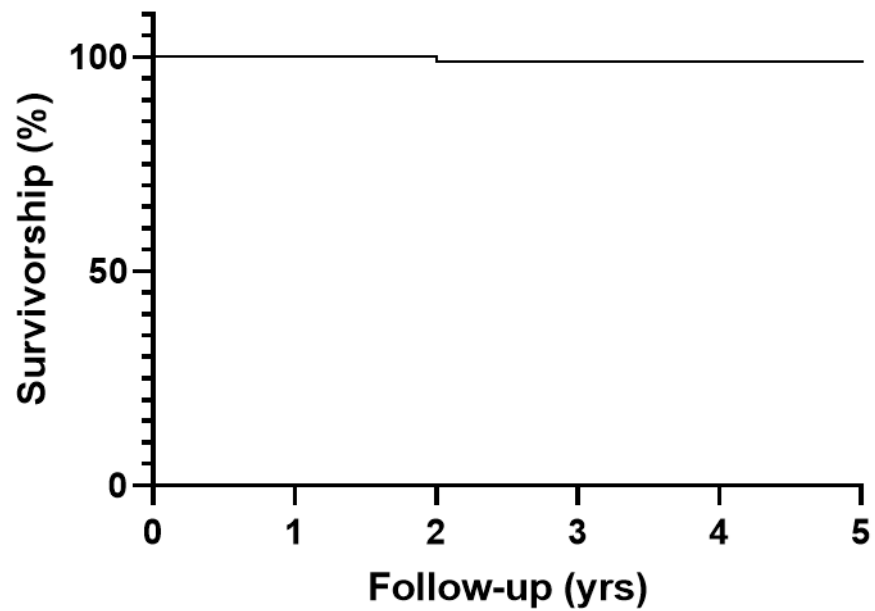


Fig. 2

Kaplan-Meier survivorship curve depicting survivorship free from any revision.

Survivorship Free from Any Reoperation

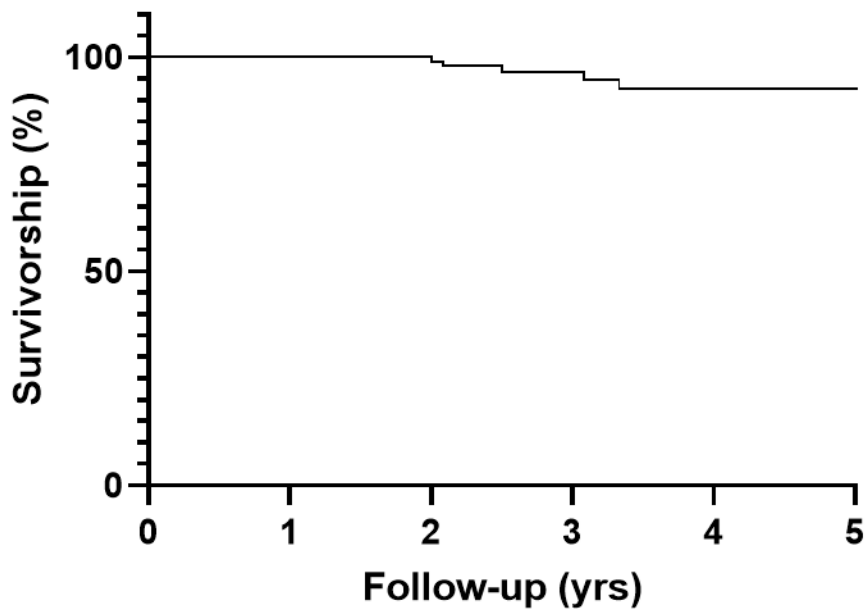


Fig. 3

Kaplan-Meier survivorship curve depicting survivorship free from any reoperation.

= 4), patellar clunk (n = 2), deep vein thrombosis (n = 2), haematoma (n = 1), and stress fracture of the distal femur (n = 1).

Radiological outcomes. At most recent follow-up, two unrevised TKAs (2%) had non-progressive radiolucent lines about both the tibial and femoral components with all others showing no radiological evidence of loosening.

Clinical outcomes. The mean KSS improved from 53 preoperatively (24 to 83) to 88 at latest follow-up (43 to 100; $p < 0.001$, unpaired *t*-test). Range of motion (ROM) improved from a mean of 105° (60° to 135°) preoperatively to a mean of 113° postoperatively (60° to 140°; $p < 0.001$, unpaired *t*-test).

Discussion

This study assessed the mid-term survivorship, clinical and radiological outcomes, and complications of a specific VVC insert paired with a standard, non-stemmed PS femoral component in complex primary TKAs. In this series, we observed no cases of aseptic loosening, with excellent survivorship free from any revision, reoperation, and nonoperative complications at five years.

VVC devices are commonly used in the revision TKA setting, often in combination with metaphyseal cones or sleeves and/or diaphyseal stems. The absence of adjuvant fixation and the use of a VVC insert raises concerns for increased rates of aseptic loosening. However, the present study found a survivorship free from aseptic loosening of 100% at five years. Similar results are reported in various other studies that used constrained implants in complex primary TKAs.^{5,7,8,13} One comparable study examined the outcomes of PS femoral implants with two different inserts, a PS insert (n = 244) and a VVC insert (n = 242), all without stemmed components. The authors reported one revision for aseptic tibial component loosening in the VVC insert group (0.4%) and no cases of aseptic loosening in the PS group at a mean follow-up of 3.25 years.¹⁰ Similarly, Crawford et al,⁷ in a series of 96 patients (103 TKAs), reported no cases of aseptic loosening at a mean follow-up of five years with mid-level constraint without stems in primary TKA. Anderson et al,¹⁴ in a series of 248 non-modular constrained condylar primary TKAs without stem extensions, reported one case of aseptic loosening, which required a femoral component revision and the addition of a diaphyseal stem.

Our study also demonstrates excellent survivorship free from any revision at five years at 99%, with the lone revision being performed for PJI. Other studies of VVC implants for primary TKAs report similar findings with Anderson et al.¹⁴ A systematic review by Avino et al⁶ on the use of VVCs in primary TKA estimated the need for implant revision to be 9% at 12 years postoperatively. Their findings were that VVC devices provided good clinical improvement, but long-term implantation may lead to more failures. It is hypothesized that these late failures

were more likely due to the increased constraint causing mechanical stresses resulting in aseptic loosening.¹⁵ More long-term studies are required to assess survivorship and failures, and to delineate the potential protective role of adjuvant fixation.

Survivorship free from any reoperation at five years was 93% for this cohort, consistent with current literature on the use of constrained implants in primary TKA that have demonstrated a range of 2.5% to 10% of patients requiring a reoperation at early follow-up.^{7,8,10,16} The most common reoperation in our study was treatment of infection followed by MUA for treatment of arthrofibrosis. Several other studies also observed arthrofibrosis as a common complication in this setting.^{7,10,16} It is possible that patients with greater intraoperative laxity who receive VVC devices may be predisposed to arthrofibrosis secondary to subtle laxity not fully addressed by the VVC implant.^{16,17}

Radiological review demonstrated two knees with non-progressive radiolucent lines at most recent follow-up in our study. Anderson et al⁵ reported no radiological evidence of loosening or wear in their cohort of primary constrained arthroplasties. One study comparing the outcomes of primary VVC arthroplasties matched to PS arthroplasties noted no signs of implant loosening in either group at mid-term follow-up.¹³ Additionally, clinical outcomes (KSS and ROM) improved significantly in this cohort. This is comparable to the current literature on this topic.^{5,7,8,14,18} However, in studies that compared PS to VVC implants, no difference in clinical outcomes were detected.^{13,19} Thus, our study adds to the building body of literature suggesting that higher constraint inserts are proving clinically and radiologically durable at mid-term follow-up.

Our study is not without limitations. First, this is a retrospective review using data from a single institution. Second, this is a relatively small cohort of patients with intermediate follow-up; longitudinal surveillance studies will be necessary moving forward, especially for addressing the incidence of aseptic loosening. This is particularly important as the primary concern is eventual aseptic loosening from increased constraint with mismatched implants, combined with lack of adjuvant fixation. Third, this study examines a single implant design, which may limit the transferability of these results to other designs.

In conclusion, for complex primary TKAs, coupling a VVC insert with a standard PS femur without stems, proved reliable and durable at five years. It is particularly notable that aseptic loosening has not presented in any patients clinically or radiologically at mid-term follow-up. Longer-term follow-up is required before recommending this technique more broadly.



Take home message

- For complex primary total knee arthroplasty, in occasional situations, coupling a varus-valgus constrained insert with a standard posterior-stabilized femur without stems proved reliable and durable at five years.

References

1. **Adravanti P, Vasta S.** Varus-valgus constrained implants in total knee arthroplasty: indications and technique. *Acta Biomed.* 2017;88(2s):112–117.
2. **Walker PS, Manktelow AR.** Comparison between a constrained condylar and a rotating hinge in revision knee surgery. *Knee.* 2001;8(4):269–279.
3. **Callaghan JJ, O'Rourke MR, Liu SS.** The role of implant constraint in revision total knee arthroplasty: Not too little, not too much. *J Arthroplasty.* 2005;20(4 Suppl 2):41–43.
4. **Mabry TM, Hanssen AD.** The role of stems and augments for bone loss in revision knee arthroplasty. *J Arthroplasty.* 2007;22(4 Suppl 1):56–60.
5. **Anderson JA, Baldini A, MacDonald JH, Pellicci PM, Sculco TP.** Primary constrained condylar knee arthroplasty without stem extensions for the valgus knee. *Clin Orthop Relat Res.* 2006;442:199.
6. **Avino RJ, King CA, Landy DC, Martell JM.** Varus-valgus constraint in primary total knee arthroplasty: a short-term solution but will it last? *J Arthroplasty.* 2020;35(3):e2:741–746.
7. **Crawford DA, Law JI, Lombardi AV, Berend KR.** Midlevel constraint without stem extensions in primary total knee arthroplasty provides stability without compromising fixation. *J Arthroplasty.* 2018;33(9):2800–.
8. **Maynard LM, Sauber TJ, Kostopoulos VK, Lavigne GS, Sewecke JJ, Sotereanos NG.** Survival of primary condylar-constrained total knee arthroplasty at a minimum of 7 years. *J Arthroplasty.* 2014;29(6):1197–1201.
9. **Martin JR, Fehring KA, Watts CD, Levy DL, Springer BD, Kim RH.** Coronal alignment predicts the use of semi-constrained implants in contemporary total knee arthroplasty. *Knee.* 2017;24(4):863–868.
10. **Deshmukh AJ, Rathod PA, Moses MJ, Snir N, Marwin SE, Dayan AJ.** Does a non-stemmed constrained condylar prosthesis predispose to early failure of primary total knee arthroplasty? *Knee Surg Sports Traumatol Arthrosc.* 2016;24(10):3194–3199.
11. **Bland JM, Altman DG.** Survival probabilities (the Kaplan-Meier method). *BMJ.* 1998;317(7172):1572.
12. **Insall JN, Dorr LD, Scott RD, Scott WN.** Rationale of the knee Society clinical rating system. *Clin Orthop Relat Res.* 1989(248):13.
13. **Puah KL, Chong HC, Foo LSS, Lo N.-N, Yeo S.-J, LSS F.** Clinical and functional outcomes: Primary constrained condylar knee arthroplasty compared with posterior stabilized knee arthroplasty. *J Am Acad Orthop Surg Glob Res Rev.* 2018;2(2):e084.
14. **Anderson JA, Baldini A, MacDonald JH, Tomek I, Pellicci PM, Sculco TP.** Constrained condylar knee without stem extensions for difficult primary total knee arthroplasty. *J Knee Surg.* 2007;20(3):195.
15. **Bourne RB, Baré J.** Failure in cam-post in total knee arthroplasty In: Bellemans J, Ries MD, Victor JM, editors. *Total Knee Arthroplasty.* Germany: Springer. 2005.
16. **Martin JR, Behrs TR, Stuhlmán CR, Trousdale RT.** Complex primary total knee arthroplasty: Long-term outcomes. *J Bone Joint Surg Am.* 2016;98-A(17):1459–1470.
17. **Tibbo ME, SC G, Ahmed AT, vWA J, BD J.** Acquired idiopathic stiffness after total knee arthroplasty: a systematic review and meta-analysis. *J Bone Joint Surg Am.* 2019;101-A(14):1320–1330.
18. **Ruel AV, Lee YY, Boles J, Boettner F, Su E, Westrich GH.** A novel assessment of braking reaction time following THA using a new fully interactive driving simulator. *HSS J.* 2015;11(2):143–147.
19. **Nam D, Umunna B-PN, Cross MB, Reinhardt KR, Duggal S, Cornell CN.** Clinical results and failure mechanisms of a nonmodular constrained knee without stem extensions. *HSS J.* 2012;8(2):96–102.

Author information:

- A. K. Limberg, BS, Research Assistant
- C. C. Wyles, MD, Assistant Professor of Anatomy, College of Medicine
- M. J. Taunton, MD, Associate Professor of Orthopedics, College of Medicine
- A. D. Hanssen, MD, Professor of Orthopedics, College of Medicine
- M. W. Pagnano, MD, Professor of Orthopedics, College of Medicine
- M. P. Abdel, MD, Professor of Orthopedics, College of Medicine
Department of Orthopedic Surgery, Mayo Clinic, Rochester, Minnesota, USA.

Author contributions:

- A. K. Limberg: Data curation, Formal analysis, Writing - original draft.
- C. C. Wyles: Data curation, Formal analysis, Writing - review & editing.
- M. J. Taunton: Writing - review & editing.
- A. D. Hanssen: Writing - review & editing.
- M. W. Pagnano: Writing - review & editing.
- M. P. Abdel: Conceptualization, Supervision, Writing - review & editing.

Funding statement:

- The author or one or more of the authors have received or will receive benefits for personal or professional use from a commercial party related directly or indirectly to the subject of this article. In addition, benefits have been or will be directed to a research fund, foundation, educational institution, or other non-profit organization with which one or more of the authors are associated.

ICMJE COI statement:

- M. P. Abdel reports being on the board of directors on the American Academy of Orthopedic Surgeons, and royalties from Stryker, which are outside of this submitted work. M. W. Pagnano declares consultancy for Turbett Surgical, and royalties from DePuy Synthes and Stryker, which are unrelated to this work. M. J. Taunton reports board membership to the American Association of Hip and Knee Surgeon, the American Academy of Orthopaedic Surgeons, and the Journal of Arthroplasty, consultancy for DJO Global, royalties from DJO Global and the Journal of Arthroplasty, and research support for Stryker, all of which are also unrelated to this article.

Ethical review statement:

- IRB ID: 17-010459

Open access funding

- The authors report that the open access funding for this manuscript was self-funded.

© 2021 Author(s) et al. This is an open-access article distributed under the terms of the Creative Commons Attribution Non-Commercial No Derivatives (CC BY-NC-ND 4.0) licence, which permits the copying and redistribution of the work only, and provided the original author and source are credited. See <https://creativecommons.org/licenses/by-nc-nd/4.0/>