

Total elbow arthroplasty: A narrative review

INTRODUCTION

Although the first resection and interposition arthroplasties of the elbow were reported at the beginning of the 20th century, modern total elbow arthroplasty (TEA) started in the late 1960s with a cemented hinge design described by Dee and Sweetnam.¹⁻³ Since then, other implants have been introduced with advances in design.⁴

Total elbow arthroplasty can be used to treat elbow joint pathology such as rheumatoid arthritis (RA), osteoarthritis (OA), trauma, and post-traumatic sequelae.⁵⁻⁷ In addition, TEA is used in rarer conditions, such as in haemophilic arthropathy, as well as in tumour reconstruction.^{8,9} From the early 1970s to the late 1990s, RA was the most common indication globally for TEA. In this millennium, the development of effective biologic drugs such as anti-TNF α – a medication for treatment of RA – has resulted in a marked decrease in the number of TEAs (Fig. 1).^{5-7,10,11} Simultaneously, TEA has been used more and more to treat primary osteoarthritis and post-traumatic sequelae such as instability, as well as acute elbow fractures in elderly patients who are both increasingly frail and have greater functional demands.

Compared with lower limb arthroplasty, TEA can be considered an uncommon procedure, with an annual incidence of 1.4 per

100 000 people in Western countries.^{12,13} In Europe, TEA incidence has slightly but constantly decreased from the late 1990s (Fig. 1).^{12,14} Conversely, in the United States there has been an annual rise of 6.4% between 1993 and 2007, from 1000 to 2400 procedures

per year. This has been projected to continue in the future.^{15,16} In addition, TEA is used more and more often to treat the conditions of younger patients, and there has been growing interest in the causes of complications and revision surgery.^{4,12,16-20}

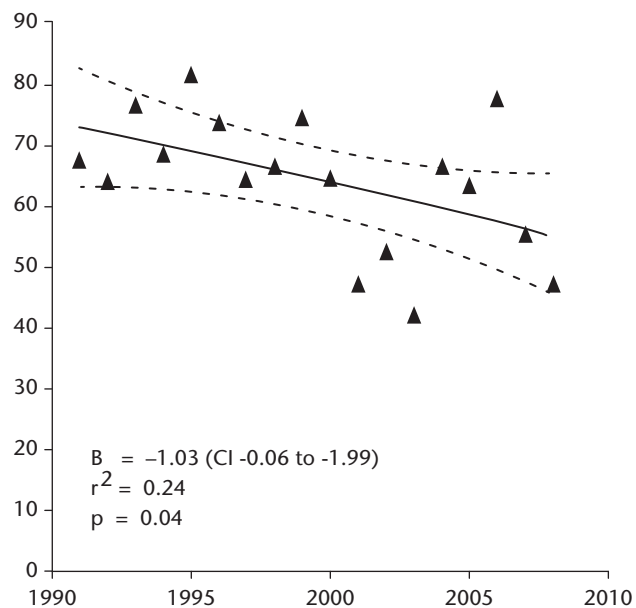


Fig. 1 Annual numbers of TEAs over time. Figure reprinted from Jenkins PJ, Watts AC, Norwood T, et al. Total elbow replacement: outcome of 1,146 arthroplasties from the Scottish Arthroplasty Project. *Acta Orthop* 2013;84:119-123.

T. Luukkala MD

A. C. Watts BSc, MBBS, FRCS(Tr.&Orth)

T. Luukkala, MD, Consultant Hand and Elbow Surgeon, Central Finland Health Care District, Jyväskylä, Finland

A. C. Watts, BSc, MBBS, FRCS(Tr.&Orth), Consultant Hand & Upper Limb Surgeon, Wrightington Hospital, Wigan and Leigh NHS Trust, UK

email: toni.luukkala@ksshp.fi

IMPLANT DESIGNS

The native elbow is a complex structure combining three different joints. The co-operative function of these allows forearm and hand to be positioned to control the environment, while the same structures also give a high degree of stability despite poor mechanical advantage with long levers and a relatively small surface area.

Over time, the language used to describe the type and biomechanical properties of TEA articulation have become confused. The terms 'linked' and 'constrained' are used interchangeably, yet they are two different properties. The term 'linked' refers to the physical property of mechanical connection between the humeral and ulnar components that does not allow disengagement of the two parts, while an 'unlinked' implant has components that are physically separate, and connection of these rely on the 3D surface architecture and soft tissues to provide function and stability. The terms 'constrained' and 'semi-' or 'non-constrained' are used to describe the mechanical properties of the articulation (in terms of control of degrees of freedom). Both linked and unlinked implants could be either constrained or non-constrained depending on the design. The advantage of a linked implant is that it cannot dislocate unless structural failure occurs, but when the link reaches the limits of constraint, torque forces rise rapidly which can lead to loosening. An unlinked implant, on the other hand, may dissipate forces across the articulation into the soft tissues but may be prone to dislocation if the constraint is low, or to loosening if too constrained.

Today, there are three basic commercially available TEA subtypes: a loose hinge (linked and semi-constrained), resurfacing (unlinked and semi-constrained), and prostheses that can be converted from unlinked to linked if needed.

Implant stems can be short or long, can be coated with various materials such as plasma spray, porous beads, titanium spray or polymethyl methacrylate, and can be fixed with or without cement.²¹⁻²⁴ The addition of an anterior flange is widely considered to reduce humeral stem migration, although biomechanical and

clinical studies have failed to demonstrate any advantage. All of these details might have an association with implant survival as well as specific complications.

Despite these design differences, no clear difference in rates of loosening of the most widely used linked and unlinked prosthetic models has been found in national studies.^{14,25} The Danish registry study observed a trend towards higher revision rates in unlinked designs and thus in Denmark most of the implants used since 2006 have been linked.²⁶ However, this comparison does not consider the effect of constraint, with many older unlinked designs exhibiting high constraint and therefore a risk of wear and loosening.

BEARING DESIGN

Linked

Early TEA designs were simple, hinge-like joints, which did not allow movement in anything other than the extension-flexion plane. This results in intrinsic constraint not present in normal elbow joints, which eventually leads to a loosening of the implant.²⁷⁻³¹ Today, most of the commercially available designs (including those produced by Zimmer, Warsaw, Indiana (1999); Biomet, Warsaw, Indiana (2011); and Tornier, Stafford, Texas (2011)) are semi-constrained or 'sloppy' hinges, allowing around 7° of varus-valgus movement and internal-external rotation, and thus mimicking the normal joint in addition to the extension-flexion plane of motion. Conceptually, a linked implant eliminates the biomechanical dependence on soft-tissue constraint to provide stability. Indeed, linked TEAs can even be used in situations where the soft-tissue condition is compromised and the ligaments are not maintaining stability, such as rheumatoid arthritis with significant deformity, fracture or revision surgery.

TEA bearing design can be split into three groups: cylindrical (Coonrad-Morrey, Zimmer-Biomet, Warsaw, Indiana); concave cylinder (Latitude EV, Tornier/Wright Medical, Memphis, Tennessee); and hourglass (Discovery, Biomet, Warsaw, Indiana). The bearing design of these

commonly used implants is illustrated in Figure 2.

Globally, the current most widely used design is the Coonrad-Morrey prosthesis, where humeral and ulnar components are linked in cylindrical fashion. The evolution of this implant traces our understanding of TEA design. The initial Coonrad implant was a smooth, shorter-stemmed linked implant with 3° of varus-valgus movement. In stages, the constraint was reduced to allow 7° of movement in the coronal plane, the stems lengthened, an anterior flange added to the humeral component and a coating applied. The Coonrad-Morrey articulation consists of a forked titanium alloy humeral component articulating with an ulnar component via ultra-high-molecular-weight polyethylene (UHMWPE) bushings and a cobalt-chromium (CoCr) axle or link-pin. The ulnar component has a cylindrical UHMWPE bushing which is larger in diameter than the axle. It has been suggested that this cylindrical design produces high stresses on the edges of the polyethylene, resulting in bushing wear, polyethylene debris and loosening of the implant that has been a clinical concern.^{32,33}

Newer bearing designs, such as the Latitude and Discovery, are an attempt to address this problem.^{22,34} The Latitude implant can be used as a linked or unlinked implant. When linked, the fork-shaped cobalt-chrome (CoCr) stem holds the CoCr concave cylinder shape on both ends, and the UHMWPE bushing of the CoCr ulnar stem loosely conforms to the axle. The axle of the Discovery design is made of two CoCr hemispheres that form an hourglass-shaped structure, which is connected at both ends to a titanium stem. The titanium ulnar stem has UHMWPE bushings that loosely conform to this hourglass structure. Finite element analysis (FEA) suggests that these designs might produce lower contact stress on the bushings; however, at the moment there is no clinical data to demonstrate an advantage. The FEA also shows that the hourglass design of the Discovery might also exhibit a linear increase in torque with varus-valgus displacement, suggesting that it may be acting as more of a constrained













Design	Ulnar	Humeral	Assembly	Cross-section
Cylindrical (CY)	 UHMWPE bushing	 CoCr axle		
Hourglass (HG)	 UHMWPE bushing	 CoCr axle		
Concave Cylinder (CC)	 UHMWPE bushing	 CoCr axle		

Fig. 2 Three commonly used modern linked bearing models. Cylindrical, CY (Coonrad-Morrey, Zimmer-Biomet, Warsaw, Indiana), Hourglass, HG (Discovery, Biomet, Warsaw, Indiana.) and Concave Cylinder (Latitude EV, Tornier/Wright Medical, Inc.). Figure reprinted, with the permission of Taylor and Francis Group, from **Willing R, King GJ, Johnson JA**. The effect of implant design of linked total elbow arthroplasty on stability and stress: a finite element analysis. *Comput Method Biomech Biomed Engin* 2014;17:1165-1172.

hinge.³⁵ Compared with the Coonrad-Morrey prosthesis, these newer designs show comparable short- to mid-term results.³⁶⁻⁴³ However, it is important to bear in mind that evidence is limited and, indeed, contradictory reports from the Swedish Arthroplasty Register have been published that suggest a higher risk of revision with newer models.⁴⁴ There is evidence of early radiological loosening of the Discovery implant.^{37,41} Radiographs of these different linked implants are presented in Figure 3.

A more recent design, the Nexel prosthesis (Zimmer-Biomet), has been introduced with a cylindrical bearing but with rounded corners on the polyethylene to reduce contact stresses; however, no clinical results have been published. The results of modern linked prostheses are summarised in Table I.

Unlinked

The rationale for unlinked TEA is that the soft tissues dissipate forces across the elbow, thereby reducing stress on the bone-cement interface and reducing rates of aseptic loosening. This produces a trade-off between an articulation that is too constrained and functions as a linked device, or one that is not constrained enough and may be prone to dislocation.

Stability of unlinked TEA is dependent on the inherent geometric constraint of the implant design and competent soft-tissue structures. Pre- and intra-operative evaluation of bone stock, the capsuloligamentous structures, the function of peri-articular musculature, soft-tissue balance and implant alignment are of critical importance for success.⁴⁵ However, despite the biomechanical rationale, the aseptic loosening, especially in the ulnar component, remains a concern both in biomechanical and clinical studies.^{21,24} This might be explained by the high constraint ratio of some former models,⁴⁶ as dislocation is a problem inherent to less constrained designs.⁴⁷ Historically, the unlinked TEAs have had higher revision rates.^{18,48} However, recent models show mid-term results comparable with those of linked implant designs. The widely used Souter-Strathclyde system (Stryker, Kalamazoo, Michigan; now withdrawn) had a five-year survival rate of 96% and a ten-year survival rate of 89% when performed in a specialist institution.¹¹ There is no high-quality evidence comparing the outcome.

The historical results of unlinked prostheses are summarised in Table II, and radiographs of historically commonly used designs are presented in Figure 4.

STEM DESIGN

Stem designs have varied and evolved over time. The presence of an anterior flange on the humeral component, the shape of the stems, and the coating material may have a role in implant survival. The biomechanical and clinical studies suggest that the anterior flange popularised initially by the Coonrad-Morrey design may reduce the stresses generated over the humeral stem as a result of torque (Fig. 3a).^{23,49} However, in modern implants with different metaphyseal geometry, such as the Latitude prosthesis, the anterior flange may not have such an important role (Fig. 3b).⁵⁰ Metaphyseal fins on the implant act as an internal flange to limit torque.

The stem surface finish affects the stability between the cement-implant interface. This is considered to be especially important on the ulnar component, where a pistoning effect in flexion is thought to result in early loosening. Some studies have demonstrated that different surface treatments can affect implant survival. The first-generation Coonrad-Morrey plasma spray-coated ulnar component had better survival than the second-generation beaded porous and third-generation PMMA coatings, and so the coating was changed back to a modern plasma spray finish. The risk for failure was

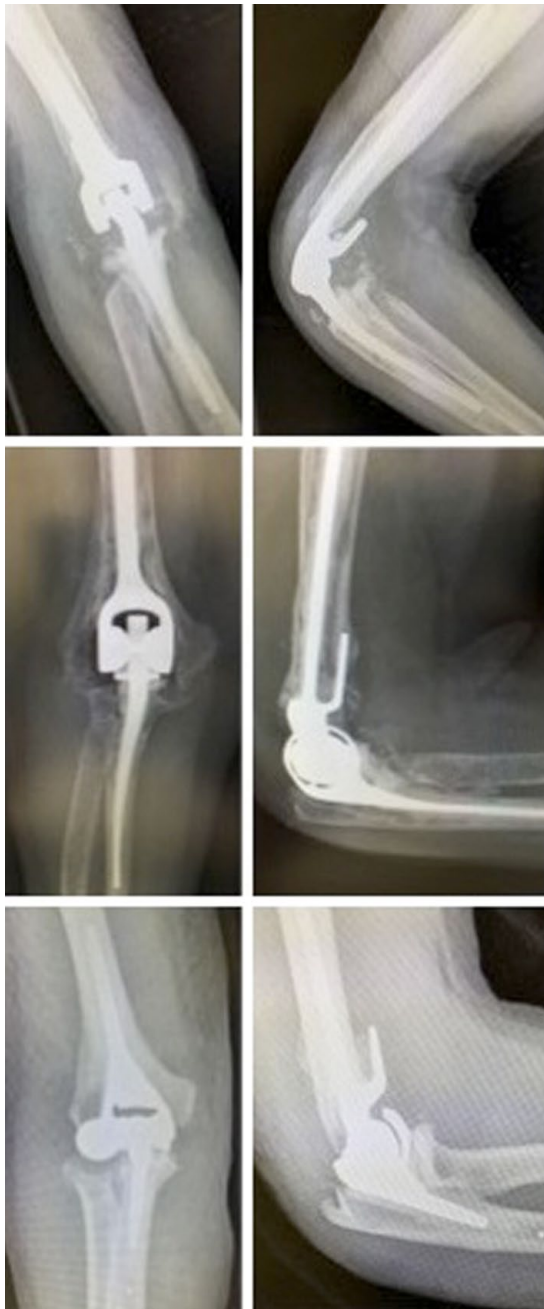

Fig. 3 Radiographs presenting commonly used linked prostheses. From top to bottom: Coonrad-Morrey; Discovery; and Latitude.

significantly higher with PMMA-coated stems than with others.²³ Today, most of the designs either have titanium or cobalt-chrome stems that are surfaced with either plasma spray or small beads. In biomechanical studies, smooth stems have had the poorest outcomes in terms of stability, followed by spray and bead finishing. In addition, it seems that the substrate material may have an effect, with cobalt-chrome stems presenting better survival in cyclic loading in the laboratory than titanium.⁵¹

SURGICAL TECHNIQUE

Given the relatively low annual incidence of TEA, it is clear that experience is accumulated slowly for an individual surgeon working in a non-specialised unit. In lower limb arthroplasty, the experience of the surgeon, as well as that of the institution, has been recognised as an important factor in improving outcomes. Similar trends with regard to TEA can be seen both in Scottish and Finnish registry studies. The Scottish registry study observed that the

revision rate was higher with those surgeons who performed fewer than five procedures per year, particularly when compared with those who performed at least ten. In the Finnish registry study, it was noted that the risk of revision was significantly lower in a specialised institution than in general orthopaedic hospitals.^{12,25}

Several technical factors such as cementing, positioning of the implant, and manipulation of the soft tissue may have an effect on overall outcome and implant survival. Two studies have shown that revision rates were markedly higher with uncemented implants, especially when the ulnar component was left uncemented.^{14,24} In cemented TEAs, a poor cement mantle surrounding the implant and a particularly poor cement-bone interface may be one potential cause for aseptic loosening. On the humeral side, the reverse cone shape of the humerus creates challenges for cementing.⁵² In cadaveric models, meticulous preparation of the intramedullary canal, use of cement restrictor, low-viscosity cement, and a narrow-nozzled cement gun improved cement mantle quality as well as failure load and stress characteristics of the implant.^{53,54} In a recent clinical study, the challenges associated with cementing of the humeral implant were suspected to be related to the use of high-viscosity cement, and therefore the use of low-viscosity cement was proposed as it is known to have good penetration into corticocancellous bone. In the same study, the quality of cementing was worse in the metaphyseal area of the ulna than in the tip, which might be explained by the lack of intramedullary plug on the ulnar side, leading to possible insufficient pressurisation.³⁷

Implant positioning is important because changes in the axis of rotation affect function, and this, combined with alignment errors, is likely to lead to early failure. In the laboratory setting, an error of up to 8° in internal-external rotation and 6° in varus-valgus orientation can occur, and malpositioning may be even more likely in clinical practice.⁵⁵ Furthermore, humeral component malalignment can cause increased load of a linked TEA implant.⁵⁶ Malrotation of the humeral component can cause alteration in articular gliding and kinematics in unlinked TEA.⁵⁷ Additionally, malpositioning of both humeral and ulnar component anterior offsets seems to have adverse effects on functional outcomes such as strength and pain.^{58,59} Ulnar pistoning caused by impingement between the coronoid and anterior flange may result from implanting the ulnar

Table 1. Results and complications of unlinked total elbow arthroplasty systems

Design/study	Follow-up (range)	No. of patients	Survival rate (%)	Total revision rate (%)	Infection (%)	Aseptic loosening (%)	Fracture (%)	Other (%)
Souter-Strathclyde								
Skyttä et al (2009, Finnish registry) ²⁵	8.8 (0 to 25.0)	912	88 (7 yrs), 82 (10 yrs)	N/A	N/A	N/A	N/A	N/A
Ikävalko et al (2009) ¹¹	10.6 (0 to 25)	525	96 (5 yrs), 89 (10 yrs)	18	1.5	12.6	2	Dislocations (3.4)
Plaschke et al (2014, Danish registry) ⁴⁸	N/A	90	91 (5 yrs), 72 (10 yrs)	12.2	N/A	N/A	N/A	N/A
Talwalkar et al (2006) ⁸¹	12 (5 to 6) patients under 50 yrs	31	85 (10 yrs)	16.7	8.3	16.7	2.8	Ulnar nerve neuropathy (8.3)
	7.3 (3 to 16) patients aged 50 yrs or over		80 (10 yrs)					
iBP/Kudo								
Skyttä et al (2009, Finnish registry) ²⁵	6.5 (0 to 13)	218	89 (7 yrs), 83 (10 yrs)	N/A	N/A	N/A	N/A	N/A
Fevang et al (2009, Norwegian registry, Kudo implants) ¹⁴	8.0	161	94 (5 yrs), 85 (10 yrs)	12.4	N/A	5.6	3.1	Luxation or instability (3.1)
Fevang et al (2009, Norwegian registry, iPB implants) ¹⁴	2.9	111		9.9	N/A	2	0	Luxation or instability (9.9)
Kodama et al (2017, Kudo 5 implants) ⁸²	11.7 (10 to 16.9)	41	87.8 (5 yrs), 70.7 (10 yrs)	30	2.4	26.8	N/A	N/A
Ibrahim et al (2017) ⁸³ Juvenile idiopathic arthritis patients	11.4 (5.4 to 17.6)	14	95 (5 yrs), 70 (10 yrs)	42.9	N/A	N/A	N/A	Ulnar neuropathy (28.6)
NES/Norway								
Skyttä et al (2009, Finnish registry) ²⁵	3.5 (0 to 10)	63	92 (4 yrs)	N/A	N/A	N/A	N/A	N/A
Fevang et al (2009, Norwegian registry, Norway implants) ¹⁴	8.9	180	96 (5 yrs), 89 (10 yrs)	10	N/A	10.6	1.1	Luxation or instability (2.2)
Fevang et al (2009, Norwegian registry, NES implants) ¹⁴	3.2	45	93 (4 yrs)	13	N/A	6.7	4.4	Luxation or instability (2.2)
GSB III								
Plaschke et al (2014, Danish registry) ⁴⁸	N/A	60	91 (5 yrs), 89 (10 yrs)	11.7	N/A	N/A	N/A	N/A

N/A, not applicable; iBP, instrumented bone preserving; NES implant, nestorone single rod implant; GSB, Gschwend-Scheier-Bähler

component too distally and is a potential cause of implant loosening.⁶⁰

The benefit of pre-operative templating is well described in arthroplasty in general; however, because intra- and interobserver reliability to template the stems is moderate to substantial in elbow arthroplasty, the predictive value is low and therefore of little worth.⁶¹

Surgical approaches for TEA are numerous and can be divided into triceps-preserving or triceps-releasing approaches. Triceps-detaching techniques improve the view for ulnar preparation and instrumentation; however, rates of triceps insufficiency are underestimated and this

is a factor that becomes progressively important as TEA is performed in ever more active individuals.⁴⁰ In clinical studies, triceps-detaching techniques have been associated with post-operative triceps failures and higher revision rates.^{40,62} Hence, triceps-sparing techniques such as the paratricipital (Alonso-Llames)⁶³ and lateral para-olecranon approaches have been used, although some question whether this increases the risk of implant malalignment and poor cementation.⁶² Limited evidence suggests that the triceps-sparing lateral para-olecranon approach might improve extension strength.⁶⁴

COMPLICATIONS

Historically, the rate of complications after TEA was reported to be significantly higher (43%) than for other large joint arthroplasties. These include infection, aseptic loosening, ulnar nerve neuropathy, instability, dislocation, intra-operative fracture, prosthesis failure, and heterotopic ossification.⁶⁵ The mechanical advances in implant design have reduced the overall complication rates drastically (24%) during the last two decades.⁴

Ulnar nerve complications after TEA are well documented. In a previous systematic review, the overall incidence of permanent ulnar nerve

Table 2. Published series of results and complications of modern linked primary total elbow arthroplasty systems

Design/study	Follow-up, mths (range)	No. of patients	Survival rate (%)	Revision rate (%)	Infection (%)	Aseptic loosening (%)	Fracture (%)	Other (%)
Coonrad-Morrey								
Skyttä et al (2009, Finnish registry) ²⁵	4.6 (0 to 10)	164	89 (7 yrs)	N/A	N/A	N/A	N/A	N/A
Plaschke et al (2014, Danish registry) ⁴⁸	N/A	91	88 (5 yrs), 88 (10 yrs)	8.8	N/A	N/A	N/A	N/A
Sanchez-Sotelo et al (2016) ²³	9 (0 to 30)	461	95 (5 yrs), 92 (10 yrs)	11	7.8	6.3	N/A	Ulnar component loosening main mechanical failure (5.2)
Rheumatoid arthritis patients						Ulnar component loosening (7.4), humeral component loosening (3.5)		
Mansat et al (2013) ⁸⁴	5 (2 to 11)	78	97.5 (5 yrs)	11.5	3.8	5.1	1.3	Ulnar nerve neuropathy (9)
Rheumatoid arthritis and trauma patients			91 (10 yrs)					Triceps weakness (6.4)
Prasad et al (2016) ⁷⁶	13 (10 to 17.5)	37	86 (10 yrs)	15	5.3	31.5	N/A	Radial nerve neurapraxia (10.5)
Trauma patients		(19 in minimum 10-yr study group)						Symptomatic HO (10.5)
Discovery								
Frohstick et al (2017, cementless fixation) ⁸⁵	5.2 (1 to 13)	20	100	0	0	0	0	Non-progressive radiolucency (10)
Hanninen et al (2017) ³⁷	5.3 (2 to 10.3)	90	95.6	4.4	10	3.3	0	Ulnar nerve palsy (3.3); significant signs of incomplete cementing (up to 38); Radiolucent lines after a mean of 5.3 (2 to 20.3) yrs (up to 30); 2 cases of previous generation implant had loose locking screws
Alizadehkhayat et al (2017), ³⁸ after primary operation	4 (2 to 9)	100 (including 25 revisions)	94.7 after primary operation; 80 after revisions	5.3 after primary operation; 20 after revisions	20	Primary (5), revisions (12)	Primary (6.8), revisions (8)	Persistent ulnar neuropathy (3); HO (6.8); non-progressive radiolucency after primary operation (13.3); non-progressive radiolucency after revisions (28)
Mukka et al (2015) ³⁹	4.5 (1 to 8)	25	80	12	8	4	0	Elbow re-operated on because of ulnar nerve entrapment (4) and triceps rupture (4); Radiolucency over distal part over the humeral component (20)
Large et al (2014) ⁴⁰	3.4 (2 to 5.8)	51	90.2 (5 yrs)	7.8	7.8	10	N/A	Radiolucency over the humeral component (31); radiolucency over ulnar component (10); Triceps failure, both Mayo triceps off approach (4)
Giannicola et al (2014) ⁴¹ Distal humeral fractures	3.4 (2.4 to 5.3)	24	N/A	0	4.2	Progressive radiolucency (4.2)	4.2	Transient ulnar neuropathy (8.4); non-progressive radiolucency (4.2)
Hastings et al (2014) ⁴²	4.1 (2 to 5.9)	46	N/A	0	6.7	2.2	0	Loose locking screws (first-generation design) (4.3); loose polyethylene wearing (2.2)
Latitude								
Wagener et al (2015) ⁴³	3.6 (0.7 to 7)	69 (including 12 unlinked conversions)	N/A	N/A	4.3	Radial head disengagement (31); humeral radiolucency (6); ulnar radiolucency (4)	4	Neurological symptoms (ulnar nerve) (13)

N/A, not available; HO, heterotopic ossification

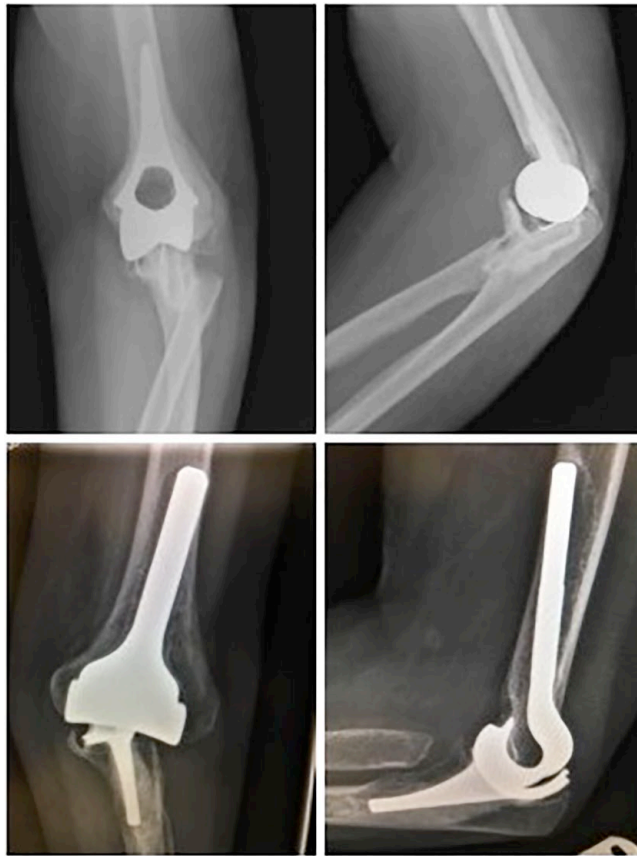

Fig. 4 Radiographs presenting two commonly used unlinked prostheses in the past: Souter-Strathclyde (top) and Kudo (bottom).

neuropathy was estimated to be up to 5% and ulnar nerve problems up to 11%. Reporting has not been performed uniformly in the literature and therefore the true incidence and best treatment are unclear.^{6,67} Nevertheless, combining ulnar nerve release or transposition with the primary operation has been reported by Ewald et al⁶⁷ to reduce transient ulnar nerve complications from 31% to 15%. However, recent literature reports post-operative ulnar nerve problems in 5% to 10% of patients who had undergone routine ulnar nerve transposition in primary TEA, suggesting that it makes little difference.^{68,69}

The infection rate with TEA is reported to be significantly higher than that in other major arthroplasties. In earlier reports, the rate of deep infection was reported to be up to 9%, and more recently, 3%.^{4,65} In cases of infection, retention of the implant may not be possible, and 50% to 90% eventually require implant removal and two-stage revision.⁷⁰⁻⁷²

Aseptic loosening is a major cause of failure and the incidence of clinically significant implant loosening has been estimated to be 7% to 15%, with the non-significant radiolucency

rate even higher.^{7,66,73} The cause for aseptic loosening can be primary failure of the bone-cement interface or osteolysis due to particulate debris from either polyethylene or cement. Fully constrained prostheses had high rates of aseptic loosening (as high as 25%) due to increased stress at the bone-cement interface, and have been replaced in the last three decades with linked semi-constrained prostheses, with loose hinges decreasing the rate (5%).^{4,74}

Aseptic loosening, deep infection, and periprosthetic fractures can lead to a lack of sufficient bone stock. Revision TEA can then be technically demanding. Moreover, soft-tissue coverage and stability may be compromised due to these complications.

Different types of bone loss can be observed. Direct bone destruction can include loss of both cancellous and cortical bone with or without capsuloligamentous and tendon attachment sites. Loss of the olecranon and triceps insertion is particularly difficult to address. Bone loss can be observed as a progressive osteolysis surrounding the implant or cement mantle, eventually leading to cortical thinning and, in more

advanced stages, to a severe ballooning of the cortex before periprosthetic fracture.⁷⁵

IMPLANT SURVIVAL

In the Danish National Patient Registry study, the survival rates of both linked and unlinked TEAs were found to be acceptable after periods of five years (90% for both linked and unlinked TEAs) and ten years (90% for linked and 77% for unlinked TEAs). However, 68 of 324 primary TEAs (21%) underwent revision, with aseptic loosening, periprosthetic fracture, and prosthesis dislocation (unlinked TEAs) being the most common reasons for revision. The infection rate in this series was 7.4% (five cases). The survival results after revision TEA were excellent, with five-year and ten-year survival rates of 96% and 89%, respectively.⁴⁸ In another registry study from Scotland, 1146 TEAs were evaluated. In this study, the ten-year and 18-year implant survivorships for primary TEAs were 90% and 85%, respectively. The ten-year cumulative complication rate for infection was 11%, 0.9% for dislocation, and 1.3% for periprosthetic fracture. The mean revision rate at 18 years was high, at 15%.¹² The Norwegian registry study reported a similar 15% failure rate after ten years of primary TEA.¹⁴

PATIENT-RELATED PREDICTIVE FACTORS

In addition to implant-specific and technique-related factors, patient-specific features will also influence the final outcome.

In the past, inflammatory arthropathy was the most common indication for TEA. During the last two decades, the use has expanded to cover trauma, post-traumatic sequelae and primary osteoarthritis. It can be seen that overall results of TEA are worse in osteoarthritis and trauma than in rheumatoid arthritis.^{76,77}

A study from the United States showed that diabetes is a significant independent risk factor for prolonged hospital stay, and that diabetic patients have significantly higher rates of peri-operative complications such as cerebrovascular attack, pneumonia, myocardial infarction, deep venous thrombosis, and wound infection.⁷⁸

Obesity (especially body mass index > 40 kg/m²) is a significant risk factor for early and late complications such as infections, and the risk of undergoing revision TEA is significantly higher in this patient group.^{40,79,80}

With regard to smoking, an analysis from the National Surgical Quality Improvement Program database in the United States showed that smoking was associated with a near seven-fold increased risk of infection.⁷⁷

CONCLUSION

The outcomes of TEA are not comparable with those of hip and knee surgery. Even though successful TEA can provide excellent individual outcomes, the overall risks remain relatively high. The path to successful TEA is likely to be multifactorial. More care is needed with patient selection, especially when considering TEA for diabetic, obese, or smoking patients. In these cases, the adverse effects of an already risky operation seem to multiply, and other treatment methods should be considered instead. With the total number of procedures decreasing in Western countries and with evidence that the annual volume of the unit and of the surgeon affects outcomes, it would be desirable to centralise these procedures to high-volume units in order to improve results. Furthermore, these units should collaborate with a view to producing high-quality scientific evidence and establishing clinical practice guidelines for this challenging field of surgery.

REFERENCES

1. Scudder CL. Arthroplasty Upon The Elbow Joint. *Ann Surg* 1907;45:297-300.
2. Ashhurst AP. Arthroplasty Of The Elbow. *Ann Surg* 1915;62:302-308.
3. Dee R, Sweetnam DR. Total replacement arthroplasty of the elbow joint for rheumatoid arthritis: two cases. *Proc R Soc Med* 1970;63:653-655.
4. Voloshin I, Schippert DW, Kakar S, Kaye EK, Morrey BF. Complications of total elbow replacement: a systematic review. *J Shoulder Elbow Surg* 2011;20:158-168.
5. Hildebrand KA, Patterson SD, Regan WD, MacDermid JC, King GJ. Functional outcome of semiconstrained total elbow arthroplasty. *J Bone Joint Surg [Am]* 2000;82-A:1379-1386.
6. Shi LL, Zurakowski D, Jones DG, Koris MJ, Thornhill TS. Semiconstrained primary and revision total elbow arthroplasty with use of the Coonrad-Morrey prosthesis. *J Bone Joint Surg [Am]* 2007;89-A:1467-1475.
7. Aldridge JM III, Lightdale NR, Mallon WJ, Coonrad RW. Total elbow arthroplasty with the Coonrad/Coonrad-Morrey prosthesis. A 10- to 31-year survival analysis. *J Bone Joint Surg [Br]* 2006;88-B:509-514.
8. Adams JE, Reding MT. Hemophilic arthropathy of the elbow. *Hand Clin* 2011;27:151-163, vi.
9. Casadei R, De Paolis M, Drago G, Romagnoli C, Donati D. Total elbow arthroplasty for primary and metastatic tumor. *Orthop Traumatol Surg Res* 2016;102:459-465.
10. Schneeberger AG, Meyer DC, Yian EH. Coonrad-Morrey total elbow replacement for primary and revision surgery: a 2- to 7.5-year follow-up study. *J Shoulder Elbow Surg* 2007;16(Suppl):S47-S54.
11. Ikävalko M, Tiihonen R, Skyttä ET, Belt EA. Long-term survival of the Souter-Strathclyde total elbow replacement in patients with rheumatoid arthritis. *J Bone Joint Surg [Br]* 2010;92-B:656-660.
12. Jenkins PJ, Watts AC, Norwood T, et al. Total elbow replacement: outcome of 1,146 arthroplasties from the Scottish Arthroplasty Project. *Acta Orthop* 2013;84:119-123.
13. Lohmander LS, Engesaeter LB, Herberts P, et al. Standardized incidence rates of total hip replacement for primary hip osteoarthritis in the 5 Nordic countries: similarities and differences. *Acta Orthop* 2006;77:733-740.
14. Fevang B-TS, Lie SA, Havelin LI, Skredderstuen A, Furnes O. Results after 562 total elbow replacements: a report from the Norwegian Arthroplasty Register. *J Shoulder Elbow Surg* 2009;18:449-456.
15. Day JS, Lau E, Ong KL, et al. Prevalence and projections of total shoulder and elbow arthroplasty in the United States to 2015. *J Shoulder Elbow Surg* 2010;19:1115-1120.
16. Gay DM, Lyman S, Do H, et al. Indications and reoperation rates for total elbow arthroplasty: an analysis of trends in New York State. *J Bone Joint Surg [Am]* 2012;94-A:110-117.
17. Toor AS, Jiang JJ, Shi LL, Koh JL. Comparison of perioperative complications after total elbow arthroplasty in patients with and without diabetes. *J Shoulder Elbow Surg* 2014;23:1599-1606.
18. Park S-E, Kim J-Y, Cho S-W, Rhee S-K, Kwon S-Y. Complications and revision rate compared by type of total elbow arthroplasty. *J Shoulder Elbow Surg* 2013;22:1121-1127.
19. Cook C, Hawkins R, Aldridge JM III, et al. Comparison of perioperative complications in patients with and without rheumatoid arthritis who receive total elbow replacement. *J Shoulder Elbow Surg* 2009;18:21-26.
20. Krenek L, Farnig E, Zingmond D, SooHoo NF. Complication and revision rates following total elbow arthroplasty. *J Hand Surg Am* 2011;36:68-73.
21. Completo A, Pereira J, Fonseca F, et al. Biomechanical analysis of total elbow replacement with unlinked iBP prosthesis: an in vitro and finite element analysis. *Clin Biomech (Bristol, Avon)* 2011;26:990-997.
22. Hastings H II, Theng CS. Total elbow replacement for distal humerus fractures and traumatic deformity: results and complications of semiconstrained implants and design rationale for the Discovery Elbow System. *Am J Orthop (Belle Mead NJ)* 2003;32(Suppl):20-28.
23. Sanchez-Sotelo J, Baghdadi YMK, Morrey BF. Primary linked semiconstrained total elbow arthroplasty for rheumatoid arthritis: a single-institution experience with 461 elbows over three decades. *J Bone Joint Surg [Am]* 2016;98-A:1741-1748.
24. van der Heide HJL, de Vos MJ, Brinkman J-M, et al. Survivorship of the KUDO total elbow prosthesis—comparative study of cemented and uncemented ulnar components: 89 cases followed for an average of 6 years. *Acta Orthop* 2007;78:258-262.
25. Skyttä ET, Eskelinen A, Paavolainen P, Ikävalko M, Remes V. Total elbow arthroplasty in rheumatoid arthritis: a population-based study from the Finnish Arthroplasty Register. *Acta Orthop* 2009;80:472-477.
26. Giannicola G, Sacchetti FM, Antonietti G, et al. Radial head, radiocapitellar and total elbow arthroplasties: a review of recent literature. *Injury* 2014;45:428-436.
27. Souter WA. Arthroplasty of the elbow with particular reference to metallic hinge arthroplasty in rheumatoid patients. *Orthop Clin North Am* 1973;4:395-413.
28. Dee R. Total replacement of the elbow joint. *Orthop Clin North Am* 1973;4:415-433.
29. Brumfield RHJ Jr, Kuschner SH, Gellman H, Redix L, Stevenson DV. Total elbow arthroplasty. *J Arthroplasty* 1990;5:359-363.
30. Garrett JC, Ewald FC, Thomas WH, Sledge CB. Loosening associated with G.S.B. hinge total elbow replacement in patients with rheumatoid arthritis. *Clin Orthop Relat Res* 1977;127:170-174.
31. Morrey BF, Bryan RS. Complications of total elbow arthroplasty. *Clin Orthop Relat Res* 1982;170:204-212.
32. Aldridge JM III, Lightdale NR, Mallon WJ, Coonrad RW. Total elbow arthroplasty with the Coonrad/Coonrad-Morrey prosthesis. A 10- to 31-year survival analysis. *J Bone Joint Surg [Br]* 2006;88-B:509-514.
33. Wright TW, Hastings H II. Total elbow arthroplasty failure due to overuse, C-ring failure, and/or bushing wear. *J Shoulder Elbow Surg* 2005;14:65-72.
34. Gramstad GD, King GJW, O'Driscoll SW, Yamaguchi K. Elbow arthroplasty using a convertible implant. *Tech Hand Up Extrem Surg* 2005;9:153-163.
35. Willing R, King GJW, Johnson JA. The effect of implant design of linked total elbow arthroplasty on stability and stress: a finite element analysis. *Comput Methods Biomech Biomed Engin* 2014;17:1165-1172.
36. Frostick SP, Elsheikh AA, Mohammed AA, Wood A. Results of cementless total elbow arthroplasty using the Discovery elbow system at a mean follow-up of 61.8 months. *J Shoulder Elbow Surg* 2017;26:1348-1354.
37. Hänninen P, Niinimäki T, Flinkkilä T, et al. Discovery Elbow System: clinical and radiological results after 2- to 10-year follow-up. *Eur J Orthop Surg Traumatol* 2017. (Epub ahead of print) PMID: 28391518.
38. Alizadehkhayati O, Mandhari AI A, Sinopidis C, Wood A, Frostick S. Total elbow arthroplasty: a prospective clinical outcome study of Discovery Elbow System with a 4-year mean follow-up. *J Shoulder Elbow Surg* 2015;24:52-59.
39. Mukka S, Berg G, Hassany HRH, et al. Semiconstrained total elbow arthroplasty for rheumatoid arthritis patients: clinical and radiological results of 1-8 years follow-up. *Arch Orthop Trauma Surg* 2015;135:595-600.
40. Large R, Tambe A, Cresswell T, Espag M, Clark DI. Medium-term clinical results of a linked total elbow replacement system. *Bone Joint J* 2014;96-B:1359-1365.
41. Giannicola G, Scacchi M, Polimanti D, Cinotti G. Discovery elbow system: 2- to 5-year results in distal humerus fractures and posttraumatic conditions: a prospective study on 24 patients. *J Hand Surg Am* 2014;39:1746-1756.
42. Hastings H II, Lee DH, Pietrzak WS. A prospective multicenter clinical study of the Discovery elbow. *J Shoulder Elbow Surg* 2014;23:e95-e107.
43. Wagener ML, de Vos MJ, Hannink G, et al. Mid-term clinical results of a modern convertible total elbow arthroplasty. *Bone Joint J* 2015;97-B:681-688.
44. No authors listed. Swedish Shoulder and Elbow Arthroplasty Registry 2011 and 2012. 2013. <http://ssas.se/files/docs/rapp13.pdf> (date last accessed 30 October 2017). (in Swedish).
45. Marsh JP, King GJW. Unlinked total elbow arthroplasty. *Instr Course Lect* 2015;64:231-242.

46. **Kamini S, O'Driscoll SW, Urban M, et al.** Intrinsic constraint of unlinked total elbow replacements—the ulnotrochlear joint. *J Bone Joint Surg [Am]* 2005;87-A:2019–2027.
47. **Ring D.** Instability after total elbow arthroplasty. *Hand Clin* 2008;24:105–112.
48. **Plaschke HC, Thillemann TM, Brorson S, Olsen BS.** Implant survival after total elbow arthroplasty: a retrospective study of 324 procedures performed from 1980 to 2008. *J Shoulder Elbow Surg* 2014;23:829–836.
49. **Craik JD, Laffer CHL, Richards SW, Walsh SP, Evans SL.** Distal humerus cortical strains following total elbow arthroplasty. *Proc Inst Mech Eng H* 2013;227:120–128.
50. **Quenneville CE, Austman RL, King GJW, Johnson JA, Dunning CE.** Role of an anterior flange on cortical strains through the distal humerus after total elbow arthroplasty with a latitude implant. *J Hand Surg Am* 2008;33:927–931.
51. **Hosein YK, King GJ, Dunning CE.** The effect of stem surface treatment and material on pistoning of ulnar components in linked cemented elbow prostheses. *J Shoulder Elbow Surg* 2013;22:1248–1255.
52. **Goldberg SH, Omid R, Nassr AN, Beck R, Cohen MS.** Osseous anatomy of the distal humerus and proximal ulna: implications for total elbow arthroplasty. *Journal of Shoulder and Elbow Surgery*. 2007;16(Suppl):S39–S46.
53. **Smith GCS, McCann PS, Simpson D, Blewitt N, Amirfeyz R.** The effect of using a cement gun with a narrow nozzle on cement penetration for total elbow arthroplasty: a cadaveric study. *J Hand Surg Am* 2015;40:276–280.
54. **Faber KJ, Cordy ME, Milne AD, et al.** Advanced cement technique improves fixation in elbow arthroplasty. *Clin Orthop Relat Res* 1997;334:150–156.
55. **Brownhill JR, Furukawa K, Faber KJ, Johnson JA, King GJW.** Surgeon accuracy in the selection of the flexion-extension axis of the elbow: an in vitro study. *J Shoulder Elbow Surg* 2006;15:451–456.
56. **Brownhill JR, Pollock JW, Ferreira LM, Johnson JA, King GJW.** The effect of implant malalignment on joint loading in total elbow arthroplasty: an in vitro study. *J Shoulder Elbow Surg* 2012;21:1032–1038.
57. **King GJ, Itoi E, Niebur GL, Morrey BF, An KN.** Motion and laxity of the capitellocondylar total elbow prosthesis. *J Bone Joint Surg [Am]* 1994;76-A:1000–1008.
58. **Figgie HE III, Inglis AE, Mow C.** A critical analysis of alignment factors affecting functional outcome in total elbow arthroplasty. *J Arthroplasty* 1986;1:169–173.
59. **Lenoir H, Micallef JP, Djerbi I, et al.** Total elbow arthroplasty: influence of implant positioning on functional outcomes. *Orthop Traumatol Surg Res* 2015;101:721–727.
60. **Cheung EV, O'Driscoll SW.** Total elbow prosthesis loosening caused by ulnar component pistoning. *J Bone Joint Surg [Am]* 2007;89-A:1269–1274.
61. **Prkić A, van Bergen CJA, The B, Eygendaal D.** Pre-operative templating in total elbow arthroplasty: not useful. *Arch Orthop Trauma Surg* 2016;136:617–621.
62. **Dachs RP, Fleming MA, Chivers DA, et al.** Total elbow arthroplasty: outcomes after triceps-detaching and triceps-sparing approaches. *J Shoulder Elbow Surg* 2015;24:339–347.
63. **Alonso-Llames M.** Bilateral-tricipital approach to the elbow: its application in the osteosynthesis of supracondylar fractures of the humerus in children. *Acta Orthop Scand* 1972;43:479–490.
64. **Studer A, Athwal GS, MacDermid JC, Faber KJ, King GJW.** The lateral para-olecranon approach for total elbow arthroplasty. *J Hand Surg Am* 2013;38:2219–2226.e3.
65. **Gschwend N, Simmen BR, Matejovsky Z.** Late complications in elbow arthroplasty. *J Shoulder Elbow Surg* 1996;5(2 Pt 1):86–96.
66. **Little CP, Graham AJ, Carr AJ.** Total elbow arthroplasty: a systematic review of the literature in the English language until the end of 2003. *J Bone Joint Surg [Br]* 2005;87-B:437–444.
67. **Ewald FC, Simmons EDJ Jr, Sullivan JA, et al.** Capitellocondylar total elbow replacement in rheumatoid arthritis. Long-term results. *J Bone Joint Surg [Am]* 1993;75-A:498–507.
68. **Kim JM, Mudgal CS, Konopka JF, Jupiter JB.** Complications of total elbow arthroplasty. *J Am Acad Orthop Surg* 2011;19:328–339.
69. **Dachs RP, Vrettos BC, Chivers DA, Du Plessis JP, Roche SJ.** Outcomes After Ulnar Nerve In Situ Release During Total Elbow Arthroplasty. *J Hand Surg Am* 2015;40:1832–1837.
70. **Yamaguchi K, Adams RA, Morrey BF.** Infection after total elbow arthroplasty. *J Bone Joint Surg [Am]* 1998;80-A:481–491.
71. **Wolfe SW, Figgie MP, Inglis AE, Bohn WW, Ranawat CS.** Management of infection about total elbow prostheses. *J Bone Joint Surg [Am]* 1990;72-A:198–212.
72. **Somerson JS, Morrey ME, Sanchez-Sotelo J, Morrey BF.** Diagnosis and management of periprosthetic elbow infection. *J Bone Joint Surg [Am]* 2015;97-A:1962–1971.
73. **Kraay MJ, Figgie MP, Inglis AE, Wolfe SW, Ranawat CS.** Primary semiconstrained total elbow arthroplasty. Survival analysis of 113 consecutive cases. *J Bone Joint Surg [Br]* 1994;76-B:636–640.
74. **Morrey BF, Bryan RS.** Complications of total elbow arthroplasty. *Clin Orthop Relat Res* 1982;170:204–212.
75. **Goldberg SH, Urban RM, Jacobs JJ, et al.** Modes of wear after semiconstrained total elbow arthroplasty. *J Bone Joint Surg [Am]* 2008;90-B:609–619.
76. **Prasad N, Ali A, Stanley D.** Total elbow arthroplasty for non-rheumatoid patients with a fracture of the distal humerus: a minimum ten-year follow-up. *Bone Joint J* 2016;98-B:381–386.
77. **Lovy AJ, Keswani A, Dowdell J, et al.** Outcomes, complications, utilization trends, and risk factors for primary and revision total elbow replacement. *J Shoulder Elbow Surg* 2016;25:1020–1026.
78. **Pope D, Scaife SL, Tzeng TH, Vasdev S, Saleh KJ.** Impact of diabetes on early postoperative outcomes after total elbow arthroplasty. *J Shoulder Elbow Surg* 2015;24:348–352.
79. **Griffin JW, Werner BC, Gwathmey FW, Chhabra AB.** Obesity is associated with increased postoperative complications after total elbow arthroplasty. *J Shoulder Elbow Surg* 2015;24:1594–1601.
80. **Baghdadi YMK, Veillette CJH, Malone AA, Morrey BF, Sanchez-Sotelo J.** Total elbow arthroplasty in obese patients. *J Bone Joint Surg [Am]* 2014;96-A:e70, 1–7.
81. **Talwalkar SC, Givissis PK, Trail IA, Nuttall D, Stanley JK.** Survivorship of the Souter-Strathclyde elbow replacement in the young inflammatory arthritis elbow. *J Bone Joint Surg [Br]* 2005;87-B:946–949.
82. **Kodama A, Mizuseki T, Adachi N.** Kudo type-5 total elbow arthroplasty for patients with rheumatoid arthritis: a minimum ten-year follow-up study. *Bone Joint J* 2017;99-B:818–823.
83. **Ibrahim EF, Rashid A, Thomas M.** Linked semiconstrained and unlinked total elbow replacement in juvenile idiopathic arthritis: a case comparison series with mean 11.7-year follow-up. *J Shoulder Elbow Surg* 2017;26:305–313.
84. **Mansat P, Bonnevalle N, Rongièrès M, Mansat M, Bonnevalle P.** Experience with the Coonrad-Morrey total elbow arthroplasty: 78 consecutive total elbow arthroplasties reviewed with an average 5 years of follow-up. *J Shoulder Elbow Surg* 2013;22:1461–1468.
85. **Frostick SP, Elsheikh AA, Mohammed AA, Wood A.** Results of cementless total elbow arthroplasty using the Discovery elbow system at a mean follow-up of 61.8 months. *J Shoulder Elbow Surg* 2017;26:1348–1354.