

# Children's orthopaedics

**X-ref** For other Roundups in this issue that cross-reference with *Children's orthopaedics* see: [Hip Roundup 5](#); [Trauma Roundup 7, 8](#).

## Paediatric femoral fractures: a single incision nailing? **X-ref**

■ The advent of elastic stable intramedullary nailing (ESIN) has provided an excellent treatment option for a relatively narrow subset of patients (those who are not too heavy and have length-stable fractures), allowing them to get up and move around without pain, using a relatively small incision. While the jury is still out on the precise indications for such a technique, the paediatric team here at 360 are firmly in favour of ESIN, when possible, in the paediatric femur. This paper from [Fresno \(USA\)](#) piqued our interest as it reports a retrospective analysis of 112 consecutive cases of paediatric femoral shaft fractures treated with two different techniques – single and dual incision.<sup>1</sup> A rather large number of the patients were excluded (n = 66), leaving a group of 23 patients treated with a single incision technique and 23 using a standard two-incision technique. The authors capably describe the surgical technique of inserting flexible intramedullary nails with a single 1-2 cm distal femoral incision, without any attempt to produce C- or S-shaped contouring of the intramedullary nail. The second nail was pre-contoured to a J-shaped configuration and inserted through the second entry point through the same incision. The authors then go on to compare the conventional approach using medial and lateral incisions with the single incision group. Both groups were of a similar age (single (5.5 years), and double (7.3 years)), and as perhaps might be expected, there were very few comminuted fractures and the majority were proximal/distal diaphysis.

Despite the small size of both groups we do think that their finding of no difference in time taken to union, and no cases of nonunions or malunions in either group, is probably true. This research neatly describes and provides enough clinical data to support the use of a single incision, in a younger age group with relatively simple proximal or midshaft fractures. The paper is interesting in that it does give a technical alternative, but from a critical perspective the paper should be interpreted with the caveat that the patients were young and that there are no data which legitimise this approach in the older child or younger adolescent. The paper demonstrates that the principle biomechanical understanding of flexible intramedullary nail does not necessarily apply to this age/weight group, and that the paired configuration with maximum divergence at the fracture site may not be necessary.

## Lateral condylar fractures: open or percutaneous? **X-ref**

■ In one of the few prospective studies of the management of this common but difficult injury, paediatric orthopaedic surgeons from [Los Angeles \(USA\)](#) have set out to establish which is the most effective method of treatment of lateral condylar fractures: open or closed.<sup>2</sup> The data was captured from a consecutive cohort of patients treated since 2007 with one or other method and entered into an IRB-approved prospective study. A whopping 225 fractures are reported as part of this study, but 34 were excluded due to short follow-up. The reported results considered 163 patients, with 135 treated with open reduction and pinning (85%), and 28 fractures (15%) treated with closed reduction and percutaneous pinning on the decision of the treating surgeon (based on the indication of 2 mm

of displacement). For fractures displaced between 2 mm and 4 mm, closed reduction was initially attempted and closed pinning was performed. Where an initial displacement was more than 4 mm, or more than 2 mm following closed reduction, surgery was performed with an open reduction and all the fractures were stabilised with a Kirschner wire. At final follow-up of 12 weeks, closed treatment confers an obvious cosmetic advantage because of the avoidance of an unsightly scar. The incidence of complications including avascular necrosis, infection, nonunion or unsatisfactory outcome was similar in both groups.

## Forearm refracture: the risks **X-ref**

■ The majority of paediatric forearm fractures are treated non-operatively, or with manipulation and plaster application. Given the rapid healing and early remodelling capacity of the majority of paediatric patients, this usually passes without incident. However, in a small proportion of patients a refracture can occur, making nailing difficult and leaving the surgeon with a decision as to whether conservative treatment or open reduction and internal fixation (ORIF) is most appropriate. Investigators from [New Brunswick \(USA\)](#) put together a retrospective study based on their database of 2590 patients, all of whom had sustained forearm fractures over a ten-year period.<sup>3</sup> They aimed to investigate factors associated with refracture including patient and treatment elements focussing on period of immobilisation. In their series, refracture was identified in 37 patients (1.4%), and in around one third of cases (36%) this occurred within six weeks of initial plaster removal and was more likely in patients with more than 15 degrees of angulation. The mean period of

primary fracture immobilisation for these patients was 72 days (with individual averages for the whole group of 43 days in cast and 34 days brace immobilisation). Perhaps the two most striking findings here are the very low refracture rate: at 1.4% this is significantly lower than would be expected in this patient group; and the authors reporting an average period of ten weeks immobilisation, which is far longer than would be conventional practice with immobilisation for six weeks. The message, although not the intention of the paper, is to suggest that prolonged immobilisation of the paediatric forearm is an important factor in reducing the rate of refracture. This is an interesting but simple finding, particularly when combined with the observation that patients with larger deformity have a higher refracture rate.

## Tibial spine fractures **X-ref**

■ In a retrospective review of children treated for displaced tibial spine fractures between 2003 and 2011, surgeons in [Boston \(USA\)](#) share their experience of managing tibial spine fractures with either open, closed or arthroscopic management.<sup>4</sup> The authors report a stratified analysis of 76 children, of whom 29 had an open reduction, 28 an arthroscopically-assisted internal fixation and 19 closed management and serial casting. The authors report the groups' demographics, mechanism of injury, radiographic measurements, treatment, duration of immobilisation, follow-up, and final range of motion. In addition, a prospective follow-up added long-term Lysholm scores, return to activity, pain, and satisfaction with treatment. Patients included in this study had all sustained Meyers and McKeever type II (posterior hinge) with anterior portion elevated, and type III (fully displaced) fractures. Sadly, the

prospective follow-up only reports a quarter of patients in each cohort. The conclusions, which, bear in mind were made on very limited data, are that minimally-displaced type II fractures with less than 5 mm elevation can be successfully managed with closed reduction and casting. The authors highlight that a low threshold for open fixation is required in patients with an initial displacement of more than 5 mm, and observed that less than 50% reduction can be expected in these patients. There was a high risk of complication with closed treatment in this group of patients. The authors were unable to demonstrate any tangible differences in the results of open *versus* arthroscopic fixation, and certainly in this series at least it appears that both options result in excellent reduction of the fracture with no difference in longer-term outcomes.

#### The child's knee in MRI X-ref

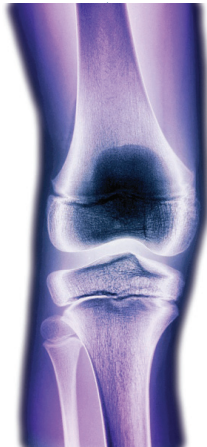
■ There are well-described changes in growing joints on plain films highlighting the specific changes associated with skeletal growth and maturity. Although the patterns outlined on radiographs are used to interpret more modern imaging modalities such as MRI scanning, we were delighted to see this paper from **San Diego (USA)** describing the morphologic changes associated with growth of the paediatric knee during maturation.<sup>5</sup> The authors undertook a retrospective review of MRI scans acquired on 132 patients between the ages of four and 18. Scans were only included when patients had presented with potentially 'normal' knees (diagnostic codes of knee pain, plicae, septic arthritis, jumper's knee, growing pains, benign neoplasm, and osteomyelitis). In common with most diagnostic studies, the authors measured a range of osseous and cartilaginous parameters in an attempt to describe fully the

aging and maturation process. The chief changes noted with the aging process were alteration in the medial patellofemoral ligament (MPFL) osseous insertion, cartilaginous notch width index, MPFL insertion, and trochlear morphology. There were differences between sexes for ACL length, Insall-Salvati ratio, intercondylar width, and sulcus angle. In terms of normal parameters associated with aging, the authors were able to venture a proximal migration of the MPFL origin until age seven when it is located above the femoral physis. Similarly, the ACL sees changes with age and an increase in diameter from 6.5 mm to 9.8 mm. This paper has application to all surgeons and clinicians treating immature patients with knee problems. In particular, the data presented are invaluable in evaluating ACL injury and patellar femoral instability, and the anatomic shifts in the position of the MPFL insertion.

#### The mechanics of slipped upper femoral epiphysis X-ref

■ In an unusual study methodology, researchers from **Bogotá (Colombia)** employed finite element analysis (FEA) to try and relate aetiologic and biomechanical factors that may play a role in the development of a slipped capital femoral epiphysis (SUFE).<sup>6</sup> Their model included a finite element analysis of the hip joint as well as the femur-physis interface. The computational model was set up to include all previously identified risk factors for SUFE, the von Mises stresses along the growth plate were then calculated as the variables were altered. The model was able to take into account physeal-diaphysis angle, body mass, the presence of the perichondrial

ring, type of physical activity, and physeal thickness of the physis. In their model of the hip physis, there was no relationship between physeal thickness, growth plate inclination and the magnitude of von Mises stresses, suggesting that if indeed SUFE is a purely mechanical process,



these have no effect. However, the factors which appeared the most important determinant in slip risk were body mass and physical activity, which is perhaps not at all surprising. One of the major limitations of models such as this is that they do not link potential structural and mechanical changes associated with the factors measured on

physeal development. For example, the physeal angle simply takes into account the mechanical effects of altering the physeal angle and assumes that all other factors are identical, which is unlikely to be true. The alteration in the mechanical angle is highly likely to also alter the morphological development of the growth plate.

#### Idiopathic clubfoot X-ref

■ The range of motion measured on physical examination has a large inherent error, and may not be a perfect measure to determine the need for percutaneous Achilles tenotomy in clubfeet. Researchers in **Seoul (South Korea)** set out to establish what, if any, was the benefit of using radiographic measurements to determine the need for percutaneous Achilles tenotomy in treatment of idiopathic clubfoot.<sup>7</sup> They propose the use of the lateral tibio-calcaneal (LTiC) angle in place of the ankle dorsiflexion (ADF) angle to determine the need for percutaneous Achilles tendon lengthening as part of the Ponsetti technique. The authors report

the results of 125 children, all with idiopathic club feet. Having measured the LTiC and ADF angles in each child, the authors attempted to predict the prognostic chances of relapse on each of the angles. Patients with a low LTiC angle (< 80°) demonstrated no sagittal relapse, even though none were offered percutaneous tenotomy, while those with a higher angle had a higher chance of relapse, even if the ADF was (≥15°). The best predictor on multivariate analysis for the requirement for percutaneous Achilles tenotomy was the LTiC angle. This deceptively simple paper adds significantly to our understanding of which children should receive tenotomy as part of their treatment for club foot.

#### REFERENCES

1. **Knedel M, Gallego EW, Gerardi J, Husak L, Altebarmakian M.** Preliminary report: pediatric femur fractures: single incision intramedullary stabilization technique. *J Pediatr Orthop* 2015;35:657-660.
2. **Silva M, Cooper SD.** Closed reduction and percutaneous pinning of displaced pediatric lateral condyle fractures of the humerus: a cohort study. *J Pediatr Orthop* 2015;35:661-665.
3. **Tisosky AJ, Werger MM, McPartland TG, Bowe JA.** The factors influencing the refracture of pediatric forearms. *J Pediatr Orthop* 2015;35:677-681.
4. **Edmonds EW, Fornari ED, Dashe J, et al.** Results of displaced pediatric tibial spine fractures: a comparison between open, arthroscopic, and closed management. *J Pediatr Orthop* 2015;35:651-656.
5. **Edmonds EW, Bathen M, Bastrom TP.** Normal parameters of the skeletally immature knee: developmental changes on magnetic resonance imaging. *J Pediatr Orthop* 2015;35:712-720.
6. **Castro-Abril HA, Galván F, Garzón-Alvarado DA.** Geometrical and mechanical factors that influence slipped capital femoral epiphysis: a finite element study. *J Pediatr Orthop B* 2015;24:418-424.
7. **Kang S, Park SS.** Lateral tibio-calcaneal angle as a determinant for percutaneous achilles tenotomy for idiopathic clubfeet. *J Bone Joint Surg [Am]* 2015;97-A:1246-1254.