

# ROUNDUP<sup>360</sup>

## Shoulder & Elbow

### Clavicular fractures are being fixed – but how?

#### x-ref Trauma

■ One of the biggest about-turns in trauma care has been the wholesale move from an almost universal conservative treatment regimen to primary fixation in displaced midshaft clavicular fractures. Initially spurred on by the COT study, and latterly with more refined indications from two subsequently reporting studies from the UK and Finland, most surgeons now have a broader view of clavicular fracture treatment that includes primary fixation in certain cases. Having established that surgery improves clinical outcomes, the next logical step would be to test the various different operative strategies. This is exactly what two separate study teams have set out to do in randomised controlled trials (RCTs). First up is a study team from **Amsterdam (The Netherlands)** where the authors report their RCTs of 120 patients randomised to either open reduction and plate fixation or intramedullary nailing.<sup>1</sup> Outcomes were assessed using both the Disabilities of the Arm, Shoulder and Hand (DASH) and Constant scores at a year post-operatively. There were few differences in outcomes between the groups at six months post-operatively but the plate group did achieve their eventual result quicker. There were no differences in incidence of complications, which was not insignificant with around 0.7 complications per patient. In a

remarkably similar study, a collaborative group in **São Paulo (Brazil)** and **Dübendorf (Switzerland)**, report their own prospective RCT with a smaller cohort of 60 patients, randomised to either elastic stable intramedullary nailing (ESIN) or plate fixation.<sup>2</sup> Outcomes were again assessed using the DASH and Constant scores at six months of follow-up, although the authors of this study placed more emphasis on secondary outcomes of radiographic union and again reported complication rates. A similarly equivocal set of results was seen with the nail and plate group. There were no significant differences in outcome scores although there were some differences in secondary measures. In this series, post-operative pain and implant irritation were more significant in the ESIN group where shortening (surprisingly) was reported as more likely to happen with the plate group (a finding we find curious here at 360). So how best to integrate these two studies into current practice? Do they really, as the authors of both studies suggest, leave surgeons with the choice of either? While it might be tempting to think that, we are less certain here at 360. All three of the recent studies demonstrated a small but significant benefit of surgical treatment over non-surgical treatment in a selected group of patients (although the authors reach different conclusions, all of which are reasonable given the marginal nature of the benefit). The ‘non-inferiority’ studies here aren’t

really equal. The plate groups (marginally) outperform the nail groups in both studies. Given the also marginal nature of the plate benefit over conservative treatment in other studies we would be concerned that this may not also apply to nailing.

### *Propionibacterium acnes*: a pain in the shoulder?

■ The shoulder surgical community is all too aware of the dangers of *Propionibacterium acnes*, a common commensal in the axilla which has been implicated in infection and early loosening in arthroplasty of the shoulder. Difficult to treat and known to be resilient in the face of surgical prep solutions, *P. acnes* has been implicated in a range of studies in poor outcomes in shoulder arthroplasty. There is surprisingly little data concerning its potential role in poor outcomes following arthroscopic shoulder surgery. A research team from **Philadelphia (USA)** set themselves the task of establishing the effect (or otherwise) of *P. acnes* in outcomes following arthroscopic surgery.<sup>3</sup> With slightly left-of-field methodology the authors report mixed outcomes from a consecutive cohort of shoulder arthroscopies, a subset of revision procedures and a small cohort (32 patients) of patients having primary shoulder arthroscopies. All in all the surgical team undertook 1591 arthroscopic procedures, of which 68 (4.3%) were revision procedures. The rate of *P. acnes* infection at revision surgery was 29.4%, while just one patient (3.2%) had positive cultures

in the control group. To a certain extent the complexity of the study design detracts slightly from the study presented here. The authors have elegantly shown that revision shoulder arthroscopy is associated with positive *P. acnes* infections and that primary arthroscopy is not. They have not, however, demonstrated a causal link to pain and stiffness, simply that having had a previous arthroscopy predisposes patients to *P. acnes* contamination.

### Bacteria, armpits and arthroplasty

■ Hot on the heels of the previous paper suggesting that subclinical infection with *P. acnes* may be responsible for more poor outcomes than previously expected, comes an interesting study from surgical colleagues in **California (USA)**, asking the simple question: does axillary hair increase infection rates?<sup>4</sup> This randomised, controlled volunteer study aimed to establish if surgical site cleanliness is improved through axillary hair clipping or not. The study team enrolled 85 healthy male volunteers and clipped one random axilla in each. Volunteers then had microbiology swabs taken before and after alcoholic chlorhexidine sterilisation to both axillae. Both specimens were cultured for aerobic and anaerobic specimens for 14 days and growth rates quantified. The results suggest that after skin preparation there were no differences in cleanliness of the surgical site, and that there are no differences

in culture rates of *P. acnes* before or after preparation.

### Lasting longer, but unhappy: the woes of shoulder arthroplasty in the under 50s

■ There really isn't a dreadfully large amount of data concerning outcomes in the long term for shoulder arthroplasty in younger patients. In most centres, patients are currently counselled that the outcomes in terms of prosthesis survivorship may not be perfect, but that function is acceptable. Interestingly, in one of the few high-quality prospective studies on the matter, researchers at the **Mayo Clinic (USA)** have found quite the opposite.<sup>5</sup> The research team report the results of their own series of 78 Neer hemiarthroplasties of the shoulder and 36 Neer total shoulder arthroplasties (TSAs). Follow-up is reported here to a minimum of 20 years with both clinical and radiographic outcomes. The results reported are really quite fascinating. The 20-year survival was as high as 75% for hemiarthroplasty and 83% for TSA – much higher than perhaps might be expected. However, clinical outcomes were less desirable. Only 80% of patients reported their shoulder scores were better than pre-operative measures. The determinants of poor outcomes differed between implant varieties with, perhaps as would be expected, hemiarthroplasty patients suffering from glenoid arthrosis, and the total shoulder patients suffering from component loosening. Outcomes in patients requiring re-operations were poorer than in those who did not. These results from a world-leading centre do give us pause for thought with younger patients wishing to have shoulder arthroplasty surgery.

### Recurrent dislocations in the adolescent population

#### x-ref Children's orth

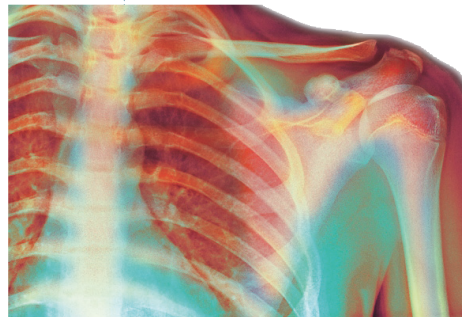
■ There is a volume of work from colleagues in Japan estimating the dislocation risk in the adult population. Itoy and others have undertaken a range of prospective

studies suggesting that the younger the patient, the higher the risk of dislocation. There is, however, little data establishing outcomes in the adolescent population where shoulder dislocation is relatively common. Investigators in **Edinburgh (UK)** have reported their own prospective experience of patients presenting with shoulder dislocations in 133 adolescents with a primary anterior dislocation.<sup>6</sup> Their study suggests that the overwhelming majority of patients are male (86.5%) and that during follow-up of their initial conservative treatment regimen, the vast majority suffered a recurrent dislocation (76.7%). Repeat dislocations occurred at a mean of ten months post-primary presentation. Survival analysis suggests that the chance of having a stable shoulder was just 59% at one year. There were no specific predictors for a favourable outcome with conservative treatment, and quite sensibly the authors of this study suggest that adolescent patients suffering from dislocation of the shoulder should be considered for early operative stabilisation.

### Splinting for elbow stiffness x-ref Trauma

■ The elbow is a fickle joint with high rates of stiffness post-trauma and post-surgery. In part due to the high levels of congruity, and in part due to high incidences of heterotopic ossification and a propensity to form myofibroblast-containing scar tissue, the lot of any surgeon with an interest in elbow surgery is to undertake large volumes of post-traumatic stiffness surgery. Splinting and physiotherapy is the mainstay of conservative treatment for post-traumatic elbow stiffness, and a review team from **Hoofddorp (The Netherlands)** caught our beady eye, here at 360, with their comprehensive review of the topic.<sup>7</sup> They set out to establish which splintage

method offered the most effective treatment for post-traumatic stiffness. Perhaps slightly surprisingly, there were actually eight studies (reporting the results of 232 patients) that met the inclusion criteria. The studies included a range of study-designs and methodologies, but only a single RCT. The cumulative analysis of all studies suggested that in the static splinting group 160 patients



improved their composite motion arc by 36° (from a pre-intervention range of 72°). In the dynamic splinting group, 72 patients improved their range of movement (ROM) by 37° (from a pre-intervention range of 63°). There is ample evidence presented here that splintage and physiotherapy does improve elbow functional ROM, but these improvements are not dependent on the type of splintage. The authors quite reasonably conclude that for post-traumatic stiffness, physiotherapy and splinting is a reasonable first-line treatment and should be continued until improvements stop.

### Revision Bankart repair

■ As arthroscopic shoulder surgery becomes commonplace for the majority of indications, a risk is that surgeons will become less and less skilled at open surgery, which may be required for revision cases. We were therefore heartened to read this report of open revision Bankart repair for failed primary stabilisation from surgeons in **Washington (USA)**.<sup>8</sup> This simple case series, including a decade of follow-up, describes the outcomes of 30 patients who all underwent revision open surgery for their arthroscopic

Bankart repair. The study team report outcomes assessed by an independent examiner and, in common with many case series of this type, reports almost universally good results with 22 patients resuming sports, and a mean American Shoulder and Elbow Surgeons score of 89. There were, however, only 13 patients (of 22 with available radiographs) who did not exhibit some form of radiological signs of degeneration.

### REFERENCES

1. van der Meijden OA, Houwert RM, Hulsmans M, et al. Operative treatment of dislocated midshaft clavicular fractures: plate or intramedullary nail fixation? A randomized controlled trial. *J Bone Joint Surg [Am]* 2015;97-A:613-619.
2. Andrade-Silva FB, Kojima KE, Joeris A, Santos Silva J, Mattar R Jr. Single, superiorly placed reconstruction plate compared with flexible intramedullary nailing for midshaft clavicular fractures: a prospective, randomized controlled trial. *J Bone Joint Surg [Am]* 2015;97-A:620-626.
3. Horneff JG 3rd, Hsu JE, Voleti PB, O'Donnell J, Huffman GR. Propionibacterium acnes infection in shoulder arthroscopy patients with postoperative pain. *J Shoulder Elbow Surg* 2015;24:838-843.
4. Marecek GS, Weatherford BM, Fuller EB, Saltzman MD. The effect of axillary hair on surgical antisepsis around the shoulder. *J Shoulder Elbow Surg* 2015;24:804-808.
5. Schoch B, Schleck C, Cofield RH, Sperling JW. Shoulder arthroplasty in patients younger than 50 years: minimum 20-year follow-up. *J Shoulder Elbow Surg* 2015; 24:705-710.
6. Roberts SB, Beattie N, McNiven ND, Robinson CM. The natural history of primary anterior dislocation of the glenohumeral joint in adolescence. *Bone Joint J* 2015;97-B:520-526.
7. Veltman ES, Doornberg JN, Eygendaal D, van den Bekerom MP. Static progressive versus dynamic splinting for posttraumatic elbow stiffness: a systematic review of 232 patients. *Arch Orthop Trauma Surg* 2015; 135:613-617.
8. Neviasser AS, Benke MT, Neviasser RJ. Open Bankart repair for revision of failed prior stabilization: outcome analysis at a mean of more than 10 years. *J Shoulder Elbow Surg* 2015;24: 897-901.