

# ROUNDUP<sup>360</sup>

## Foot & Ankle

### Ankle arthrodesis is as good for sports as ankle replacement

■ At 360 we have always preferred the concept of arthroplasty to arthrodesis. After all, it works in the hips doesn't it? But plagued by difficult surgical techniques and high rates of aseptic loosening, particularly in the young, successful total ankle replacement (TAR) remains the holy grail in young active patients. We often struggle at 360 to know what to advise our patients who are concerned that arthrodesis may inhibit their sports and recreational activities. Researchers from **Vienna (Austria)** attempted to answer the question, 'how do ankle arthrodesis and TAR compare in function with particular reference to sports and recreational activities?' Using a prospective cohort of patients with either arthrodesis or TAR over a period of 34 months, the authors used the ankle activity score and the University of California, Los Angeles (UCLA) activity scale, combined with the American Orthopaedic Foot and Ankle Society (AOFAS) hindfoot score to establish functional and activity scores. Of the 41 patients included in the study 21 underwent TAR and 20 received an arthrodesis. In both groups 76% of patients were active in sports. The UCLA activity scores were not significantly different in either group (TAR 7.0 *versus* arthrodesis 6.8). Similarly, the AOFAS scores were not different in either group (75.6 in the arthrodesis group *versus* 75.6 in the TAR group). Although both groups suffered a decrease in activity post-

operatively there was no difference in the size of the drop.<sup>1</sup> At 360 we were disappointed to find there was no difference between the two groups. Of course this could be because of an underpowered study, and a larger randomised study would certainly be welcomed. However, we were heartened to find that although not an ideal solution, patients for whom only arthrodesis was suitable have a similar functional result to those undergoing TAR.

### Bologna-Oxford total ankle replacements

■ In the fast evolving world of arthroplasty there are many more designs than there are published studies with good follow-up. Within the world of hip and knee replacements independent verification of series published by the designing surgeons is easily achieved using national joint registries. Not so with ankle, elbow, toe, wrist and hand arthroplasty where few registries exist and series are rarely reported. So 360 was pleased to read this independent review of the Bologna-Oxford (BOX) total ankle replacement (TAR) at mid-term follow-up. An independent group of surgeons in **Milan (Italy)** investigated the BOX TAR. The implant is designed to maximise pain-free movement of the ankle. To date, however, there are no independent series. The researchers designed a retrospective single centre cohort series (Level IV evidence) to examine the function and survivorship of the BOX TAR. They followed the patients up with multiple endpoints; clinically

the patients were assessed with the AOFAS score and radiologically with standardised plain radiographs. The authors included 60 patients with 62 BOX TARs implanted between 2004 and 2008. Two independent observers reviewed the radiographs for signs of loosening or failure. The implant survival was 91.9% at just over 3.5 years mean follow-up. The clinical function was found to be excellent, with the mean AOFAS score improving from 35.1 pre-operatively to 78.0 at final follow-up. This improvement was statistically significant ( $p < 0.01$ ). The researchers, however, noted radiolucencies of  $< 2$  mm in 28% of the surviving 57 TARs. The remaining five TARs had undergone revision for functional limitation or continuing pain.<sup>2</sup> TAR remains a procedure with significant failure and revision rates so it is heartening to see an independent cohort reported in large numbers to mid-term follow-up. Their results of approximately 90% survival with a further 25% signs of radiographic loosening are in line with results presented in the rest of the literature. We do, however, wonder here at 360 if, given the findings of the previous paper of similar activity levels, TAR is worth the high failure rate?

### Surgical treatment of Achilles tendon rupture gives better outcomes

■ The evolving debate as to how to manage Achilles tendon ruptures has been followed carefully here at 360. With many studies ranging from randomised controlled trials to

case reports and reported cohorts, it seems there is a scientific paper to back up any treatment plan, so we were pleased to see an up-to-date systematic review. Researchers in **Buffalo (USA)** designed a qualitative systematic review of randomised controlled trials. They aimed to identify the optimal management of isolated Achilles tendon ruptures, balancing the risk of surgical complications against post-operative function. They hypothesise that there may be no advantage to surgical repair as most studies have not shown a reduction in re-rupture rate when comparing operative and non-operative treatment methods. The study performed a meta-analysis of previously conducted trials using re-rupture as the primary outcome, and secondary outcomes of strength, return to work and complications. The researchers conducted a thorough search including all Level I randomised controlled trials indexed in the commonly used medical search engines. They performed a Coleman methodology score and a weighted meta-analysis with pooled data. The authors identified seven Level I trials describing the treatment of 677 patients that met their inclusion criteria. These were all well conducted studies with Coleman scores of between 78 and 97. The pooled data analysis demonstrated open repair to be significantly superior to non-operative treatments with regards to re-rupture rates (3.6% *versus* 8.8%), but to carry an increased rate of sural nerve palsy, infection and an unsightly scar. The

studies included had far too much heterogeneous strength data for any meaningful meta-analysis to be performed.<sup>3</sup> Here at 360 we are heartened to see some consensus in the data surrounding treatment of Achilles tendon ruptures which will allow patients and clinicians to make more meaningful decisions. At 360 we would like to see more research on this topic, particularly focusing on strength outcomes, and post-operative rehabilitation regimes.

### Selective plantar fascia release – can surgery really help diabetic ulcers?

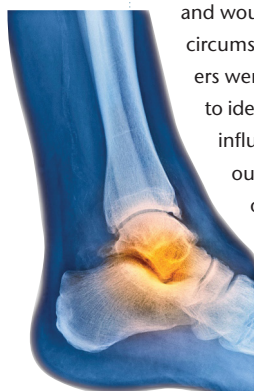
■ Patients with diabetes or obesity, as well as the elderly, are becoming more and more common in the orthopaedic outpatient department. Patients who fit into all three of these categories often have diabetic foot ulcers which can be challenging to treat. Surgical options are often limited to amputation or revascularisation in those with concomitant vascular disease. A paper that piqued our interest at 360 this month examines the use of selective plantar fascia release to alter the foot biomechanics and offload the ulcer. Researchers in **Seoul (South Korea)** reasoned that as Achilles tendon lengthening decreases plantar pressures, leading to resolution of forefoot ulceration at the cost of up to a 30% complication rate, they developed a new technique, selective plantar fascia release, as an alternative to Achilles tendon lengthening for managing these forefoot ulcers. The research team report a prospective cohort series (Level III evidence) of patients managed with the new technique. They describe a selective plantar fascia release, and recorded wound healing data, and pre- and post-operative range of movement of the operated metatarsophalangeal joint. They report the results of 60 patients followed-up for two years. The authors achieved a healing rate of 56% at six weeks, accompanied by an increased range of movement from 15° to 30° dorsiflexion. The researchers noted that the ulcers healed in all

patients in whom the pre-operative dorsiflexion was restricted to less than 30° and in whom the post-operative range of movement of that joint increased by at least 13°. Impressively, the authors noted no ulcer recurrence or complications associated with the selective plantar fascia release.<sup>4</sup> 360 was delighted to read this gem of a paper describing a new surgical technique, with long-term follow-up, and describing predictors of success. Although a 56% healing rate is not huge in the established non-healing ulcer, a small procedure without major complications is a welcome addition to a surgeon's armamentarium.

### Does removal of metalwork resolve foot pain?

■ Patients returning after apparently successful surgery, but complaining of pain over the operative site can be a difficult group to treat. Without obviously prominent metalwork, here at 360 we are often at a loss to explain the origin of the pain. Soft-tissue scarring, incisional scarring, infection or symptomatic metalwork are all possible. Often (we're sure like many others) we offer the patient metalwork removal but have never been certain if the risks outweigh the benefits. A research team from **Baltimore (USA)** set out to establish if patients complaining of apparently idiopathic post-operative foot and ankle pain would benefit from removal of their metalwork. The research group selected a prospective series of patients undergoing elective removal of their metalwork and carried out a prospective cohort study (Level III evidence). They evaluated the patients using a satisfaction score and the McGill pain score pre- and post-operatively. Final follow-up was at six weeks post-intervention. The investigators report on the results of 69 patients who, on average,

reported significantly reduced levels of pain and pain intensity. The pain scores fell from 3.06 to 0.88 for overall pain rating and from 2.03 to 0.53 for pain intensity. Perhaps more reassuringly, 65% of patients reported no pain at all after the procedure. There was in general a high level of satisfaction in those patients undergoing removal of metalwork with over 90% of patients reporting they were satisfied with the procedure and would repeat it in the same circumstances.<sup>5</sup> The researchers were unfortunately unable to identify any factors that influenced post-operative



outcome, such as intensity of pain, location of metalwork, age, gender, etc. Although sparse, we will find the information in this study to be of great use in the consulting room when counselling patients. What is disappointing is that the investigators were unable to tell us which 65% of patients would be cured by the surgery. We wonder if increasing the sample size might help with answering the most important question: whose metalwork should we offer to remove?

### Allgrafting of osteochondral lesions

■ Moving back into the arena of new and emerging surgical techniques, researchers in **Toronto (Canada)** have been performing bulk allografts for treatment of large osteochondral lesions of the talus. With a great many treatments available for every joint in the body from microfracture to chondrocyte implantation, scaffolds, growth factors, platelet-rich plasma, autografting and allografting, we have been watching the evaluation of the evolving technologies here at 360 with interest. We have always treated allografting with a small measure of suspicion as although it reduces the risk of donor-site morbidity it introduces the risk of rejection, and still suffers the drawbacks of mismatch and

fixation failure. We were heartened to see a scientific investigation of the results. The authors investigated the outcomes of 16 patients (17 ankles) who underwent surgery for large osteochondral defects with bulk osteochondral allograft. Outcomes were assessed using a complete range of outcome measures including the Ankle Osteoarthritis Scale (AOS), Short Form-36 (SF-36), American Academy of Orthopaedic Surgeons (AAOS) Foot and Ankle Module, and the American Orthopaedic Foot & Ankle Society (AOFAS) hindfoot scale scores. Additional data were collected from post-operative CT scans and radiographs. The investigators followed up the patients over a four-year period and during that time nearly 30% of ankles were considered a surgical failure. There was minimal graft incorporation (two ankles), worrying rates of osteolysis (five ankles), subchondral cysts (eight ankles), and degenerative changes (seven ankles). The authors reported improvement in some scores, but no changes in AOS Pain, AAOS Foot and Ankle Shoe Comfort Scale, or SF-36 scores.<sup>6</sup> Despite these results the authors conclude that ten patients had a good or excellent result. This causes us to stop and think, at 360, how we define a good or excellent result; the authors report only four patients were symptom free, two required re-operation and five had failed. Not quite the good or excellent results to which we have become accustomed in modern orthopaedic surgery.

### Distraction for osteoarthritis

■ Here at 360 we always find randomised controlled trials a welcome read. It is a testament to the hard work and tenacity of orthopaedic researchers around the world that so much Level I evidence has become available in orthopaedic and trauma surgery during the last few years. Designing and implementing randomised controlled trials of surgical interventions is many times more demanding and time consuming than doing the same in many other medical fields. We were particularly

intrigued to read this paper describing one such trial for joint distraction as a treatment for osteoarthritis. Researchers in **Iowa City (USA)** hypothesised that as there are some initial reports of fixed distraction as a treatment for osteoarthritis of the ankle joint (and indeed, elsewhere in the orthopaedic literature in the elbow), an articulated distractor could potentially see the same benefit without the drawback of stiffness from extended immobilisation. The researchers designed a randomised controlled trial to establish if mobile distraction or static distraction were better when combined with cheilectomy (osteophyte removal) for ankle osteoarthritis. The research team recruited 36 patients who were randomised to treatment with either fixed distraction or distraction with motion after cheilectomy of their osteoarthritic ankle. The patients were followed within the study for two years and the Ankle Osteoarthritis Scale (AOS) was the primary outcome measure. Patients in both groups showed significantly improved AOS scores after two years of follow-up as compared with pre-operatively. Additionally, the patients randomised to the articulated distraction group had significantly

better AOS scores at 26 weeks, and at one and two years. At two years the articulated distraction group had an overall mean improvement of 56.6% in the AOS score compared with 22.9%. The researchers concluded that adding ankle movement to distraction improved outcomes.<sup>7</sup> Despite the advantages of randomised controlled trials, sometimes the narrowness of the research question being posed can be disadvantageous. While we were delighted at 360 to learn from this study that if we were to use ankle distraction we should use an articulated device, we are still none the wiser as to whether we should use ankle distraction at all. A third arm of patients undergoing just cheilectomy is essential if any meaningful conclusions can be drawn regarding the overall benefit of distraction.

#### **Ultrasound-guided minimally invasive surgery – a new toy**

■ Orthopaedic surgeons the world over are great innovators, forever designing new surgical techniques or new ways to use old technologies. Surgeons in **Taipei (Taiwan)** have pioneered a new technique to improve minimally invasive Achilles tendon surgery. The technique

reduces wound complications while ensuring the sural nerve remains uninjured. Cunning, we thought at 360, and even more promisingly they have reported their technique and a series of outcomes. The researchers recruited 23 patients into a prospective comparative cohort series (Level II evidence). All the patients presented with an isolated Achilles tendon rupture and underwent repair with an ultrasound-guided minimally invasive technique. A total of 23 patients who underwent the minimally invasive technique were compared with a control group of 25 patients who received traditional open Achilles tendon repair. The authors found no differences in the post-operative clinical results (as judged by the AOFAS score), but did note an improvement in the rates of infection and sural nerve injury in the minimally invasive group.<sup>8</sup> While the jury is still out as to the benefit of operative repair, as described in an earlier paper, this study certainly raises an eyebrow or two here at 360. Perhaps for once it is possible to have one's cake and eat it. Ultrasound-guided surgery may allow for the functional benefits of operative repair without the high rate of surgical complications. Time will tell.

#### **REFERENCES**

1. **Schuh R, Hofstaetter J, Krismer M, et al.** Total ankle arthroplasty versus ankle arthrodesis: comparison of sports, recreational activities and functional outcome. *Int Orthop* 2012;36:1207-1214.
2. **Bianchi A, Martinelli N, Sartorelli E, Malerba F.** The Bologna–Oxford total ankle replacement: a mid-term follow-up study. *J Bone Joint Surg [Br]* 2012;94-B:793-798.
3. **Wilkins R, Bisson LJ.** Operative versus nonoperative management of acute Achilles tendon ruptures: a quantitative systematic review of randomized controlled trials. *Am J Sports Med* 2012;40:2154-2160.
4. **Kim JY, Hwang S, Lee Y.** Selective plantar fascia release for nonhealing diabetic plantar ulcerations. *J Bone Joint Surg [Am]* 2012;94-A:1297-1302.
5. **Williams AA, Witten DM, Duester R, Chou LB.** The benefits of implant removal from the foot and ankle. *J Bone Joint Surg [Am]* 2012;94-A:1316-1320.
6. **Haene R, Qamirani E, Story RA, Pinsker E, Daniels TR.** Intermediate outcomes of fresh talar osteochondral allografts for treatment of large osteochondral lesions of the talus. *J Bone Joint Surg [Am]* 2012;94-A:1105-1110.
7. **Saltzman CL, Hillis SL, Stolley MP, Anderson DD, Amendola A.** Motion versus fixed distraction of the joint in the treatment of ankle osteoarthritis: a prospective randomized controlled trial. *J Bone Joint Surg [Am]* 2012;94-A:961-970.
8. **Wang CC, Chen PY, Wang TM, Wang CL.** Ultrasound-guided minimally invasive surgery for achilles tendon rupture: preliminary results. *Foot Ankle Int* 2012;33:582-590.