



■ KNEE

Release of the tourniquet immediately after the implantation of the components reduces the incidence of deep vein thrombosis after primary total knee arthroplasty

**P. Zan,
M. O. Mol,
J. J. Yao,
L. Fan,
D. Yang,
K. Liu,
G. Li**

Shanghai Tenth
People's Hospital
affiliated to Tongji
University, Shanghai,
China

■ P. Zan, MD, Orthopaedic Surgeon, Department of Orthopaedic Surgery,
■ L. Fan, MD, Orthopaedic Surgeon, Department of Orthopaedic Surgery,
■ D. Yang, MD, Orthopaedic Surgeon, Department of Orthopaedic Surgery,
■ K. Liu, MD, Orthopaedic Surgeon, Department of Orthopaedic Surgery,
■ G. Li, MD, Orthopaedic Surgeon, Department of Orthopaedic Surgery, Tongji University, Shanghai Tenth People's Hospital, Zhabei Qu, Shanghai 200085, China.
■ M. O. Mol, MD, Medical doctor, Academic Medical Centre (AMC), University of Amsterdam, Meibergdreef 9, 1105 AZ Amsterdam-Zuidoost, The Netherlands.
■ J. J. Yao, BA, Orthopedic Surgeon, Department of Orthopedic Surgery, University of Texas Southwestern Medical Center, 5323 Harry Hines Boulevard, Dallas, Texas, USA.

Correspondence should be sent to G. Li; email: litrue2004@163.com

doi: 10.1302/2046-3758.69.BJR-2017-0149.R2

Bone Joint Res 2017;6:535–541.

Received: 25 May 2017;

Accepted: 9 August 2017

Objectives

The length of the tourniquet time during total knee arthroplasty (TKA) is related to the incidence of post-operative deep vein thrombosis (DVT). Our aim in this study was to investigate the effect of the early release of the tourniquet on the incidence of DVT in patients undergoing TKA.

Methods

A total of 200 patients who underwent TKA between November 2015 and November 2016 were prospectively enrolled. The tourniquet was inflated before surgery and released immediately after the introduction of the components (early release group). This group was compared with a retrospective cohort of 200 primary TKAs, in which the tourniquet was released after the dressings had been applied (late release group). The presence of a DVT was detected using bilateral lower limb ultrasonography. Peri-operative clinical and follow-up data were collected for analysis.

Results

The incidence of DVT in the early release group (9 of 196, 4.6%) was significantly lower compared with the late release group (24 of 200, 12%; odds ratio (OR) 0.35, 95% confidence interval (CI) 0.16 to 0.78, $p = 0.008$). The incidence of proximal DVT in the early release group (1 of 196 (0.5%)) was significantly lower than in the late release group (8 of 196, 4%; OR 0.12, 95% CI 0.02 to 0.99, $p = 0.020$). Although the mean intra-operative blood loss was higher in the early release group, the mean post-operative drainage, total blood loss, transfusion requirements and complications were not significantly different in the two groups.

Conclusion

In patients who undergo TKA, releasing the tourniquet early is associated with a decreased incidence of DVT, without increasing the rate of complications.

Cite this article: *Bone Joint Res* 2017;6:535–541.

Keywords: Total knee arthroplasty, Tourniquet, Deep vein thrombosis, Blood loss

Article focus

- The duration of application of a tourniquet is related to the incidence of deep vein thrombosis (DVT) following total knee arthroplasty (TKA).
- We examined the effect of releasing the tourniquet immediately after introducing the components on the incidence of DVT in a series of TKAs.

Key messages

- There was a reduced incidence of DVT in patients in whom the tourniquet was released early.
- Other clinical outcomes were non inferior with this earlier tourniquet release strategy.

Strengths and limitations

- Strengths: This was a comparative cohort study, the associated surgical and clinical

factors were controlled effectively, and this is the first study to investigate the relationship between the timing of release of the tourniquet and the incidence of DVT following TKA.

- Limitations: None of the patients received chemoprophylaxis for DVT; there was no long-term follow-up and some patients may have developed a DVT after the time of final assessment, three months post-operatively.

Introduction

Total knee arthroplasty (TKA) is a successful, safe, and cost-effective procedure for reducing pain and restoring function in patients with severe osteoarthritis and rheumatoid arthritis affecting the knee.^{1,2} Venous thromboembolism (VTE), including both deep vein thrombosis (DVT) and pulmonary embolism (PE), is associated with significant post-operative morbidity and mortality.³ Although a DVT can occur throughout a deep vein, thrombi usually form distally within the deep veins of the lower limb. A thrombus can extend proximally or break off and travel to the lungs, causing a PE.⁴ The rate of DVT following TKA is high and DVT is associated with a large clinical and economic burden.⁵⁻⁷

A tourniquet is commonly used during TKA as it improves visualisation, shortens the operating time and decreases intra-operative bleeding, thus ensuring better cementation.⁸⁻¹¹ However, the complications of using a tourniquet include wound dehiscence, swelling of the leg, oozing, infection, and DVT.¹²⁻¹⁴ Although highly debated for many years, tourniquets remain widely used in orthopaedic surgery. Recent studies have focused on how to further optimise their use in TKA.¹⁵⁻¹⁸ An increased length of tourniquet time may increase the risk of DVT due to increased venous stasis and potential damage to calcified vessels inducing an inflammatory stimulus.¹⁹ We undertook a study to detect the effect of the release of the tourniquet immediately after implantation of the components on the incidence of DVT after primary TKA. The hypothesis was that patients treated with release of the tourniquet at this time would have a reduced incidence of DVT compared with those in whom the tourniquet was released after applying the dressings.

Patients and Methods

This study was a combined prospective and retrospective cohort study. Patients with osteoarthritis or rheumatoid arthritis who underwent unilateral primary TKA between November 2015 and November 2016 were considered for enrollment. Exclusion criteria included pre-operative signs of coagulopathy, such as abnormal coagulation test values or continuing anticoagulant treatment, poorly controlled diabetes mellitus or hypertension and a history of previous surgery to the knee.

All patients underwent TKA under the same laryngeal mask anaesthetic protocol. The lower limb was elevated to allow pooled blood to drain, after which the tourniquet was inflated to 250 mmHg. A standard procedure involving a posterior cruciate-substituting cemented prosthesis (Genesis II Oxinium; Smith & Nephew, Memphis, Tennessee) was performed by a senior surgeon (GL) using a longitudinal midline incision and a medial parapatellar approach. Peripheral femoral and tibial osteophytes were removed and intramedullary and extramedullary guides were used for preparation of the femur and tibia, respectively. After introduction of the components, the tourniquet was released and the wound was closed following irrigation and the injection of a single dose of morphine, bupivacaine and betamethasone, diluted by 60 ml of sterile normal saline into the soft tissues around the knee.²⁰ One drainage tube was used. This group of patients was compared with a retrospective cohort of 200 identical unilateral procedures undertaken by the same surgeon between March 2014 and October 2015, in which the tourniquet was not released until after the dressings were applied. Data for this group were obtained from the medical records using the same exclusion criteria as for the study group.

All patients received post-operative oral non-steroidal anti-inflammatory medication with celecoxib capsules (Pfizer, New York City, New York), 200 mg, once daily, except for those with contra-indications. None received chemical thromboprophylaxis. All were mobilised, using a routine physiotherapy protocol, on the first post-operative day after removal of the drainage tube. The criteria for blood transfusion were a serum level of haemoglobin of < 8 g/dL or symptomatic anaemia at a level of < 10 g/dL. All patients underwent ultrasonography with ultrasound (Philips iU22, Amsterdam, The Netherlands) of both lower limbs by physicians who were blinded to the tourniquet strategy that had been used, between five and seven days post-operatively. A thrombus located above the knee including one in the iliac, femoral, superficial or deep saphenous and popliteal vein was defined as a proximal DVT. One located below the knee, in the anterior or posterior tibial, peroneal, soleal vein or small tertiary vessels was defined as a distal DVT. A multi-vein thrombus was assigned as proximal or distal based upon the larger vein that was involved.

Various baseline demographic characteristics and intra- and post-operative data were extracted for analysis. All patients were reviewed at least three months post-operatively. Those who had developed a DVT during their admission underwent further ultrasonography of both lower limbs one and three months post-operatively. The blood loss, including the volume of intra-operative suction and post-operative drainage and the requirement for transfusion, were recorded. The blood loss was calculated as described by Gross,²¹ using the difference between the

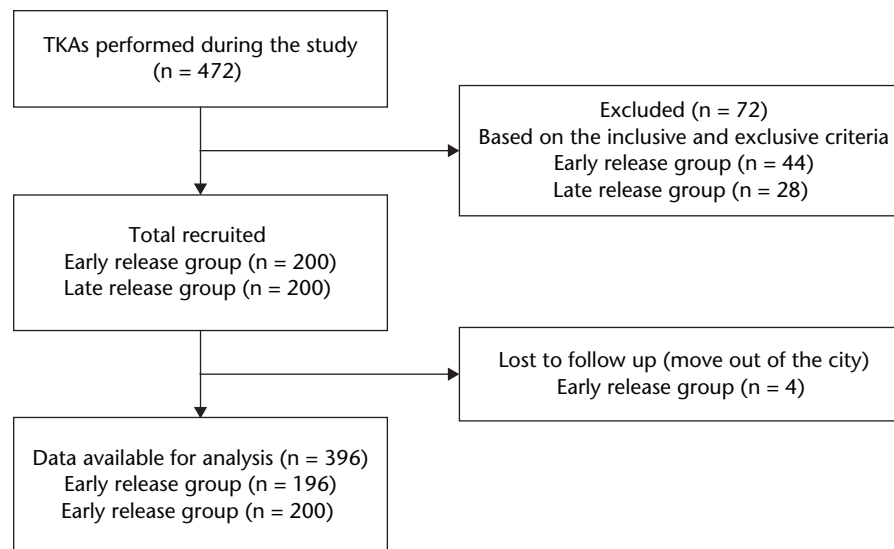


Fig. 1

Patients' flow diagram (TKA, total knee arthroplasty).

Table I. The demographics of the patients

Parameters	Early release group (n = 196) (mean, sd)	Late release group (n = 200) (mean, sd)	Mean difference (95% CI)	p-value
Age (yrs)	69.4 (7.2)	68.6 (8.1)	0.8 (-3.77 to 5.34)	0.674*
Left/right (n)	102, 94	113, 87	N/A	0.373†
Male/female (n)	84, 112	79, 121	N/A	0.497†
BMI (kg/m ²)	25.7 (2.2)	26.1 (1.9)	-0.4 (-1.80 to 1.06)	0.451*
Diagnosis (OA or RA)	189, 7	191, 9	N/A	0.639†
Haemoglobin level (g/L)	131.2 (11.3)	129.7 (12.7)	1.5 (-4.46 to 7.46)	0.682*
Tourniquet time (mins)	47.6 (7.8)	71.2 (10.8)	-23.6 (-25.55 to -21.72)	< 0.001*‡
Operating time (mins)	73.3 (11.4)	71.2 (10.8)	2.1 (-1.05 to 5.24)	0.152*
Intra-operative blood loss (ml)	177.4 (37.2)	117.6 (39.4)	59.8 (52.33 to 67.42)	< 0.001*‡
Post-operative drainage volume (ml)	301.2 (44.7)	296.4 (39.5)	4.8 (-8.34 to 17.94)	0.466*
Calculated blood loss (ml)	907.4 (237.5)	894.9 (188.2)	12.5 (-10.73 to 35.73)	0.232*
Blood transfusion (patients)	9	11	N/A	0.680†

*Student's *t*-test

†chi-squared test

‡Statistically significant

BMI, body mass index; OA, osteoarthritis; RA, rheumatoid arthritis; Hb, haemoglobin; CI, confidence interval; N/A, not applicable

level of haemoglobin or haematocrit pre-operatively and on the first post-operative day (15 to 24 hours), accounting for the height and weight of the patient and using a correction factor for gender. The bleeding-related outcomes, and the tourniquet time and operating time, were considered as secondary outcomes.

The study had ethical approval and all patients gave informed consent.

Statistical analysis. Data analysis was performed using standard statistical software (SPSS, version 22.0, 2013, IBM Corp, Armonk, New York). Categorical variables were presented as absolute numbers and relative frequencies, of which the chi-squared test was used to test the differences as shown using odds ratios (OR) and corresponding 95% Confidence Intervals (CIs). Continuous variables were presented as the mean and standard deviation (SD). The Student's *t*-test was used to investigate parametric data, these data are presented with mean

difference and 95% CI. Results were considered significant with *p*-values < 0.05.

Results

A total of 472 patients with primary unilateral TKAs in the combined prospective and retrospective cohorts were identified. A total of 72 patients, 44 in the early release group and 28 patients in the late release group, were excluded. An intended total of 400 patients were recruited for this trial. The date of the final follow-up was 16 February 2017. Four patients in the prospective cohort who were lost to follow-up were excluded, leaving 196 in the prospective early release group and 200 in the retrospective late release group for the final analysis. A flow-diagram is shown in Figure 1. The groups were matched based on the following pre-operative characteristics: age, side of TKA, gender, BMI, diagnosis, and pre-operative level of haemoglobin (Table I).

Table II. Details of patients who had a deep vein thrombosis (DVT)

Patient (n)	Group	Gender	Age (yrs)	BMI	Tourniquet time (mins)	Operation time (mins)	Thrombus location	Treatment
1	ERG	Female	73	26.5	57	79	Right posterior tibial and peroneal veins	None
2	ERG	Male	75	27.4	48	73	Left posterior tibial vein	None
3	ERG	Female	68	24.8	51	71	Right soleal vein	None
4†	ERG	Female	76	25.1	56	74	Right femoral vein	Rivaroxaban
5	ERG	Male	67	27.1	53	81	Left peroneal vein	None
6	ERG	Female	78	23.7	55	77	Left posterior tibial and peroneal veins	None
7	ERG	Female	81	25.6	52	75	Left posterior tibial vein	None
8	ERG	Female	77	27.4	53	78	Right peroneal and soleal veins	None
9	ERG	Male	83	26.9	49	73	Left posterior tibial vein	None
10	LRG	Female	76	27.1	71	71	Left peroneal vein	None
11†	LRG	Female	68	28.4	69	69	Left popliteal vein	Rivaroxaban
12	LRG	Female	64	24.7	75	75	Right posterior tibial vein	None
13*†	LRG	Male	59	26.3	73	73	Left femoral vein and peroneal vein	Rivaroxaban
14	LRG	Male	66	26.1	81	81	Right anterior tibial vein	None
15	LRG	Female	75	24.8	68	68	Left peroneal veins	None
16†	LRG	Female	71	25.3	67	67	Left great saphenous vein	Rivaroxaban
17	LRG	Male	84	27.8	74	74	Right peroneal vein and soleal veins	None
18	LRG	Female	81	26.2	71	71	Left peroneal vein and small vessels	None
19	LRG	Male	69	28.1	84	84	Right femoral vein	None
20†	LRG	Female	73	26.3	77	77	Left popliteal vein and small vessels	Rivaroxaban
21	LRG	Female	78	24.7	72	72	Right posterior tibial vein	None
22	LRG	Female	67	23.9	69	69	Right peroneal vein	None
23†	LRG	Male	77	26.6	75	75	Left femoral and posterior tibial veins	Rivaroxaban
24†	LRG	Female	73	28.8	83	83	Left femoral vein	Rivaroxaban
25	LRG	Male	68	22.9	74	74	Right posterior tibial and peroneal veins	None
26	LRG	Male	81	27.3	71	71	Left peroneal vein	None
27*†	LRG	Female	83	28.3	66	66	Right femoral and popliteal veins	Rivaroxaban
28	LRG	Female	69	26.2	84	84	Right posterior tibial vein	None
29	LRG	Male	75	25.9	71	71	Left posterior tibial vein and small vessels	None
30†	LRG	Male	71	24.7	69	69	Left femoral vein and small vessels	Rivaroxaban
31†	LRG	Female	69	25.7	88	88	Left popliteal vein	Rivaroxaban
32	LRG	Female	77	26.8	81	81	Right peroneal vein	None
33	LRG	Female	79	25.9	73	73	Right posterior tibial and peroneal veins	None

*proximal DVT

†symptomatic DVT

ERG, early release group; LRG, late release group; BMI, body mass index

The mean tourniquet time was significantly shorter in the early release group (47.6 minutes, SD 7.8) than in the late release group (71.2 minutes, SD 10.8; mean difference = -23.6, 95% CI -25.55 to -21.72, $p < 0.001$). The mean operating time in the two groups was not significantly different: early release group (73.3 minutes, SD 11.4); late release group (71.2 minutes, SD 10.8; mean difference = 2.1, 95% CI -1.05 to 5.24, $p = 0.152$). The mean intra-operative blood loss was significantly greater in the early release group (177.4 ml, SD 37.2) compared with the late release group (117.6 ml, SD 39.4; mean difference = 59.8, 95% CI 52.33 to 67.42, $p < 0.001$). The mean volume of post-operative drainage, total blood loss and transfusion requirement in the two groups were not significantly different (Table I).

Two patients in the late release group developed a symptomatic proximal DVT with progressive swelling of the operated limb on the third and fourth post-operative day, respectively. These were identified at the time of the ultrasonography. The total incidence of proximal post-operative DVT was 0.5% ($n = 1$) in the early release group and 4% ($n = 8$) in the late release group; this difference was significant (odds ratio (OR) 0.12, 95% CI 0.02 to

0.99, $p = 0.02$). The incidence of distal DVT was 4.1% ($n = 8$) in the early release group and 8% ($n = 16$) in the late release group; this difference was not significant (OR 0.49, 95% CI 0.21 to 1.17, $p = 0.102$). The total number of patients with a DVT was significantly higher in the late release group (12%, $n = 24$) than in the early release group (4.6%, $n = 9$; OR 0.35, 95% CI 0.16 to 0.78, $p = 0.008$).

Patients with a proximal DVT were treated with rivaroxaban (15mg twice a day for 21 days and then 20 mg daily). Those with a distal DVT were not treated with anticoagulants on the advice of a haematologist. All patients with a DVT underwent further ultrasonography at the time of the review, one and three months post-operatively. Rivaroxaban treatment continued for one month if the thrombus had resolved on ultrasound at that time. Treatment continued for three months in total if it had not. The thrombus had resolved one month post-operatively in one patient in the early release group and three in the late release group with a proximal DVT. Three patients with an asymptomatic proximal DVT in the late release group and two patients in this group with a symptomatic proximal DVT had complete resolution of

Table III. Summary of the complications

Parameters	Early release group (n = 196)	Late release group (n = 200)	OR (95% CI)	p-value
Total DVT† (n)	9	24	0.35 (0.16 to 0.78)	0.008*
Proximal DVT (n)	1	8	0.12 (0.02 to 0.99)	0.020*
Distal DVT (n)	8	16	0.49 (0.21 to 1.17)	0.102
Total complications‡ (n)	13	18	0.72 (0.34 to 1.51)	0.381
Symptomatic DVT (n)	0	2	0.20 (0.01 to 4.24)	0.160
Wound drainage (n)	6	3	2.07 (0.51 to 8.41)	0.297
Skin tension blister (n)	3	8	0.37 (0.10 to 1.43)	0.135
Marginal necrosis (n)	1	2	0.51 (0.05 to 5.64)	0.574
Superficial infection (n)	2	3	0.68 (0.11 to 4.10)	0.669
Deep infection (n)	1	0	3.08 (0.12 to 75.99)	0.312

*Statistically significant difference

†Number of patients with proximal and distal DVT

‡Number of patients with symptomatic DVT plus those with other complications

OR, odds ratio; CI, confidence interval; DVT, deep vein thrombosis

p-values calculated using chi-squared test

the thrombus three months post-operatively. The thrombus had resolved completely in all patients with a distal DVT, three months post-operatively. The thrombus did not propagate further in any patient and no patient had a fatal PE. Detailed data is shown in Table II and Table III.

Excluding those with an asymptomatic DVT, 13 patients (6.6%) in the early release group had a complication of surgery. Six had wound drainage beyond one post-operative week, three had blistering of the skin, one had skin necrosis, two had a superficial infection and one had a deep infection. In comparison, 18 patients (9.0%) in the late release group a complication. Three had wound drainage beyond one post-operative week, eight had blistering of the skin, two had skin necrosis, three had a superficial infection and two had symptomatic DVTs. The difference in the rate of complications between the two groups was not significant (OR 0.72, 95% CI 0.34 to 1.51, $p = 0.381$).

Discussion

To our knowledge, this is the first study that assesses the effect of the timing of release of the tourniquet on the incidence of DVT following TKA. We found that early release was associated with a significantly reduced incidence of DVT, without a significant increase in the rate of other complications.

Most surgeons prefer to use a tourniquet during TKA, although the prevalence of peri-operative complications associated with its use has caused much controversy. Abdel-Salam et al²² reported an increased incidence of DVT as confirmed by venography, with the use of a tourniquet in TKA. Mori et al²³ found that the use of a tourniquet was associated with a significantly increased risk of distal DVT, as identified by ultrasound. Many authors have suggested that shortening the tourniquet time will reduce the disadvantages of its use, while preserving the advantages. In a retrospective study by Razak et al,²⁴ the incidence of a symptomatic DVT in patients was significantly related to a longer tourniquet time. One patient developed a PE with a tourniquet time of 160 minutes,

which was significantly longer than the mean tourniquet time for the whole series. Chung et al,²⁵ also reported that the rate of DVT appeared to be increased with a longer tourniquet time, probably due to a longer period of venous stasis and damage to calcified vessels. We have previously undertaken a meta-analysis on the early release of the tourniquet before wound closure and found a tendency to a decreased incidence of DVT with early release.¹⁹ With the current study, using relatively large prospective and retrospective cohorts, we found a significantly decreased incidence of DVT, identified by ultrasound, with early release of the tourniquet. Most DVTs were asymptomatic. There is evidence, however, that an asymptomatic post-operative DVT is associated with an increased risk of the late development of the post-thrombotic syndrome.^{26,27} Thus patients with an asymptomatic DVT should be monitored carefully, although they may not require chemical thromboprophylaxis. We also speculate that an increased rate of asymptomatic DVT may be related to the rate of symptomatic VTE following TKA.^{23,26,27}

Patients undergoing TKA are at a high risk of VTE. Guidelines from many national orthopaedic societies recommend the use of pharmacologic agents and/or mechanical compressive devices for the prevention of VTE in these patients.^{28,29} A lower incidence of VTE in Asian patients compared with Western patients undergoing TKA has also been reported,^{30,31} and many Asian centres do not routinely use thromboprophylaxis in TKA. A study from Singapore found that both the prevalence and incidence of symptomatic VTE in TKA in patients not receiving thromboprophylaxis was < 1%.^{24,32,33} Routine anticoagulation has risks. Sutherland et al³⁴ reported an incidence of 4% systemic complications and 12% of wound complications with the use of warfarin, and Chin et al³⁵ reported an incidence of bleeding complications of 11% with enoxaparin. Several other studies have also shown that the aggressive use of chemical prophylaxis is accompanied by complications such as delayed wound healing, haematoma and infection. These complications

may interfere with rehabilitation, prolong hospitalisation and require further surgery leading to an enhanced burden on society.³⁶⁻³⁹ We do not use routine thromboprophylaxis following TKA.

It is not clear whether these findings could be extrapolated to a Western cohort, in whom chemoprophylaxis is commonly used. There may be ways, by which the risk of DVT can be reduced other than by adjusting the tourniquet strategy or administering chemoprophylaxis. Several authors have reported a reduced risk using mechanical intermittent compression of the lower limbs after THA, TKA and Achilles tendon repair.^{40,41}

The incidence of symptomatic DVT was low, 0.5% (2 of 400), in this study, consistent with the incidence found in other Asian studies.^{24,32,33} The two patients in the late release group with a symptomatic DVT both had many thrombi, with thrombus in the left femoral vein and peroneal vein in the first patient, and in the right femoral and popliteal veins in the second. Some authors have suggested that a thrombus in the calf is unlikely to produce symptomatic VTE regardless of the size, and therefore anticoagulation is unnecessary.^{42,43} Kakkar et al⁴⁴ and Wang et al⁴⁵ also proposed that thrombi in the calf are attached securely and resolve rapidly and spontaneously. Parisi et al⁴⁶ found that only 2.9% of distal calf DVTs progressed proximally, and Schellong et al⁴⁷ stated that 80% to 90% of distal DVTs do not require anticoagulant treatment. In our study, anticoagulants were not given to patients with a distal DVT. Rivaroxaban was used for patients with a proximal DVT under the guidance of a haematologist. None of the patients developed a recurrent DVT, proximal propagation or a fatal PE. The symptoms in the two patients with a symptomatic DVT resolved following anticoagulant treatment, and the thrombus resolved completely in all patients with a DVT by three months post-operatively.

This study had limitations. First, the surgeons were not blinded to the tourniquet strategy, which may impose some bias. This lack of blinding is hard to avoid. However, the ultrasonographers were blinded to the tourniquet strategy. Secondly, the diagnostic accuracy of ultrasonography is not 100%, although it is widely accepted as an alternative method to venography for the diagnosis of a DVT.⁴⁸ Venography is invasive, involves the injection of contrast and is more expensive than ultrasound.⁴⁹⁻⁵¹ Thirdly, our study was performed in a single institution by a single surgeon. It is possible that our findings may not be generalisable to other patients, other centres or other surgeons. Our patients were all Asian with a mean BMI that was notably lower than that used in many studies involving Western patients. Further multicentre prospective trials are needed to determine whether our findings may be generalisable to other groups. Lastly, we did not routinely treat patients with chemoprophylaxis for DVT, which could have influenced the results. We did not report any clinical outcome data, such as the Oxford

Knee Score.⁵² Additionally, there was no long-term follow-up. Some patients may have developed a DVT after the ultrasound examination or after the review three months post-operatively. Although these potential limitations exist, the present study provides evidence that releasing the tourniquet immediately after introducing the components at TKA may reduce the risk of DVT while preserving the advantages of using a tourniquet and without increasing the rate of other complications.

References

1. Pulido L, Parvizi J, Macgibeny M, et al. In hospital complications after total joint arthroplasty. *J Arthroplasty* 2008;23(Suppl 1):139-145.
2. Losina E, Walensky RP, Kessler CL, et al. Cost-effectiveness of total knee arthroplasty in the United States: patient risk and hospital volume. *Arch Intern Med* 2009;169:1113-1121.
3. Anderson FA Jr, Wheeler HB, Goldberg RJ, et al. A population-based perspective of the hospital incidence and case-fatality rates of deep vein thrombosis and pulmonary embolism. The Worcester DVT Study. *Arch Intern Med* 1991;151:933-938.
4. Zhang H, Mao P, Wang C, et al. Incidence and risk factors of deep vein thrombosis (DVT) after total hip or knee arthroplasty: a retrospective study with routinely applied venography. *Blood Coagul Fibrinolysis* 2017;28:126-133.
5. Geerts WH, Pineo GF, Heit JA, et al. Prevention of venous thromboembolism: the Seventh ACCP Conference on Antithrombotic and Thrombolytic Therapy. *Chest* 2004;126(Suppl):338S-400S.
6. Shahi A, Chen AF, Tan TL, et al. The incidence and economic burden of in-hospital venous thromboembolism in the United States. *J Arthroplasty* 2017;32:1063-1066.
7. No authors listed. Cardiovascular Disease Educational and Research Trust, European Venous Forum, North American Thrombosis Forum, International Union of Angiology, Union Internationale de Phlebologie. Prevention and treatment of venous thromboembolism: international consensus statement (guidelines according to scientific evidence). *Clin Appl Thromb Hemost* 2013;19:116-118.
8. Tai T-W, Chang C-W, Lai K-A, Lin C-J, Yang C-Y. Effects of tourniquet use on blood loss and soft-tissue damage in total knee arthroplasty. *J Bone Joint Surg [Am]* 2012;94-A:2209-2215.
9. Tai T-W, Lin C-J, Jou I-M, et al. Tourniquet use in total knee arthroplasty: a meta-analysis. *Knee Surg Sports Traumatol Arthrosc* 2011;19:1121-1130.
10. Li B, Wen Y, Wu H, et al. The effect of tourniquet use on hidden blood loss in total knee arthroplasty. *Int Orthop* 2009;33:1263-1268.
11. Parvizi J, Diaz-Ledezma C. Total knee replacement with the use of a tourniquet: more pros than cons. *Bone Joint J* 2013;95-B(Suppl A):133-134.
12. Stroh DA, Johnson AJ, Mont MA, Bonutti PM. Excellent clinical outcomes in total knee arthroplasty performed without a tourniquet. *Surg Technol Int* 2011;21:189-193.
13. Reikerås O, Clementsen T. Time course of thrombosis and fibrinolysis in total knee arthroplasty with tourniquet application. Local versus systemic activations. *J Thromb Thrombolysis* 2009;28:425-428.
14. Alcelik I, Pollock RD, Sukeik M, et al. A comparison of outcomes with and without a tourniquet in total knee arthroplasty: a systematic review and meta-analysis of randomized controlled trials. *J Arthroplasty* 2012;27:331-340.
15. Yavarikia A, Amjad GG, Davoudpour K. The influence of tourniquet use and timing of its release on blood loss in total knee arthroplasty. *Pak J Biol Sci* 2010;13:249-252.
16. Heller S, Chen A, Restrepo C, Albert E, Hozack WJ. Tourniquet release prior to dressing application reduces blistering following total knee arthroplasty. *J Arthroplasty* 2015;30:1207-1210.
17. Chen S, Li J, Peng H, et al. The influence of a half-course tourniquet strategy on peri-operative blood loss and early functional recovery in primary total knee arthroplasty. *Int Orthop* 2014;38:355-359.
18. Tarwala R, Dorr LD, Gilbert PK, Wan Z, Long WT. Tourniquet use during cementation only during total knee arthroplasty: a randomized trial. *Clin Orthop Relat Res* 2014;472:169-174.
19. Zan PF, Yang Y, Fu D, Yu X, Li GD. Releasing of tourniquet before wound closure or not in total knee arthroplasty: a meta-analysis of randomized controlled trials. *J Arthroplasty* 2015;30:31-37.
20. Fu P, Wu Y, Wu H, et al. Efficacy of intra-articular cocktail analgesic injection in total knee arthroplasty—a randomized controlled trial. *Knee* 2009;16:280-284.
21. Gross JB. Estimating allowable blood loss corrected for dilution. *Anesthesiology* 1983;58:277-280.

22. **Abdel-Salam A, Eyres KS.** Effects of tourniquet during total knee arthroplasty. A prospective randomised study. *J Bone Joint Surg [Br]* 1995;77-B:250-253.
23. **Mori N, Kimura S, Onodera T, et al.** Use of a pneumatic tourniquet in total knee arthroplasty increases the risk of distal deep vein thrombosis: A prospective, randomized study. *Knee* 2016;23:887-889.
24. **Razak HRBA, Razak NFBA, Tan H-CA.** Prevalence of venous thromboembolic events is low in Asians after total knee arthroplasty without chemoprophylaxis. *J Arthroplasty* 2017;32:974-979.
25. **Chung LH, Chen WM, Chen CF, Chen TH, Liu CL.** Deep vein thrombosis after total knee arthroplasty in Asian patients without prophylactic anticoagulation. *Orthopedics* 2011;34:15.
26. **Siragusa S, Beltracchi C, Barone M, Piovella F.** Clinical course and incidence of post-thrombotic syndrome after profound asymptomatic deep vein thrombosis. Results of a transverse epidemiologic study. *Minerva Cardioangiol* 1997;45:57-66.
27. **Wille-Jørgensen P, Jørgensen LN, Crawford M.** Asymptomatic postoperative deep vein thrombosis and the development of postthrombotic syndrome A systematic review and meta-analysis. *Thromb Haemost* 2005;93:236-241.
28. **Mont MA, Jacobs JJ.** AAOS clinical practice guideline: preventing venous thromboembolic disease in patients undergoing elective hip and knee arthroplasty. *J Am Acad Orthop Surg* 2011;19:777-778.
29. **Haas SB, Barrack RL, Westrich G, Lachiewicz PF.** Venous thromboembolic disease after total hip and knee arthroplasty. *J Bone Joint Surg [Am]* 2008;90-A:2764-2780.
30. **Ruban P, Yeo S, Seow K, Tan S, Ng S.** Deep vein thrombosis after total knee replacement. *Ann Acad Med Singapore* 2000;29:428-433.
31. **Lee W-S, Kim K-I, Lee H-J, Kyung H-S, Seo S-S.** The incidence of pulmonary embolism and deep vein thrombosis after knee arthroplasty in Asians remains low: a meta-analysis. *Clin Orthop Relat Res* 2013;471:1523-1532.
32. **Tay K, Razak HRBA, Tan AHC.** Obesity and venous thromboembolism in total knee arthroplasty patients in an Asian population. *J Arthroplasty* 2016;31:2880-2883.
33. **Razak HRBA, Soon AT, Dhanaraj ID, Tan AHC.** Incidence of clinically significant venous thromboembolic events in Asian patients undergoing total knee arthroplasty without anticoagulation. *J Arthroplasty* 2012;27:1128-1132.
34. **Sutherland CJ, Schurman JR.** Complications associated with warfarin prophylaxis in total knee arthroplasty. *Clin Orthop Relat Res* 1987;219:158-162.
35. **Chin PL, Amin MS, Yang KY, Yeo SJ, Lo NN.** Thromboembolic prophylaxis for total knee arthroplasty in Asian patients: a randomised controlled trial. *J Orthop Surg (Hong Kong)* 2009;17:1-5.
36. **Francis CW, Ricotta JJ, Everts CM, Marder VJ.** Long-term clinical observations and venous functional abnormalities after asymptomatic venous thrombosis following total hip or knee arthroplasty. *Clin Orthop Relat Res* 1988;232:271-278.
37. **Chandrasekaran S, Ariaretnam SK, Tsung J, Dickison D.** Early mobilization after total knee replacement reduces the incidence of deep venous thrombosis. *ANZ J Surg* 2009;79:526-529.
38. **Sharfman ZT, Campbell JC, Mirocha JM, Spitzer AI.** Balancing thromboprophylaxis and bleeding in total joint arthroplasty: impact of eliminating enoxaparin and predonation and implementing pneumatic compression and tranexamic acid. *J Arthroplasty* 2016;31:1307-1312.
39. **Lynch JA, Baker PL, Polly RE, et al.** Mechanical measures in the prophylaxis of postoperative thromboembolism in total knee arthroplasty. *Clin Orthop Relat Res* 1990;260:24-29.
40. **Kakkos SK, Warwick D, Nicolaidis AN, Stansby GP, Tsolakis IA.** Combined (mechanical and pharmacological) modalities for the prevention of venous thromboembolism in joint replacement surgery. *J Bone Joint Surg [Br]* 2012;94-B:729-734.
41. **Domeij-Arverud E, Labruto F, Latifi A, et al.** Intermittent pneumatic compression reduces the risk of deep vein thrombosis during post-operative lower limb immobilisation: a prospective randomised trial of acute ruptures of the Achilles tendon. *Bone Joint J* 2015;97-B:675-680.
42. **Lotke PA, Steinberg ME, Ecker ML.** Significance of deep venous thrombosis in the lower extremity after total joint arthroplasty. *Clin Orthop Relat Res* 1994;299:25-30.
43. **Moser KM, LeMoine JR.** Is embolic risk conditioned by location of deep venous thrombosis? *Ann Intern Med* 1981;94:439-444.
44. **Kakkar V, Howe C, Flanc C, Clarke M.** Natural history of postoperative deep-vein thrombosis. *Lancet* 1969;294:230-233.
45. **Wang C-J, Wang J-W, Weng L-H, Hsu C-C, Lo C-F.** Outcome of calf deep-vein thrombosis after total knee arthroplasty. *J Bone Joint Surg [Br]* 2003;85-B:841-844.
46. **Parisi R, Visonà A, Camporese G, et al.** Isolated distal deep vein thrombosis: efficacy and safety of a protocol of treatment. Treatment of Isolated Calf Thrombosis (TICT) Study. *Int Angiol* 2009;28:68-72.
47. **Schellong SM.** Distal DVT: worth diagnosing? Yes. *J Thromb Haemost* 2007;5(Suppl 1):51-54.
48. **Kakale SB, Maaji SM, Aliyu SA.** Lower extremities Duplex-Doppler ultrasonography for the detection of suspected deep venous thrombosis: A preliminary report from Sokoto. *Asian J Med Sci* 2016;7:53-57.
49. **de Valois JC, van Schaik CC, Verzijlbergen F, et al.** Contrast venography: from gold standard to 'golden backup' in clinically suspected deep vein thrombosis. *Eur J Radiol* 1990;11:131-137.
50. **Sidhu P, Alikhan R, Ammar T, Quinlan D.** Lower limb contrast venography: a modified technique for use in thromboprophylaxis clinical trials for the accurate evaluation of deep vein thrombosis. *Br J Radiol* 2007;80:859-865.
51. **Huisman MV, Klok FA.** Diagnostic management of acute deep vein thrombosis and pulmonary embolism. *J Thromb Haemost* 2013;11:412-422.
52. **Murray DW, Fitzpatrick R, Rogers K, et al.** The use of the Oxford hip and knee scores. *J Bone Joint Surg [Br]* 2007 89-B:1010-1014.

Acknowledgement

- We appreciate the help from the nursing staff of the orthopaedic department and the ultrasonographers in our hospital.

Funding Statement

- This work was supported by the National Natural Science Foundation of China (NSFC), grant number (81572632).

Author Contribution

- P. Zan, MD: Conception; Study design, Data collection and analysis, Drafting the article.
- M. O. MoI, MD: Drafting the article, Language editing.
- J. J. Yao, BA: Data analysis, Language editing.
- L. Fan, MD: Data collection, Drafting the article.
- D. Yang, MD: Data Collection.
- K. Liu, MD: Data Collection.
- G. Li, MD: Conception and study design, Final approval.

Conflicts of Interest Statement

- None declared

© 2017 Zan et al. This is an open-access article distributed under the terms of the Creative Commons Attribution licence (CC-BY-NC), which permits unrestricted use, distribution, and reproduction in any medium, but not for commercial gain, provided the original author and source are credited.