

■ **KNEE**

The medial and lateral epicondyle as a reliable landmark for intra-operative joint line determination in revision knee arthroplasty

**B. Ozkurt,
T. Sen,
D. Cankaya,
S. Kendir,
K. Basarir,
Y. Tabak**

Ankara University
School of Medicine
Anatomy Department,
Ankara, Turkey

■ B. Ozkurt, MD, Associate Professor,
■ D. Cankaya, MD, Staff Surgeon,
■ Y. Tabak, MD, Associate Professor,
Orthopaedic Department, Ankara Numune Research and Training Hospital, Talatpasa Bulvarı Samanpazarı Ankara, Turkey
■ T. Sen, MD, Associate Professor, School of Medicine Anatomy Department,
■ S. Kendir, MD, Medical Doctor, School of Medicine Anatomy Department,
■ K. Basarir, MD, Associate Professor, School of Medicine Anatomy Department
Ankara University, Sıhhiye Ankara, Turkey

Correspondence should be sent to Mr B. Ozkurt; email: bulentozkurt@hotmail.com

doi: 10.1302/2046-3758.57.BJR-2016-0002.R1

Bone Joint Res 2016;5:280–286.
Received: 29 March 2016;
Accepted: 9 May 2016

Objectives

The purpose of this study was to develop an accurate, reliable and easily applicable method for determining the anatomical location of the joint line during revision knee arthroplasty.

Methods

The transepicondylar width (TEW), the perpendicular distance between the medial and lateral epicondyles and the distal articular surfaces (DMAD, DLAD) and the distance between the medial and lateral epicondyles and the posterior articular surfaces (PMAD, PLAD) were measured in 40 knees from 20 formalin-fixed adult cadavers (11 male and nine female; mean age at death 56.9 years, SD 9.4; 34 to 69). The ratios of the DMAD, PMAD, DLAD and PLAD to TEW were calculated.

Results

The mean TEW, DMAD, PMAD, DLAD and PLAD were 82.76 mm (standard deviation (SD) 7.74), 28.95 mm (SD 3.3), 28.57 mm (SD 3), 23.97 mm (SD 3.27) and 24.42 mm (SD 3.14), respectively. The ratios between the TEW and the articular distances (DMAD/TEW, DLAD/TEW, PMAD/TEW and PLAD/TEW) were calculated and their means were 0.35 (SD 0.02), 0.34 (SD 0.02), 0.28 (SD 0.03) and 0.29 (SD 0.03), respectively.

Conclusion

This method provides a simple, reproducible and reliable technique enabling accurate anatomical joint line restoration during revision total knee arthroplasty.

Cite this article: *Bone Joint Res* 2016;5:280–286.

Keywords: Knee; Joint line; Arthroplasty; Cadaver; Revision arthroplasty

Article focus

■ This study was planned to create a reliable method which can be applied easily to determine the joint line during revision knee arthroplasty.

Key messages

■ There is a significant correlation between the DMAD and TEW, PMAD, DLAD and PLAD, enabling exact localisation of the joint line in relation to both distal and posterior articular surfaces.

Strengths and limitations

■ This technique allows easy and accurate determination of both distal and posterior anatomical joint lines.

■ The limitation of the study is that it is only useful in cases with intact epicondyles.

Introduction

Precise anatomical positioning of the bones of the knee and their adjacent soft tissues is essential for normal knee kinematics. Alterations of the joint line during revision total knee arthroplasty (TKA) have a significant negative impact on patellar biomechanics, retropatellar pressure, patellar pain, strength of the extensor mechanism, and range of movement (ROM).^{1,2}

Revision TKA is a sophisticated surgical procedure that requires a detailed understanding of the biomechanical relationship between the soft-tissue and bony components of the

joint to achieve optimal knee kinematics.³ The difficulties inherent in restoring the anatomical joint line during revision surgery may impair the results.⁴ Perfect knee function requires an exact balance between the bony anatomy and the adjacent soft tissues, and that balance is disrupted when the joint line is altered.⁵ Alteration of the joint line has negative effects on both patellofemoral and tibiofemoral kinematics and function.⁶ Contact between the tibia and the inferior pole of the patella or the patellar tendon as a result of joint line elevation may result in accelerated wear, weakness of the quadriceps, anterior knee pain, structural tendon damage, and limited knee flexion.⁷ A 5 mm alteration in the position of the joint line limits knee flexion and increases the stress on the patellofemoral joint, potentially resulting in subluxation, dislocation, chondromalacia, anterior knee pain or fracture and varus-valgus laxity.^{5,8} There are significant correlations between joint line elevation and patient satisfaction, pain, ROM and knee scores.³

The importance of joint line restoration in revision TKA is well accepted. Intra-operative determination of the anatomical joint line during revision TKA is difficult, and there is no generally accepted method to determine the joint line location pre-operatively. Numerous bony reference points that may aid in determination of the joint line have been identified and include the distance from the adductor tubercle, or epicondyles, to the distal articular surface of the distal femur; the lateral flare of the distal femur relative to the joint line; and the inferior patellar pole, the tip of the fibular head and the tibial tuberosity relative to the joint line.^{2,5} However, there is no consensus in terms of radiological pre-operative planning.

The main question is whether exact restoration of the joint line can be achieved in knee arthroplasty, especially in revision TKA. Recently, some reproducible methods which are easily performed intra-operatively, such as the adductor tubercle ratio, have been reported. This issue still remains an object of interest.⁹⁻¹¹ The present study aimed to identify an accurate, reliable and easily performed standardised method for determining the correct anatomical position of the joint line intra-operatively during revision TKA. The hypothesis was that a ratio could be determined based on the distal and posterior articular distances from the epicondyles to indicate the imaginary borders of the distal femur and the level of the joint line in revision TKA, and therefore enable an accurate decision regarding the size and location of the femoral component.

Material and Methods

The transepicondylar width (TEW), the distance from the medial epicondyle to both the distal and posterior articular joint lines, and the distance from the lateral epicondyle to both the distal and posterior articular joint lines were measured in 40 knees from 20 formalin-fixed adult cadavers. In total, 11 male and nine female cadavers were

used for this study and their mean age at death was 56.9 years (SD 9.4; 34 to 69). None of the cadavers had evidence of joint disease, previous knee operations, inflammatory disease, osteoarthritis, infections or fractures around the knee, or abnormalities associated with neuromuscular disorders. Two investigators (orthopaedic surgeons; BO, DC) independently measured all 40 knees. All measurements were taken twice with an interval of seven days between them.

The legs were removed from the cadavers at the hip. The knees were exposed using the same procedure as for TKA. Midline skin incisions and medial parapatellar arthrotomies were performed and the menisci were mobilised from the joint capsules when necessary. Synovial membranes over the medial and lateral epicondyles were excised to the layer of the medial and lateral collateral ligaments to facilitate identification of the most prominent point of the medial and lateral epicondyles.

TEW was defined as the distance between the most prominent points of the medial and lateral epicondyles at the centre of the insertions of the medial and lateral collateral ligaments. Distal medial articular distance (DMAD) and distal lateral articular distance (DLAD) were defined as the perpendicular distance from the most prominent points at the centre of the insertions of the medial and lateral collateral ligaments, to the distal joint lines/distal articular surfaces of the medial and lateral condyles parallel to the anatomical axis of the femur in the sagittal plane, respectively. The posterior medial articular distance (PMAD) and posterior lateral articular distance (PLAD) were defined as the distance between the most prominent points of the medial and lateral epicondyles and the posterior joint lines/posterior articular surfaces of the medial and lateral condyles perpendicular to the anatomical axis of the femur in the sagittal plane. The anatomical axis of the femur and the joint line were determined as previously described by Maderbacher et al.^{9,12} In brief, the femoral mechanical axis is defined as the line from the midpoint of the centre of the shaft to the midpoint of the distal femur, and the joint line defined as the line tangent to the most distal points of both the medial and the lateral femoral condylar articular surfaces. The most prominent points of the medial and lateral epicondyles and the joint lines were re-identified for each measurement (Fig. 1).

The most prominent points of the medial and lateral epicondyles were identified at the centre of the origins of the medial and lateral collateral ligaments, and hypodermic needles were inserted at these points to facilitate the measurements. Anteroposterior radiographs were taken for clinical application in order to confirm the localisation of the hypodermic needles. The previous needle insertion points were easily effaced after the measurements by rubbing the soft tissue overlying the epicondyles in order to minimise bias in subsequent measurements. Additional subsequent dissections were performed after the final

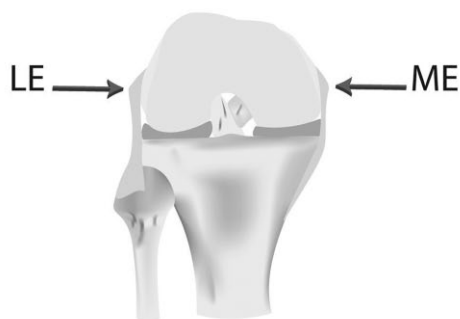


Fig. 1a

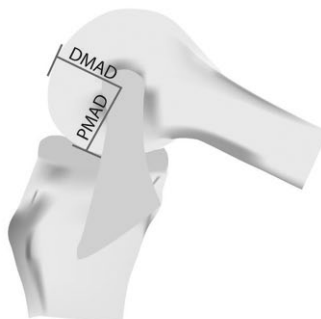

Fig. 1b

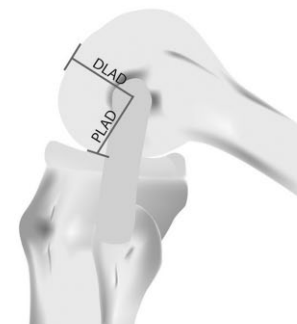


Fig. 1c

Diagrams showing a) determination of the medial and lateral epicondyles and transepicondylar width measurement in the anteroposterior view, b) determination of the distal medial articular distance (DMAD) and posterior medial articular distance (PMAD) in the medial view and c) determination of distal lateral articular distance (DLAD) and posterior lateral articular distance (PLAD) in the lateral view, with the knee in 100° to 110° flexion.

fourth needle insertion to confirm that the most prominent epicondylar points had been identified correctly. The joint lines were marked using a 1.2 mm Kirschner (K)-wire placed tangent to both the medial and lateral epicondylar articular surfaces at 0° and 90° posterior to the anatomical axis of the femur in the sagittal plane. The K-wires were temporarily attached to the distal and posterior articular surfaces of the medial and lateral femoral condyles with adhesive tape for individual measurement. Each reference point, the TEW, and the DMAD, DLAD, PMAD and PLAD were identified and measured with the knee in 100° to 110° of flexion. The internal borders of the hypodermic needle and the K-wire were measured. The collateral ligaments, cruciate ligaments and the joint capsules were released prior to joint line determination in cadavers in which flexion of > 100° could not be achieved. All measurements were taken to the nearest 0.1 mm using the same digital caliper. The ratios of DMAD, DLAD, PMAD, and PLAD to the transepicondylar width were calculated. The mean of each of the four measurements taken for each parameter (the first and the second measurements taken by each investigator) was used for the calculations.

Data were analysed using SPSS 15.0 (SPSS Inc, Chicago, Illinois). For each measured parameter, the mean and standard deviation (SD) were calculated for subsequent analyses. For each cadaver, we analysed the relationship between measurements and gender differences using the mean of four measurements. Between-gender differences in the measured parameters were assessed using Student's *t*-test. Differences between left and right measurements were compared by paired *t*-test. Pearson correlation and linear regression analyses were used to assess the relationships between joint-line distances (DMAD, DLAD, PMAD, PLAD) and the TEW. Stepwise regression analysis was used to assess the dependencies between the distal and posterior joint line distance (both medially and laterally), gender and the TEW in these relationships. Inter- and intra-observer reliability were analysed using analysis of variance. Intraclass correlation coefficients (ICC, absolute agreement) were

calculated with reliability statistics to assess inter-observer correlations. The mean values of both measurements were calculated in order to achieve agreement between investigators for further analyses. Differences were considered statistically significant when the *p*-value was < 0.05. TEW, DMAD, DLAD, PMAD and PLAD were measured in five male and five female cadavers, selected randomly in this study. Sample size was calculated as at least 37 knees with 80% power and 5% type I error.

Results

The inter- and intra-observer measurements for TEW, DMAD, DLAD, PMAD and PLAD did not significantly differ, confirming the reliability and reproducibility of the method. Anteroposterior screenings revealed that all the selected points of needle insertions were positioned correctly on the medial and lateral epicondyles. All four measurements for the same distance in our study differed within a 4 mm zone. The inter- and the intra-observer correlations were calculated according to a scale from *r* 0.40% to 0.59% (moderate), *r* 0.60% to 0.79% (good) to *r* ≥ 0.80% (excellent). All measurements scored excellent (Table I).

There was a significant difference in TEW, DMAD, DLAD, PMAD and PLAD between male and female cadavers (*p* < 0.001), but there was no significant difference between the left and right knees (*p* > 0.05). (Table II).

The ratios between the TEW and the perpendicular and posterior distance to the joint line from the most prominent point of the epicondyles for the medial condyle (DMAD/TEW, PMAD/TEW) and the lateral condyle (DLAD/TEW, PLAD/TEW) were calculated. These ratios did not significantly differ between genders (*p* > 0.05). The mean DMAD/TEW was 0.35 (SD 0.02; 0.31 to 0.37), the mean PMAD/TEW was 0.34 (SD 0.02; 0.32 to 0.38), the mean DLAD/TEW was 0.28 (SD 0.03; 0.23 to 0.32), and the mean PLAD/TEW was 0.29 (SD 0.03; 0.25 to 0.33). The mean ratios between TEW and the distance to the joint lines for male and female cadavers are shown in Tables II and III.

Table I. Inter- and intra-observer reliability

Measurement	Intra-observer reliability			Inter-observer reliability		
	r	95% CI	p-value	r	95% CI	p-value
TEW	0.98	0.97 to 0.99	< 0.001	0.98	0.98 to 0.99	< 0.001
DMAD	0.98	0.97 to 0.99	< 0.001	0.96	0.94 to 0.98	< 0.001
DLAD	0.94	0.89 to 0.97	< 0.001	0.98	0.98 to 0.99	< 0.001
PMAD	0.92	0.86 to 0.96	< 0.001	0.97	0.96 to 0.99	< 0.001
PLAD	0.98	0.97 to 0.99	< 0.001	0.97	0.95 to 0.98	< 0.001

CI, confidence interval; TEW, transepicondylar width; DMAD, distal medial articular distance; DLAD, distal lateral articular distance; PMAD, posterior medial articular distance; PLAD, posterior lateral articular distance

Table II. Mean measurement values and standard deviation (sd)

	Series (n = 40) Mean sd (range)	Male (n = 22) Mean sd (range)	Female (n = 18) Mean sd (range)	p-value*
TEW (mm)	82.76 sd 7.74 (67.12 to 96.23)	88.02 sd 5.32 (77.21 to 96.23)	76.35 sd 4.82 (67.12 to 85.91)	< 0.001
DMAD (mm)	28.95 sd 3.33 (20.40 to 35.85)	30.78 sd 2.59 (26.12 to 35.85)	26.72 sd 2.76 (20.40 to 31.52)	< 0.001
DLAD (mm)	23.97 sd 3.27 (15.27 to 31.47)	25.44 sd 2.69 (21.15 to 31.47)	22.17 sd 3.05 (15.27 to 27.56)	0.001
PMAD (mm)	28.57 sd 3.00 (21.08 to 35.40)	29.97 sd 2.65 (25.20 to 35.40)	26.85 sd 2.51 (21.08 to 32.01)	0.001
PLAD (mm)	24.42 sd 3.14 (16.43 to 33.12)	25.50 sd 2.87 (21.76 to 33.12)	23.10 sd 3.01 (16.43 to 27.37)	0.014
DMAD/TEW	0.35 sd 0.02 (0.31 to 0.37)	0.35 sd 0.02 (0.33 to 0.37)	0.34 sd 0.02 (0.31 to 0.36)	0.124
DLAD/TEW	0.28 sd 0.03 (0.23 to 0.32)	0.28 sd 0.03 (0.24 to 0.32)	0.29 sd 0.03 (0.23 to 0.32)	0.301
PMAD/TEW	0.34 sd 0.02 (0.32 to 0.38)	0.34 sd 0.03 (0.32 to 0.38)	0.35 sd 0.02 (0.32 to 0.37)	0.234
PLAD/TEW	0.29 sd 0.03 (0.25 to 0.33)	0.29 sd 0.03 (0.26 to 0.32)	0.30 sd 0.03 (0.25 to 0.33)	0.293

TEW, transepicondylar width; DMAD, distal medial articular distance; DLAD, distal lateral articular distance; PMAD, posterior medial articular distance; PLAD, posterior lateral articular distance

*All p-values were undertaken by Student's *t*-test

There were significant correlations between TEW and DMAD ($p < 0.001$; $r = 0.743$), DLAD ($p < 0.001$; $r = 0.607$), PMAD ($p < 0.001$; $r = 0.678$), and PLAD ($p < 0.001$; $r = 0.529$) (Table IV).

The results of the multiple linear regression analyses are shown in Table V. The regression models included TEW as a dependent variable and the articular distance measurements (DMAD, DLAD, PMAD, PLAD) and gender as independent variables. Gender was included in the regression models because the measurements of articular distance were significantly different between male and female knees. Regression analyses showed a linear correlation between the TEW and DMAD, gender ($y = 56.24 + 1.03X_1 - 7.47X_2$) ($R^2 = 0.70$); TEW and DLAD, gender ($y = 69.93 + 0.71X_1 - 9.34X_2$) ($R^2 = 0.64$); TEW and PMAD, gender ($y = 58.1 + 0.99X_1 - 8.88X_2$) ($R^2 = 0.69$); and TEW and PLAD, gender ($y = 70.56 + 0.68X_1 - 10.02X_2$) ($R^2 = 0.64$).

Discussion

Restoring the anatomical joint line during a revision TKA procedure is challenging, and there is a negative impact on the functional outcome of the surgery if correct anatomical restoration is not achieved.⁵ The results of this study indicate that the epicondyles are useful and reliable bony landmarks for determining the location of the anatomical joint line. Proper flexion and extension gap balance and accurate femoral component size choice and the joint line localisation can be easily estimated in relation to the lateral epicondyle by multiplying TEW with 0.28 distally and 0.29 posteriorly and also in relation to

Table III. Simple equation of TEW to DMAD, DLAD, PMAD and PLAD

	DMAD	DLAD	PMAD	PLAD
TEW	0.35	0.28	0.34	0.29

TEW, transepicondylar width; DMAD, distal medial articular distance; DLAD, distal lateral articular distance; PMAD, posterior medial articular distance; PLAD, posterior lateral articular distance

the medial epicondyle by multiplying TEW with 0.35 distally and 0.34 posteriorly, elementarily as a result of the present study. This practical operation can be beneficial in determining appropriate joint line position in challenging cases.

Alterations in joint line position negatively affect the ROM, pain, satisfaction and function of the patient. The range of alteration in joint line that leads to inferior clinical results is controversial.¹³ Previous reports stated that an alteration of more than sd 8 mm has a significant negative effect on the clinical outcomes.^{3,4,9} Although subsequent studies reported the acceptable critical range as sd 5 mm,^{8,11} more recently opinion in the literature on this subject has been changed by newer reports indicating that a deviation of more than 4 mm in the joint line proximally or distally from its normal position leads to unfavourable results.^{10-13,14-16} Thus, it is clear that exact determination of the anatomical joint line is essential to achieve an optimal post-operative clinical outcome. We believe that the anatomical joint line can be restored within the acceptable zone of less than 5 mm proximally or distally from its neutral/original anatomical position by

Table IV. Simple correlations between TEW and femoral articular distances

	r	p-value*
DMAD	0.743	0.001
DLAD	0.607	0.001
PMAD	0.678	0.001
PLAD	0.529	0.001

DMAD, distal medial articular distance; DLAD, distal lateral articular distance; PMAD, posterior medial articular distance; PLAD, posterior lateral articular distance

*All p values undertaken by Pearson's correlation test

Table V. Results of linear regression analyses of the relationship between TEW and joint-line distance

	B	SE	β	p-value
Model 1 R ² = 0.70				
Constant	56.24	8.19		< 0.001
Gender	-7.47	1.75	-0.48	< 0.001
DMAD	1.03	0.26	0.44	< 0.001
Model 2 R ² = 0.64				
Constant	69.93	6.91		< 0.001
Gender	-9.34	1.74	-0.60	< 0.001
DLAD	0.71	0.26	0.30	0.012
Model 3 R ² = 0.69				
Constant	58.10	8.41		< 0.001
Gender	-8.55	1.66	-0.55	< 0.001
PMAD	0.99	0.27	0.38	0.001
Model 4 R ² = 0.64				
Constant	70.56	6.78		< 0.001
Gender	-10.02	1.63	-0.65	< 0.001
PLAD	0.68	0.26	0.27	0.013

DMAD, distal medial articular distance; DLAD, distal lateral articular distance; PMAD, posterior medial articular distance; PLAD, posterior lateral articular distance; B, regression coefficient; SE, standard error of regression coefficient

using this simple, and reproducible method that we have presented herein.

Review of the literature suggests that surgeons tend to locate the joint line more proximally than its anatomical position in revision TKA.^{3,5,6} Elevation of the joint line occurs when the bone lost from the distal femur is not replaced. During revision TKA, a distal femoral bony defect is frequently encountered. Additionally, posterior bone loss is frequently seen during revision TKA, leading to a tendency to prefer a smaller sized femoral component to obtain direct contact of the implant with the remaining bone. A thicker insert is typically used to fill the resulting flexion gap, leading to a proximally shifted joint line.⁶ Review of the literature has also revealed that use of a straight femoral stem enlarges flexion space as these stems tend to position the femoral component anteriorly.⁶ Poor outcomes such as flexion-extension gap imbalance and possible complications may be prevented by the proper implantation of the femoral component in sagittal, coronal and axial planes, in its anatomical localisation, and by using the anatomical measurements and ratios highlighted in the present study. Studies about both the distal and posterior articular distances from the femoral epicondyles continue to be of interest.^{17,18} Determining the accurate size and location of the femoral

component may be possible by creating imaginary borders of the femur, especially by taking into consideration posterior articular distances combined with distal articular distances from medial and lateral epicondyles.

Pre-operative planning for revision TKA involves imaging analysis of the same knee, or the contralateral knee without a TKA, and using plain radiography, CT and MRI. The position of the joint line is determined based on anatomical reference points visualised on the radiograph and is then created during surgery.^{2,5} Serious problems can result if the reference points used to determine the joint line location cannot be identified during surgery because of additional bone loss associated with removal of the previous implant. Additionally, an oversized prosthesis implanted previously, or large osteophytes or bone defects, may also conceal the bony landmarks. Considering the time, cost, radiation dose and potential risks associated with radiological methods, a simple, reproducible intra-operative technique that enables accurate anatomical joint line restoration may avoid these undesired problems associated with pre-operative planning for revision TKA.

The importance of the intra-operative determination of anatomical landmarks has been discussed.¹⁹ Anatomical landmarks such as the tibial tuberosity, fibular head, meniscal scar and inferior pole of the patella have been used.¹¹ The measurements using these landmarks are highly variable, which negatively influences the use of these methods for determining the joint line.^{5,11} However, accurate joint line determination based on the fibular head or tibial tuberosity is still the subject of recent studies.^{2,14,20} All these bony landmarks may be successfully used as reference points for determining the anatomical joint line pre-operatively via radiological evaluation, but for intra-operative determination we need simpler, more accurate methods which enable restoration of the joint line to within the acceptable range of its correct anatomical position.

Selection of the femoral component should not be based upon the remaining anteroposterior bone, but rather upon the mediolateral dimension of the condylar bone.⁶ A distal femoral bone defect may occur because of excessive bone resection during primary TKA or bone loss at revision due to osteolysis, infection, migration of the component, or fracture, or damage to the distal femur during removal of the previous component.⁷ The epicondyles are less prone to bone defects than are the distal and posterior femoral condyles. The method that we have presented is based upon the mediolateral dimension. Intra-operative methods for locating the joint line using the epicondyles have been previously described: those reporting approximate distance values^{5,21} or ratios.^{2,10,17,22,23} The idea of creating ratios on this subject depends on the fact that owing to ethnic and anthropometric variation, the dimensions of the distal femur may differ between individuals. However, the ratio between

the TEW and the epicondyle-joint line distance is not affected by anthropometric properties such as height and gender and was consistent between patients.

We found a non-gender-specific ratio between the TEW and the DMAD, DLAD, PMAD and PLAD, which correlates with the literature.² The universality of these ratios makes them routinely useful, easy to apply, clinically feasible and able to be standardised for intra-operative determination of both the distal and posterior anatomical joint lines. Recent studies emphasise the importance of correct localisation of both the distal and posterior anatomical joint lines during TKA to achieve ideal outcomes throughout the entire ROM.^{5,8}

The joint line is not perpendicular to the tibial mechanical axis; there is 3° to 4° of varus alignment with reference to the mechanical axis of the tibia.^{9,12,24,25} The joint line orientation will vary if surgeons performed the classical resection method of the proximal tibia and distal femur perpendicular to the mechanical axis, thus not respecting the natural deviation of the joint line. Among the patients with natural joint line obliquity, the classical resection method will lower the joint line on the lateral side as a result of lateral tibial over-resection. The natural joint line will be altered from a 3° to 4° of varus angulation to a valgus angle of 3° to 4°.^{9,12} In our opinion, creation of the imaginary borders of the distal femur by the described ratio associated with the femoral epicondyles can prevent potential confusion in regards to the natural joint line obliquity.

The limitation of our measurement technique is that it is only useful in cases with intact epicondyles. Also, some authors have suggested that epicondyle determination may be difficult due to excessive soft tissues, fibrosis and scarring overlying the epicondyles, loss of bone and the operator-dependent factors associated with the surgeons' ability to pinpoint identification accurately.^{10,19,22,26-28} However, others have concluded that the epicondyles are reliable and easily identifiable intra-operative bony landmarks in TKA.^{22,23,29} The superficial soft tissues covering the epicondyles can be dissected up to the collateral ligaments as a part of standard surgical exposure and debridement. In revision TKA surgery, dissection of the distal femur is usually more extensive than in primary TKA cases, allowing easy identification of the medial and lateral epicondyles. During the study period, all four inter- and intra-observer measurements were reproducible to within a very narrow range, which would allow proper joint line determination within the critical 5 mm safety zone.

Use of the measurements that we describe in this study may have broad clinical application. This method, which uses the medial and lateral epicondyles as bony landmarks and the epicondylar ratio to account for gender and size variations, takes into consideration posterior articular distances combined with distal articular

distances and provides a simple, reproducible and reliable technique for accurate anatomical joint line restoration in revision TKA.

References

- Mahoney OM, Kinsey TL.** Modular femoral offset stems facilitate joint line restoration in revision knee arthroplasty. *Clin Orthop Relat Res* 2006;446:93-98.
- Romero J, Seifert B, Reinhardt O, Ziegler O, Kessler O.** A useful radiologic method for preoperative joint-line determination in revision total knee arthroplasty. *Clin Orthop Relat Res* 2010;468:1279-1283.
- Partington PF, Sawhney J, Rorabeck CH, Barrack RL, Moore J.** Joint line restoration after revision total knee arthroplasty. *Clin Orthop Relat Res* 1999;367:165-171.
- Porteous AJ, Hassaballa MA, Newman JH.** Does the joint line matter in revision total knee replacement? *J Bone Joint Surg [Br]* 2008;90-B:879-884.
- Mason M, Belisle A, Bonutti P, et al.** An accurate and reproducible method for locating the joint line during a revision total knee arthroplasty. *J Arthroplasty* 2006;21:1147-1153.
- Bellemans J.** Restoring the joint line in revision TKA: does it matter? *Knee* 2004;11:3-5.
- Yoshii I, Whiteside LA, White SE, Milliano MT.** Influence of prosthetic joint line position on knee kinematics and patellar position. *J Arthroplasty* 1991;6:169-177.
- Martin JW, Whiteside LA.** The influence of joint line position on knee stability after condylar knee arthroplasty. *Clin Orthop Relat Res* 1990;259:146-156.
- Maderbacher G, Keshmiri A, Schaumburger J, et al.** Accuracy of bony landmarks for restoring the natural joint line in revision knee surgery: an MRI study. *Int Orthop* 2014;38:1173-1181.
- Luycckx T, Beckers L, Colyn W, Vandenneucker H, Bellemans J.** The adductor ratio: a new tool for joint line reconstruction in revision TKA. *Knee Surg Sports Traumatol Arthrosc* 2014;22:3028-3033.
- Ji SJ, Zhou YX, Jiang X, et al.** Effect of joint line elevation after posterior-stabilized and cruciate-retaining total knee arthroplasty on clinical function and kinematics. *Chin Med J (Engl)* 2015;128:2866-2872.
- Maderbacher G, Keshmiri A, Zeman F, Grifka J, Baier C.** Assessing joint line positions by means of the contralateral knee: a new approach for planning knee revision surgery? *Knee Surg Sports Traumatol Arthrosc* 2015;23:3244-3250.
- Gromov K, Korchi M, Thomsen MG, Husted H, Troelsen A.** What is the optimal alignment of the tibial and femoral components in knee arthroplasty? *Acta Orthop* 2014;85:480-487.
- Sadaka C, Kabalan Z, Hoyek F, Abi Fares G, Lahoud JC.** Joint line restoration during revision total knee arthroplasty: an accurate and reliable method. *Springerplus* 2015;4:736-740.
- Kowalczewski JB, Labey L, Chevalier Y, et al.** Does joint line elevation after revision knee arthroplasty affect tibio-femoral kinematics, contact pressure or collateral ligament lengths? An in vitro analysis. *Arch Med Sci* 2015;11:311-318.
- Cleve A, Henaff GL, Roger T, et al.** Joint line level in revision total knee replacement: assessment and functional results with an average of seven years follow-up. *Int Orthop* 2016 (Epub ahead of print).
- Servien E, Viskontas D, Giuffrè BM, Coolican MR, Parker DA.** Reliability of bony landmarks for restoration of the joint line in revision knee arthroplasty. *Knee Surg Sports Traumatol Arthrosc* 2008;16:263-269.
- Cherian JJ, Kapadia BH, Banerjee S, et al.** Mechanical, anatomical, and kinematic axis in TKA: concepts and practical applications. *Curr Rev Musculoskelet Med* 2014;7:89-95.
- Stoeckl B, Nogler M, Krismer M, et al.** Reliability of the transepicondylar axis as an anatomical landmark in total knee arthroplasty. *J Arthroplasty* 2006;21:878-882.
- Tang Q, Zhou Y, Yang D, Tang J, Shao H.** The knee joint line position measured from the tibial side in Chinese people. *J Arthroplasty* 2011;26:989-993.
- Martin JW, Whiteside LA.** The influence of joint line position on knee stability after condylar knee arthroplasty. *Clin Orthop Relat Res* 1990;259:146-156.
- Iacano F, Raspugli GF, Filardo G, et al.** The adductor tubercle: an important landmark to determine the joint line level in revision total knee arthroplasty. *Knee Surg Sports Traumatol Arthrosc* 2015 (Epub ahead of print).
- Rajagopal TS, Nathwani D.** Can interepicondylar distance predict joint line position in primary and revision knee arthroplasty? *Am J Orthop (Belle Mead NJ)* 2011;40:175-178.

24. **Bellemans J, Colyn W, Vandenneucker H, Victor J.** The Chitranjan Ranawat award: is neutral mechanical alignment normal for all patients? The concept of constitutional varus. *Clin Orthop Relat Res* 2012;470:45-53.
25. **Victor JM, Bassens D, Bellemans J, et al.** Constitutional varus does not affect joint line orientation in the coronal plane. *Clin Orthop Relat Res* 2014;472:98-104.
26. **Yan CH, Yau WP, Ng TP, et al.** Inter- and intra-observer errors in identifying the transepicondylar axis and Whiteside's line. *J Orthop Surg (Hong Kong)* 2008;16:316-320.
27. **Amanatullah DF, Di Cesare PE, Meere PA, Pereira GC.** Identification of the landmark registration safe zones during total knee arthroplasty using an imageless navigation system. *J Arthroplasty* 2013;28:938-942.
28. **Raju S, Chinnakkannu K, Sunderayan R, Puttaswamy MK.** Rotational landmarks of the distal femur in Indian population: A MRI-based study. *J Orthop Surg Res* 2015;10:186-191.
29. **Kobayashi H, Akamatsu Y, Kumagai K, et al.** Is the surgical epicondylar axis the center of rotation in the osteoarthritic knee? *J Arthroplasty* 2015;30:479-483.

Funding Statement

- None declared.

Author Contribution

- B. Ozkurt: Design, Data collection, Writing, Dissections, Measurements, Final control.
- T. Sen: Dissections, Measurements.
- D. Cankaya: Data collection, Measurements.
- S. Kendir: Dissections, Measurements.
- K. Basarir: Data collection.
- Y. Tabak: Data collection.

ICMJE conflict of interest

- None declared.

© 2016 Ozkurt et al. This is an open-access article distributed under the terms of the Creative Commons Attribution licence (CC-BY-NC), which permits unrestricted use, distribution, and reproduction in any medium, but not for commercial gain, provided the original author and source are credited.