



## ■ RESEARCH

# Bone micro-architectural analysis of mandible and tibia in ovariectomised rats

A QUANTITATIVE STRUCTURAL COMPARISON BETWEEN UNDECALCIFIED HISTOLOGICAL SECTIONS AND MICRO-CT

**H. Liu\***,  
**W. Li\***,  
**Y. S. Liu**,  
**Y. S. Zhou**

Department of  
Prosthodontics, Peking  
University School  
and Hospital of  
Stomatology

■ H. Liu, MS, Assistant Research Fellow, Department of Prosthodontics, The Core Laboratory, Peking University School and Hospital of Stomatology,  
■ W. Li, BS, Technician, Department of Oral Pathology, Peking University School and Hospital of Stomatology,  
■ Y. S. Liu, DDS, Dentist, Department of Prosthodontics, Peking University School and Hospital of Stomatology,  
■ Y. S. Zhou, DDS, PhD, Dentist, Department of Prosthodontics, National Engineering Lab for Digital and Material Technology of Stomatology, Peking University School and Hospital of Stomatology, 22 Zhongguancun South Avenue, Haidian District, Beijing 100081, China

Correspondence should be sent to Professor Y. S. Zhou; email: kqzhouysh@hsc.pku.edu.cn

doi:10.1302/2046-3758.56.2000565

*Bone Joint Res* 2016;5:253–262.

Received: 2 September 2015;

Accepted: 22 March 2016

## Objectives

This study aims to evaluate if micro-CT can work as a method for the 3D assessment and analysis of cancellous bone by comparing micro-CT with undecalcified histological sections in OVX rats.

## Methods

The mandible and tibia of sham, ovariectomised (OVX) and zoledronate-injected ovariectomised (OVX-ZOL) rats were assessed morphometrically. Specimens were scanned by micro-CT. Undecalcified histological sections were manufactured from the specimen scanned by micro-CT and stained with haematoxylin and eosin. Bivariate linear regressions and one-way analysis of variance were undertaken for statistics using SPSS 16.0.1 software.

## Results

There were highly significant correlations between undecalcified histological sections and micro-CT for all parameters (bone volume density (BV/TV), bone surface density (BS/BV), trabecular thickness (Tb.Th), trabecular number (Tb.N), and trabecular separation (Tb.Sp)) in the mandible and tibia. Bone histomorphometric parameters analysed by both methods exhibited significant differences among sham, OVX, and OVX-ZOL groups. There were significant correlations between mandible and tibia in BV/TV, BS/BV, and Tb.Sp.

## Conclusions

Micro-CT is a complementary tool to histological sections in basic research that could improve our understanding of bone histomorphometry. The mandible can be used as an effective site to assess bone morphometry of OVX or metabolic bone disease rat models.

**Cite this article:** *Bone Joint Res* 2016;5:253–262.

**Keywords:** Mandible; Tibia; Bone histomorphometry; Micro-CT; Undecalcified histological sections

## Article focus

■ To compare bone micro-architectural analysis of bone disease between undecalcified histological sections and micro-CT using rodent models.

## Key messages

- There were highly significant correlations between the results of micro-architectural analysis of undecalcified histological sections and micro-CT of the mandible and tibia for all parameters.
- The mandible could be used as an alternative site with which to evaluate the bone morphometry of metabolic bone diseases

## Strengths and limitations

- This is the first study, using rodent models, to compare bone micro-architectural analysis of bone disease between undecalcified histological sections and micro-CT.
- However, relatively few undecalcified histological sections were made from individual specimens. This partially explained the different results obtained from undecalcified histological sections and micro-CT, particularly for the tibia.

## Introduction

Quantitative bone histomorphometry is a method that assesses the structural properties

of trabeculae in basic or clinical research.<sup>1,2</sup> Quantitative bone histomorphometry is an important index of bone micro-architecture in research on bone disease such as metabolic bone diseases and bone defects.<sup>3-5</sup> Traditionally, bone micro-architectural analysis has been assessed by histological sections (2D measurements), where the structural parameters are either inspected visually or measured from sections, and the third dimension is added based on stereology.<sup>6,7</sup> However, histological sectioning is a tedious and time-consuming method. Moreover, these descriptors of the trabecular network are derived from measurements from the trabecular area and trabecular perimeter, and provide only a limited description of the architecture in 2D measurements. The destructive character of the procedure is particularly limiting. Once sectioned, the bone specimens are no longer available for other static or dynamic histomorphometric analyses.<sup>8-10</sup> Therefore, it is important to design a non-destructive method of bone micro-architectural analyses.

Micro-computed tomography (micro-CT) is a miniaturised version of computerised axial tomography, and the system has a resolution in the order of a few micrometres.<sup>11</sup> Micro-CT has great advantageous characteristics compared with histological sections such as being non-destructive, fast, and easy to operate.<sup>11-15</sup> Although micro-CT was established to a large extent for bone analytical purposes, the procedures and applications utilised to assess and analyse the trabecular bone structure quantitatively are not yet fully standardised, especially for the jaw.<sup>16,17</sup>

Recently, post-menopausal osteoporosis has been shown to have an increased rapid morbidity among the elderly and has become a research focus worldwide.<sup>18-20</sup> Hence, ovariectomised (OVX) rats, as the most commonly used animal model of post-menopausal osteoporosis, were chosen in this study to assess the skeletal micro-architecture of metabolic bone disorders.<sup>21</sup> It is well known that the mandible is both morphologically and functionally different from other bones of the axial or peripheral skeleton.<sup>22</sup> Hence, the mandibular alveolar bone may be used as an alternative site to evaluate the bone morphometry in OVX rats, which ensures that the comparison between undecalcified histological sections and micro-CT is more comprehensive.

This study aims to evaluate if micro-CT can work as a method for the 3D assessment and analysis of cancellous bone by comparing micro-CT with conventional bone histomorphometry in OVX rats, and to determine whether the mandible can be used as an effective site to evaluate the bone morphometry of OVX rats, or other models of metabolic bone disease.

## Materials and Methods

**Animals and administration procedure.** All animal experiments were approved by the Animal Care and Use Committee of Peking University Health Science Center (Approval number: LA2014233, Beijing, China). Female

Sprague Dawley rats aged eight weeks ( $n = 15$ ) were purchased and a bilateral OVX or sham operation was performed using standard methods. Four weeks after the OVX or sham operation, rats were assigned randomly into three groups of five: sham rats injected with vehicle (sham group); OVX rats injected with vehicle (OVX group); and OVX rats injected with zoledronate (100  $\mu\text{g}/\text{kg}$ ) subcutaneously at days 1 and 8 (OVX-ZOL group). Three months later, the rats were killed and the mandible and the tibia from each animal were thoroughly dissected free from soft tissue and fixed in 10% neutral-buffered formalin, and used for micro-CT and undecalcified histological sections.

**Micro-CT analysis.** The mandibles and tibias were studied using a compact fan-beam-type tomography system (Inveon MM CT, Siemens AG, Munich, Germany). In brief, the mandible or tibia was located and scanned in its entirety, being rotated 360° in 360 equiangular steps.<sup>13</sup> Images were scanned at a resolution of 8.82  $\mu\text{m}$ , tube voltage of 80 kV, tube current of 500  $\mu\text{A}$  and exposure time of 1500 ms. The images consisted of 1536 slices with a voxel size of 17.64  $\mu\text{m}$  in all three axes. Two-dimensional images were used to generate 3D reconstructions using multimodal 3D visualisation software (Inveon Research Workplace, Siemens). In order to evaluate the influence of scanning resolution on the results from micro-CT analysis, the same specimen was scanned at resolutions of 8.82  $\mu\text{m}$ , 13.57  $\mu\text{m}$ , 35.32  $\mu\text{m}$ , 43.74  $\mu\text{m}$  and 104.84  $\mu\text{m}$ , with all other parameters being kept the same.

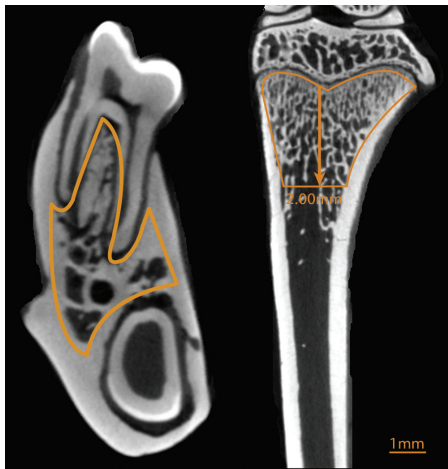
For the mandible, the region of interest (ROI) was obtained from all trabecular bone under the first molar domains (Fig. 1) as previously described.<sup>17</sup> For the tibia, the ROI was drawn 2 mm from the nadir of the proximal epiphysis. An appropriate threshold was adjusted exactly to the mineralised bone phase. The threshold levels distinguishing trabecular bone from bone marrow for mandible and tibia in sham, OVX and OVX-ZOL groups are shown in Table I. The parameters were calculated as follows: bone volume density (BV/TV), bone surface density (BS/BV), trabecular thickness (Tb.Th), trabecular number (Tb.N) and trabecular separation (Tb.Sp).<sup>23</sup>

**Histological sectioning and staining.** The mandible and tibia were fixed and dehydrated in ethanol followed by embedding in destabilised methyl methacrylate resin under vacuum at room temperature. Next, the sections were ground and polished to 20  $\mu\text{m}$  to 30  $\mu\text{m}$  by the EXAKT precision cutting and grinding system (EXAKT Apparatebau GmbH & Co KG, Norderstedt, Germany) and stained with haematoxylin and eosin (H&E).<sup>13</sup> A similar ROI, as previously defined in the micro-CT measurement, was analysed by means of a semi-automatic histomorphometric analysis system (Bio-Quant Inc., San Diego, California). The undecalcified histological slices stained by H&E were automatically photographed by Nikon inverted microscope and the images were transferred to graphic workstation. Next, the ROI of the undecalcified histological slices was drawn using the BQ Imaging Toolkit (Bio-Quant Inc., San Diego,

**Table 1.** The threshold levels of micro-CT for mandible and tibia in the sham, ovariectomised and zoledronate-injected ovariectomised groups

	Threshold value*		
	Sham	OVX	OVX-ZOL
Mandible	2928.99 to 3010	2386 to 2453.32	2926.81 to 2992.77
Tibia	2409.31 to 2480	2340.39 to 2421.94	2711.79 to 2911.45

\*When the histomorphometric parameters by micro-CT were analysed, a threshold value was set to distinguish trabecular bone from bone marrow. If the numerical range was from the threshold value to the maximum value, the region of interest (ROI) showed the trabecular bone in the specimen; if the numerical range was from the minimum value to the threshold value, the ROI showed the bone marrow in the specimen  
OVX, ovariectomised rats; OVX-ZOL, zoledronate-injected ovariectomised rats

**Fig. 1**

This representative image from a micro-CT shows that the region of interest (ROI) on the mandible in the axial plane and on the tibia in the coronal plane (the yellow outline represents the ROI on mandible and tibia). Scale bar = 1 mm.

California). After the threshold value was set, the histomorphometric parameters were automatically calculated by BIOQUANT OSTEO Image Analysis Systems (Bio-Quant Inc., San Diego, California). Of note, trabecular diameter (Tb.Dm) in two-dimensional histology is instead of the Tb.Th from 3D histomorphometric parameters of micro-CT.

**Statistical analysis.** Quantitative data for correlations of the histomorphometric parameters on mandible or tibia between micro-CT and histological sections are presented as bivariate linear regressions using SPSS 16.0.1 software (IBM, Armonk, New York). The coefficient of variation (CV) was calculated as the standard deviation (SD) percentage of the mean. Coefficients of correlation ( $r$ ) and determination ( $r^2$ ) are given for the goodness of fit. Additionally, one-way analysis of variance (ANOVA) was undertaken for comparison within groups;  $p < 0.05$  was considered statistically significant. Quantitative data of the histomorphometric parameters are presented as mean and SD.

## Results

**Stereology-based comparison of histological and corresponding micro-tomographical sections of mandible and tibia.** Compared with the images of histological sections in the first row of Figure 2, the 3D reconstruction images

(second row) showed that there were still a slight reduction of bone mass in trabecular boundaries, which might be correlated with the loss of low-density tissue induced by radiograph in micro-CT, such as new bone and osteoid (Fig. 2).

**The evaluation of the accuracy of micro-CT analysis of mandibles and tibias at different scanning resolutions.** The radiographs of mandibles and tibias from the same rat in the sham group became less clear as the scanning resolution decreased. The boundary between trabecular bone and bone marrow of tibias and mandibles could not be clearly distinguished at resolutions below  $8.82 \mu\text{m}$  and  $13.57 \mu\text{m}$ , respectively (Fig. 3). There were unpredictable changes in the results of morphometric parameters at different resolutions; the data obtained at the highest resolution were similar to those obtained by histological analysis. It was therefore concluded that the most appropriate resolution at which to scan was  $8.82 \mu\text{m}$ .

**Histomorphometric parameters of mandible correlations between histological indices and micro-CT.** The results indicated that the mean calculated by micro-CT was slightly overestimated in BV/TV, BS/BV and Tb.N compared with that of histology in the remaining three groups. The Tb.Sp average was calculated to be roughly equal between the two methods. According to the formula ( $\text{Tb.Dm} = 4/(\text{BS}/\text{BV})$ ,  $\text{Tb.Th} = 2/(\text{BS}/\text{BV})$ ), Tb.Dm was equal to twofold Tb.Th in number ( $\text{Tb.Dm} = 2 * \text{Tb.Th}$ ).<sup>24</sup> Hence, the mean of Tb.Th from micro-CT was equal to Tb.Dm by histology, and the two parameters are combined hereinafter to simplify the analysis. The coefficients of variations (CV) of histomorphometric parameters from micro-CT were lower when compared with their corresponding histological CVs.

Our results demonstrated that there were significant correlations in the mandible between histological indices and micro-CT analysis for all five histomorphometric parameters (Fig. 4). Moreover, for the mandible, good correlation was found between the two methods for BV/TV, Tb.Th, and Tb.Sp, with the mean percentage differences being no more than 5%. Larger differences, although still relatively small, were found for BS/BV and Tb.N.

**The correlations of the histomorphometric parameters of the tibia between histological indices and micro-CT.** Our results demonstrated that the 3D values from micro-CT were overestimated in the BV/TV compared with

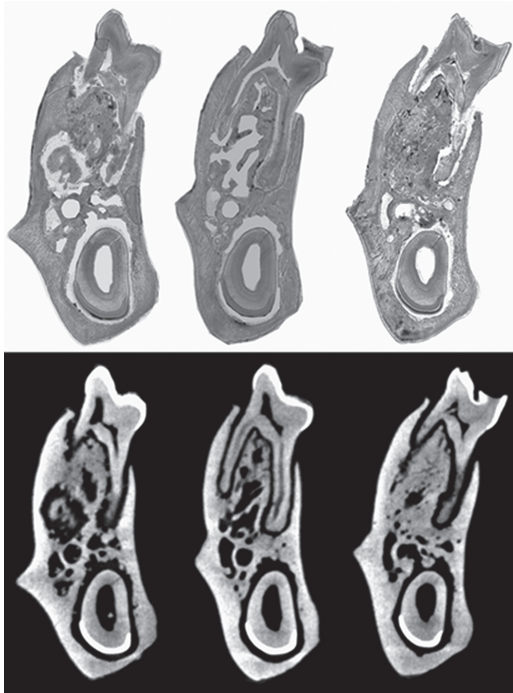


Fig. 2a

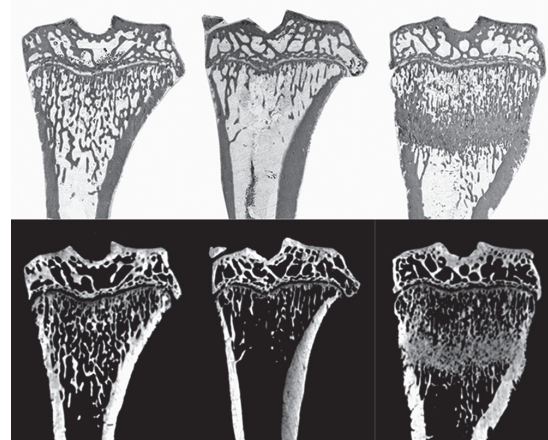


Fig. 2b

These images show the bone micro-architecture of the a) mandible and b) tibia among sham, ovariectomised (OVX) and zoledronate-injected ovariectomised (OVX-ZOL) groups in the coronal plane. The first row represents a single histological section. The second row represents a 3D reconstruction corresponding to histological section. Scale bar = 1 mm.

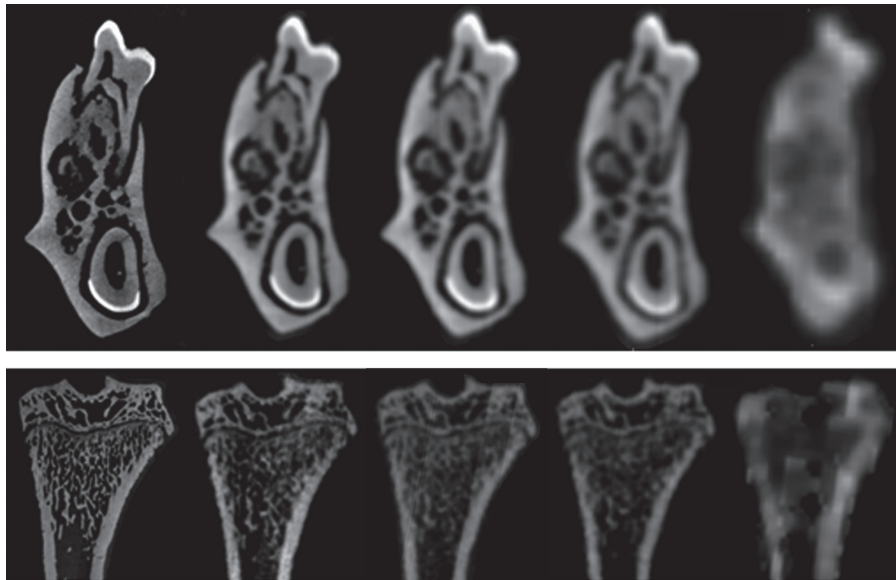


Fig. 3

Radiographs of the mandible (top) and tibia (bottom) from the same rat at all five scanning resolutions. The radiographs became less clear as the scanning resolution decreased. Scale bar = 1 mm.

2D measurements obtained from histological sections. The averages of the other parameters were inconsistent between the two methods. However, the CV of histomorphometric parameters from micro-CT was lower compared with their corresponding histological ones. Unexpectedly, the CVs of the tibia were higher compared with those of the mandible, especially in the OVX-ZOL

group. In the OVX-ZOL group, the CV value of the tibia was dramatically higher than that of either sham or OVX groups. This was associated with the pyknotic bone trabecular plate induced by zoledronate below the proximal epiphysis (Fig. 2b).

In addition, for the tibia, there were significant correlations between histological indices and micro-CT analysis

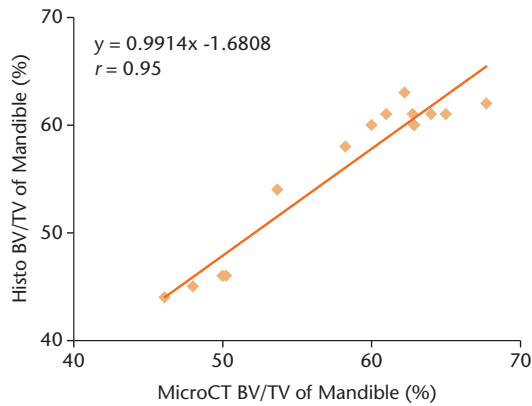


Fig. 4a

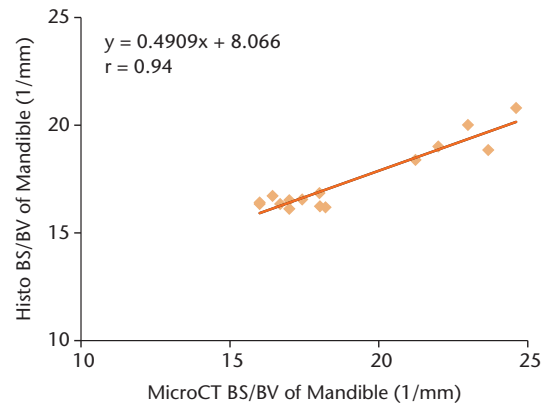


Fig. 4b

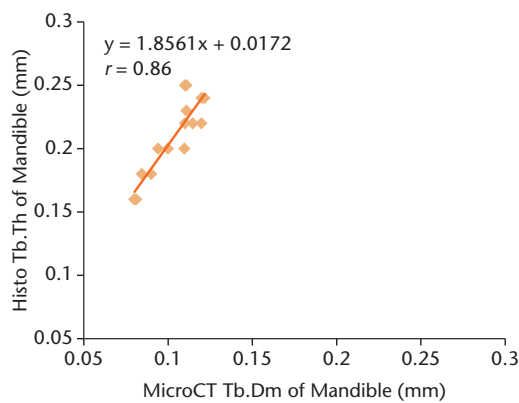


Fig. 4c

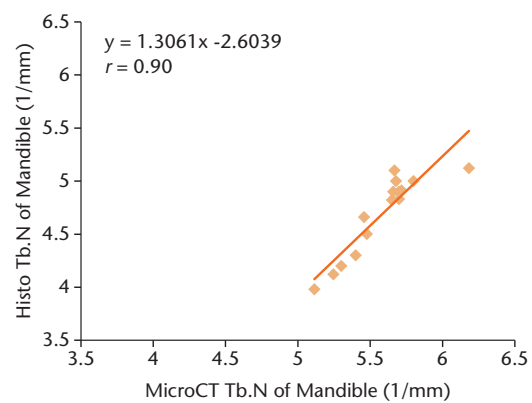


Fig. 4d

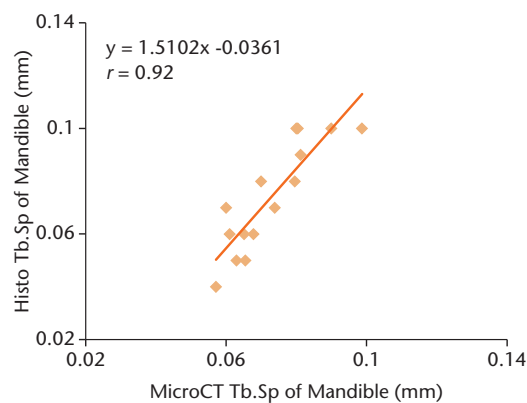


Fig. 4e

Histological indices and micro-CT analysis correlations from the same histomorphometric parameters of the mandible; a) bone volume density; b) bone surface density; c) Tb.Dm (Tb. Th); d) trabecular number; e) trabecular separation. A total of 15 specimens among sham, ovariectomised, and zoledronate-injected ovariectomised groups were used for correlations. All regressions were highly significant.

for all five histomorphometric parameters (Fig. 5). However, for the tibia, good correlation between the two methods was only found in Tb.Th. The mean percentage differences of the other four parameters in the tibia were higher than those of the mandible.

#### Histomorphometric parameter correlations between the mandible and tibia by histological indices and micro-CT

**analysis.** There were significant correlations observed in BV/TV, BS/BV, and Tb.Sp between mandible and tibia, respectively (Fig. 6). Consistent with the correlation of histological analysis, the results of micro-CT showed that the more significant correlations were found in BV/TV, BS/BV, Tb.N, and Tb.Sp between mandible and tibia (Fig. 7). These data have confirmed that the variation

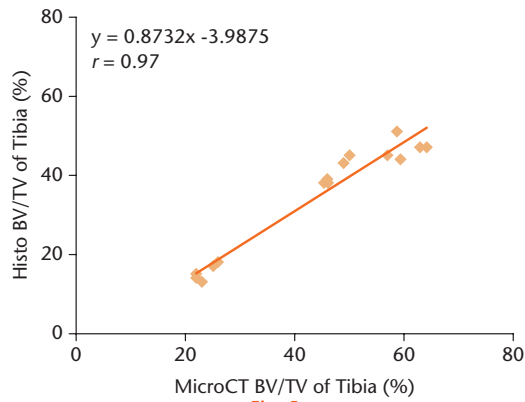


Fig. 5a

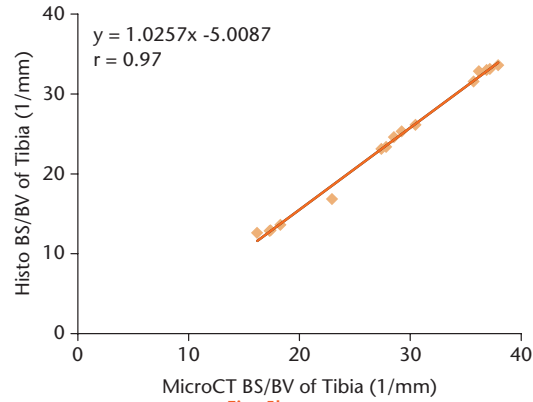


Fig. 5b

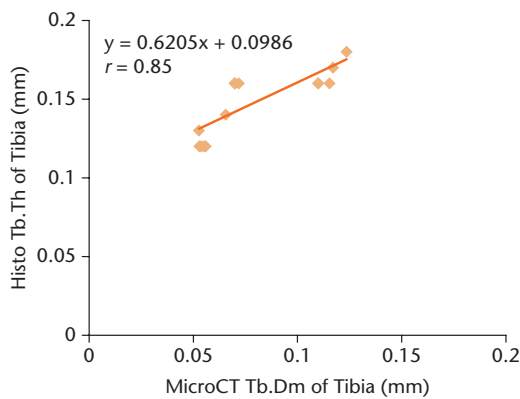


Fig. 5c

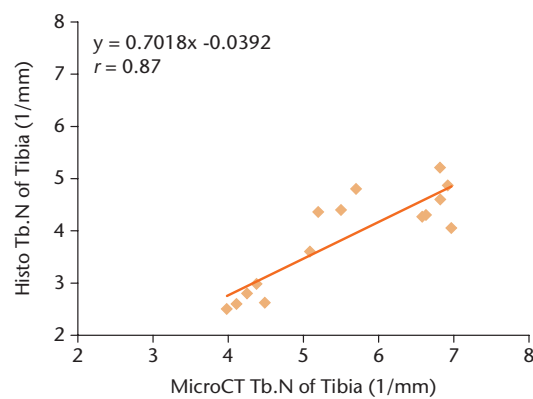


Fig. 5d

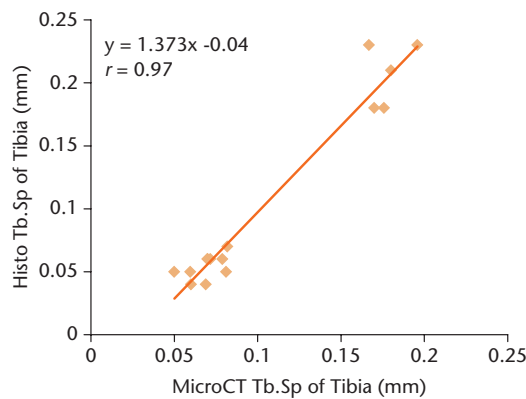


Fig. 5e

Histological indices and micro-CT analysis correlations from the same histomorphometric parameters of the tibia; a) bone volume density; b) bone surface density; c) Tb.Dm (Tb. Th); d) trabecular number; e) trabecular separation. A total of 15 specimens among sham, ovariectomised and zoledronate-injected ovariectomised groups were used for correlations. All regressions were highly significant.

of histomorphometric parameters in the mandible was associated with that of the tibia in OVX-induced osteoporotic or zoledronate-treated rat models.

**Comparison of histomorphometric parameters among sham, OVX, and OVX-ZOL groups by undecalcified histological sections and micro-CT.** For undecalcified histological sections of the tibia, the OVX group significantly decreased in BV/TV, Tb.Dm, and Tb.N compared with

sham and OVX-ZOL groups. Moreover, there were significant increases in BS/BV and Tb.Sp in the OVX group compared with the sham and OVX-ZOL groups. The OVX-ZOL group dramatically increased in BV/TV and decreased in BS/BV compared with the sham group. Consistent with undecalcified histological sections, micro-CT analysis of the tibia showed that the values of BV/TV, Tb.Th, and Tb.N in the OVX group were lower than in sham and OVX-ZOL

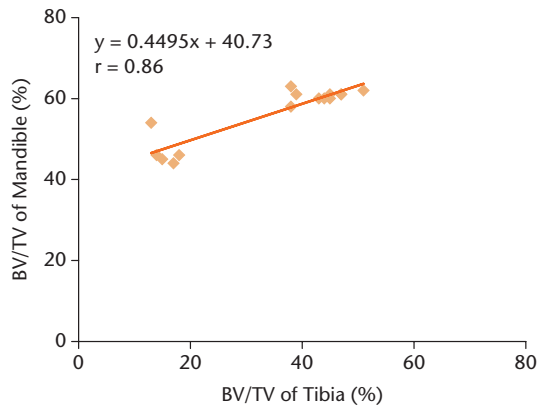


Fig. 6a

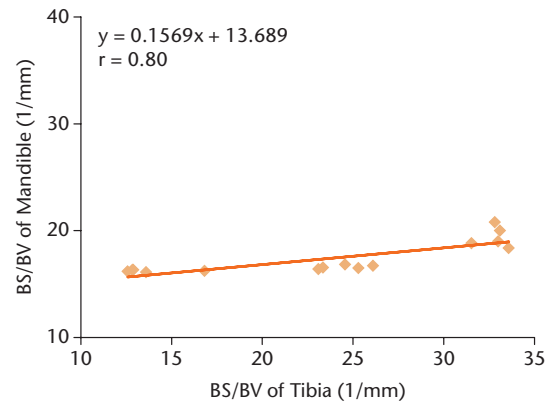


Fig. 6b

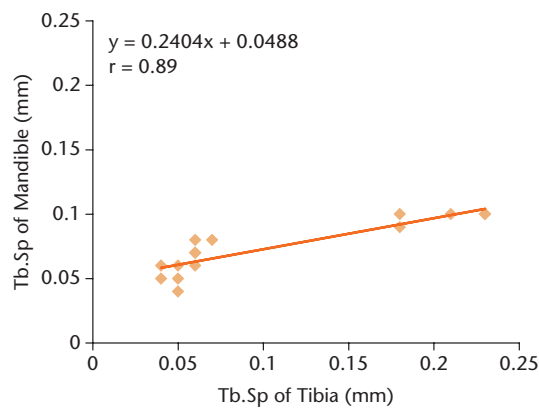


Fig. 6c

Correlations from the same histomorphometric parameters between the mandible and tibia by histological indices analysis; a) bone volume density; b) bone surface density; c) trabecular separation. A total of 15 specimens among sham, ovariectomised, and zoledronate-injected ovariectomised groups were used for correlations. All regressions were highly significant.

groups with the exception of the Tb.N of the OVX-ZOL group. Moreover, there were significant increases in BS/BV and Tb.Sp of the OVX group compared with sham and OVX-ZOL groups. However, the parameters of BV/TV and Tb.Th in the OVX-ZOL group were higher than that of the sham group. Meanwhile, the BS/BV in the OVX-ZOL group was lower than the sham group.

In undecalcified histological sections of the mandible, there were significant decreases in BV/TV and Tb.Dm of the OVX group compared with sham and OVX-ZOL groups. Moreover, the OVX group showed a dramatic increase in Tb.N and Tb.Sp compared with the sham group. The OVX-ZOL group showed a significant increase in Tb.N compared with the sham group. Meanwhile, in the OVX-ZOL group, Tb.Sp was dramatically decreased compared with the sham and OVX groups. Consistent with undecalcified histological sections, the micro-CT results of the mandible showed that the OVX group significantly decreased in BV/TV and Tb.Th and increased in BS/BV compared with the sham and OVX-ZOL groups. Of note, inconsistent with the tibia, the Tb.N of the mandible in the OVX group exhibited a significant increase compared with the sham group using both methods,

which might be associated with new bone lacunae of the alveolar septum induced by bone resorption in the mandible (Fig. 2a). The OVX-ZOL group showed a significant decrease in Tb.Sp compared with the OVX group. These aforementioned data further corroborate the finding that undecalcified histological sections and micro-CT have an excellent ability to evaluate OVX-induced osteoporosis and osteoporotic treatment. Moreover, consistent with the tibia, bone histomorphometry on the mandible also revealed the presence of osteoporosis or effect of osteoporotic treatment in an ovariectomised rat model.

## Discussion

Although quantitative structural comparison of histological sections and micro-CT using human bone biopsies has been investigated in several studies,<sup>11,13,15</sup> bone micro-architectural comparison of these two methods using rodent specimens has rarely been reported. Our analysis has indicated that the mean percentage differences in trabecular morphometric parameters are increased when the average width of rodent trabeculae is only a few micrometres compared with that of the human trabeculae (132.4  $\mu\text{m}$ , SD 27.9).<sup>25</sup> The results of the accuracy of micro-CT at different

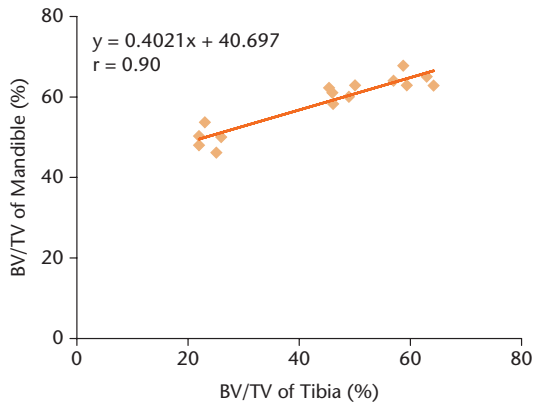


Fig. 7a

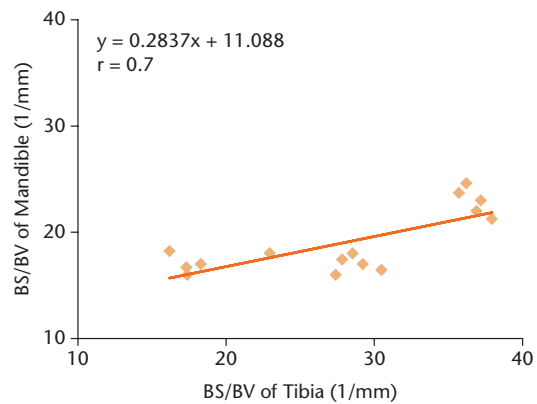


Fig. 7b

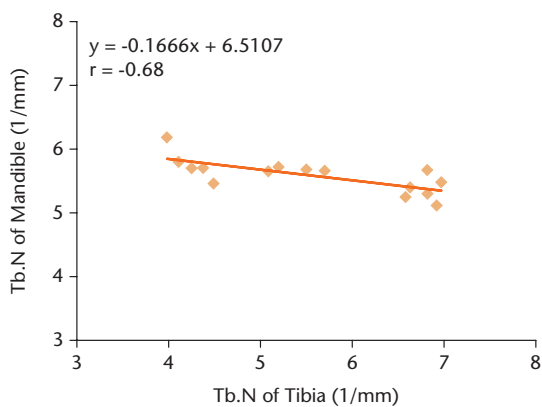


Fig. 7c

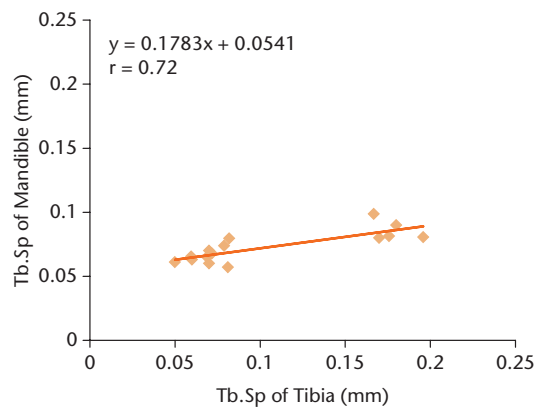


Fig. 7d

Correlations from the same histomorphometric parameters between the mandible and tibia by micro-CT analysis; a) bone volume density; b) bone surface density; c) trabecular number; d) trabecular separation. A total of 15 specimens among sham, ovariectomised, and zoledronate-injected ovariectomised groups were used for correlations. All regressions were highly significant.

scanning resolutions indicated that the radiographs became less clear as the scanning resolution decreased and that the histomorphometric parameters at the highest resolution were similar to the histological parameters. Consistent with our results, Müller et al<sup>26</sup> demonstrated that only the highest resolution could predict accurate values of human bone biopsies when very accurate results are required. Moreover, the accuracy for lower resolution data could decrease. In this respect, the micron-sized micro-CT may currently be the best available option, although inadequate to scan the bone trabeculae of rodent animals, therefore a higher resolution of micro-CT should be used in future. However, although varying accuracy appeared in the morphometric results when bone micro-architectural analysis of 2D and 3D data were compared, highly significant linear correlations between the two methods were found for the determination of both of the morphometric parameters. Meanwhile, stereology-based comparison of the trabecular bone structures on the mandible or tibia by a histological and the corresponding micro-tomographical section also provided visible evidence that the micro-CT system was functioning effectively for the evaluation of bone micro-architecture.

In this study, the mean percentage differences of all five morphometric parameters of the mandible were

lower than the tibia, although correlation coefficients were similar between both methods. Our analysis indicated that the discrepancy of accuracy between the mandible and tibia was mainly due to the cut direction and discontinuity of the undecalcified histological sections. Undecalcified histological sections were created by the EXAKT precision cutting and grinding system. Therefore, local bone tissues were grinded by specific sandpaper in one step. For the mandible, the sections were cut along the coronal plane (Fig. 1). In this plane, the micro-architecture of the alveolar trabeculae exhibited repeatability, although the trabeculae are irregular in each plane. However, the numbers of trabeculae in the central cancellous bone of the tibia are fewer than those of the peripheral cancellous bone in the tibia when the sections of tibia were conventionally cut along the coronal planes, especially in diseases of bone resorption such as osteoporosis (Fig. 8). Generally, the cutting sites of undecalcified histological sections on rats were more focused on the central cancellous bone in the tibia to avoid cutting the excessive cortical bone accidentally in a diameter of a few millimetres. Therefore, the BV/TV of the tibia that was calculated from the histological slices was underestimated compared with the 3D data from micro-CT, which



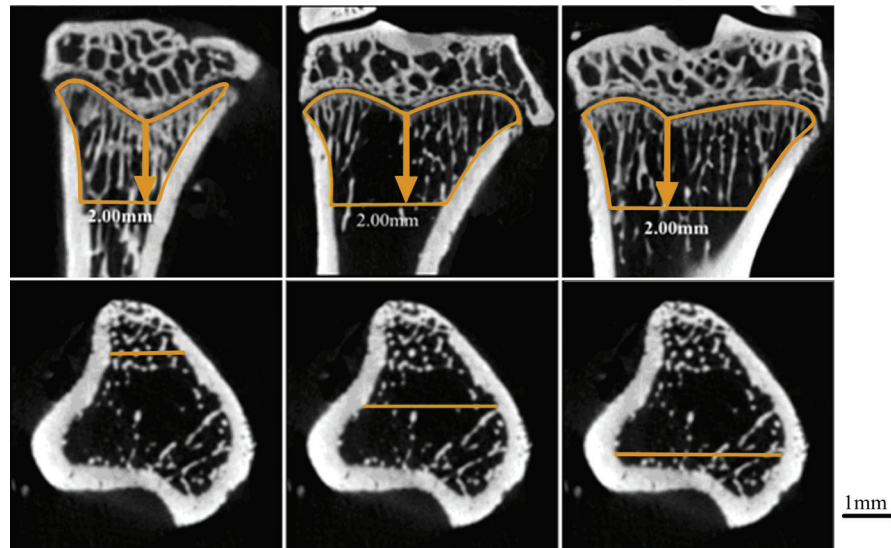


Fig. 8

Visual comparison of numbers of trabeculae between the central and peripheral cancellous bone of tibia in ovariectomised rats in coronal planes. The first row represents the trabeculae of coronal planes derived from different locations of cancellous bone in tibia (represents the front, middle, or back plane). The second row shows the transverse plane of tibia where the yellow lines mark the corresponding coronal locations in the first row for observation of cancellous structures. Scale bar = 1 mm.

showed a greater difference of BV/TV in the tibia between both methods than that of the mandible.

Yan, Pham and Crabbe<sup>27</sup> discovered that significant positive correlations were found in Tb.Sp and the structure model index (SMI) using micro-CT between mandible and tibia in an ovariectomised rat model. We previously reported that there were significant correlations in BS/BV, Tb.Th, and Tb.Sp by micro-CT between alveolar bone around the mandibular first molar and the proximal tibia among sham, OVX, and oestrogen-injected ovariectomised rats.<sup>17</sup> In order to confirm the conclusion, the correlations between mandible and tibia were evaluated by undecalcified histological sections and micro-CT, and our results demonstrated that there were significant correlations in BV/TV, BS/BV, and Tb.Sp between the mandible and tibia by both methods.

In this study, we found that both histological sections and micro-CT were effective in evaluating bone morphometry of osteoporosis and relative treatment. We also conclude that the mandible may be used as an effective site to assess the bone morphometry of OVX rats or other metabolic bone disease models, although the mandible had a smaller percentile reduction in BV/TV than the tibia in response to oestrogen deficiency. This difference might be associated with masticatory function of the jaws.<sup>28</sup> In order to investigate whether mandible can be used as an effective site to assess bone morphometry, further experiments are required.


Although there was a good correlation for morphometric parameters between micro-CT and undecalcified histological sections, much information could not be

provided by micro-CT, such as bone dynamics and the number of osteoblasts or osteoclasts. In this regard, micro-CT imaging cannot replace histology, but is complementary.

However, there are limitations to this study. One piece of undecalcified histological section was made from one specimen, which was one of the reasons for the difference between undecalcified histological sections and micro-CT, especially regarding the tibia. Sequential undecalcified histological sections will be made by a more advanced precision cutting and grinding system in further investigations.

In conclusion, this study has demonstrated for the first time that there are highly significant linear correlations between undecalcified histological sections and micro-CT bone micro-architectural analysis of the mandible and tibia in osteoporotic rodent models. Our data provide solid evidence for the application of micro-CT analysis in rodent animals of metabolic bone disease. In addition, we further confirmed that there were significant correlations of histological data between the mandible and tibia by two methods, and the mandible could be used as an alternative site to evaluate the bone morphometry of metabolic bone diseases.

### Supplementary material

 Tables showing further data on the histological and micro-tomographic parameters of the mandible can be found alongside the paper at <http://www.bjr.boneandjoint.org.uk/>

## References

- Rauch F.** Watching bone cells at work: what we can see from bone biopsies. *Pediatr Nephrol* 2006;21:457-462.
- Parfitt AM, Drezner MK, Glorieux FH, et al.** Bone histomorphometry: standardization of nomenclature, symbols, and units. Report of the ASBMR Histomorphometry Nomenclature Committee. *J Bone Miner Res* 1987;2:595-610.
- Liu Y, Wang L, Kikui T, et al.** Mesenchymal stem cell-based tissue regeneration is governed by recipient T lymphocytes via IFN- $\gamma$  and TNF- $\alpha$ . *Nat Med* 2011;17:1594-1601.
- Liu YS, Ou ME, Liu H, et al.** The effect of simvastatin on chemotactic capability of SDF-1 $\alpha$  and the promotion of bone regeneration. *Biomaterials* 2014;35:4489-4498.
- Cho SW, Sun HJ, Yang JY, et al.** Human adipose tissue-derived stromal cell therapy prevents bone loss in ovariectomized nude mouse. *Tissue Eng Part A* 2012;18:1067-1078.
- Chappard D, Baslé MF, Legrand E, Audran M.** Trabecular bone microarchitecture: a review. *Morphologie* 2008;92:162-170.
- Dalle Carbonare L, Valenti MT, Bertoldo F, et al.** Bone microarchitecture evaluated by histomorphometry. *Micron* 2005;36:609-616.
- Müller R, Rügsegger P.** Analysis of mechanical properties of cancellous bone under conditions of simulated bone atrophy. *J Biomech* 1996;29:1053-1060.
- Turner CH.** On Wolff's law of trabecular architecture. *J Biomech* 1992;25:1-9.
- Williams JL, Lewis JL.** Properties and an anisotropic model of cancellous bone from the proximal tibial epiphysis. *J Biomech Eng* 1982;104:50-56.
- Chappard D, Retailleau-Gaborit N, Legrand E, et al.** Comparison insight bone measurements by histomorphometry and microCT. *J Bone Miner Res* 2005;20:1177-1184.
- Fajardo RJ, Ryan TM, Kappelman J.** Assessing the accuracy of high-resolution X-ray computed tomography of primate trabecular bone by comparisons with histological sections. *Am J Phys Anthropol* 2002;118:1-10.
- Müller R, Van Campenhout H, Van Damme B, et al.** Morphometric analysis of human bone biopsies: a quantitative structural comparison of histological sections and micro-computed tomography. *Bone* 1998;23:59-66.
- Müller R, Hahn M, Vogel M, Delling G, Rügsegger P.** Morphometric analysis of noninvasively assessed bone biopsies: comparison of high-resolution computed tomography and histologic sections. *Bone* 1996;18:215-220.
- Thomsen JS, Laib A, Koller B, et al.** Stereological measures of trabecular bone structure: comparison of 3D micro computed tomography with 2D histological sections in human proximal tibial bone biopsies. *J Microsc* 2005;218:171-179.
- Aguirre JI, Akhter MP, Kimmel DB, et al.** Enhanced alveolar bone loss in a model of non-invasive periodontitis in rice rats. *Oral Dis* 2012;18:459-468.
- Liu H, Gao K, Lin H, Zhang Y, Li B.** Relative Skeletal Effects in Different Sites of the Mandible With the Proximal Tibia During Ovariectomy and the Subsequent Estrogen Treatment. *J Oral Implantol* 2015;41:386-390.
- Silva BC, Bilezikian JP.** New approaches to the treatment of osteoporosis. *Annu Rev Med* 2011;62:307-322.
- Liu H, Li W, Liu Y, Zhang X, Zhou Y.** Co-administration of aspirin and allogeneic adipose-derived stromal cells attenuates bone loss in ovariectomized rats through the anti-inflammatory and chemotactic abilities of aspirin. *Stem Cell Res Ther* 2015;6:200.
- Li B, Liu H, Jia S.** Puerarin enhances bone mass by promoting osteoblastogenesis and slightly lowering bone marrow adiposity in ovariectomized rats. *Biol Pharm Bull* 2014;37:1919-1925.
- Turner RT, Maran A, Lotinun S, et al.** Animal models for osteoporosis. *Rev Endocr Metab Disord* 2001;2:117-127.
- Mavropoulos A, Rizzoli R, Ammann P.** Different responsiveness of alveolar and tibial bone to bone loss stimuli. *J Bone Miner Res* 2007;22:403-410.
- Bouxsein ML, Boyd SK, Christiansen BA, et al.** Guidelines for assessment of bone microstructure in rodents using micro-computed tomography. *J Bone Miner Res* 2010;25:1468-1486.
- Dempster DW, Compston JE, Drezner MK, et al.** Standardized nomenclature, symbols, and units for bone histomorphometry: a 2012 update of the report of the ASBMR Histomorphometry Nomenclature Committee. *J Bone Miner Res* 2013;28:2-17.
- Recker RR, Kimmel DB, Parfitt AM, et al.** Static and tetracycline-based bone histomorphometric data from 34 normal postmenopausal females. *J Bone Miner Res* 1988;3:133-144.
- Müller R, Koller B, Hildebrand T, et al.** Resolution dependency of microstructural properties of cancellous bone based on three-dimensional mu-tomography. *Technol Health Care* 1996;4:113-119.
- Yang J, Pham SM, Crabbe DL.** Effects of oestrogen deficiency on rat mandibular and tibial microarchitecture. *Dentomaxillofac Radiol* 2003;32:247-251.
- Elovic RP, Hipp JA, Hayes WC.** Maxillary molar extraction causes increased bone loss in the mandible of ovariectomized rats. *J Bone Miner Res* 1995;10:1087-1093.

### Funding Statement

- Grants have been received for this study from the National Natural Science Foundation of China (81170937) and the Program for New Century Excellent Talents in University from Ministry of Education (NCET-11-0026).

### Author Contribution

- H. Liu: Study design, Data collection and analysis, Manuscript preparation.
- W. Li: Data collection and analysis, proofreading, Manuscript preparation.
- Y. S. Liu: Data collection and analysis.
- Y. S. Zhou: Study design, Manuscript preparation, Final approval of paper.

- Acknowledgement: \*H. Liu and W. Li contributed equally to this study.

### ICMJE conflict of interest

- None declared.

© 2016 Liu et al. This is an open-access article distributed under the terms of the Creative Commons Attribution licence (CC-BY-NC), which permits unrestricted use, distribution, and reproduction in any medium, but not for commercial gain, provided the original author and source are credited.