



■ LOWER LIMB

Induced membrane technique for the treatment of bone defects due to post-traumatic osteomyelitis

X. Wang,*
F. Luo,*
K. Huang,
Z. Xie

Southwest Hospital,
Third Military Medical
University, Chongqing,
China

■ X. Wang, MD, Orthopaedic Surgeon, National and Regional United Engineering Laboratory of Tissue Engineering, Department of Orthopaedics.

■ F. Luo, MD, Professor, National and Regional United Engineering Laboratory of Tissue Engineering, Department of Orthopaedics.

■ K. Huang, MD, Orthopaedic Surgeon, National and Regional United Engineering Laboratory of Tissue Engineering, Department of Orthopaedics.

■ Z. Xie, MD, Professor, Department of Orthopaedics, Southwest Hospital, Third Military Medical University, Gaotanyan No.30, Chongqing 400038, The People's Republic of China.

Correspondence should be sent to Dr Z. Xie; e-mail: xiezhao54981@163.com

doi:10.1302/2046-3758.53.2000487

Bone Joint Res 2016;5:101–105.

Received: 6 July 2015;

Accepted: 28 January 2016

Objectives

Induced membrane technique is a relatively new technique in the reconstruction of large bone defects. It involves the implantation of polymethylmethacrylate (PMMA) cement in the bone defects to induce the formation of membranes after radical debridement and reconstruction of bone defects using an autologous cancellous bone graft in a span of four to eight weeks. The purpose of this study was to explore the clinical outcomes of the induced membrane technique for the treatment of post-traumatic osteomyelitis in 32 patients.

Methods

A total of 32 cases of post-traumatic osteomyelitis were admitted to our department between August 2011 and October 2012. This retrospective study included 22 men and ten women, with a mean age of 40 years (19 to 70). Within this group there were 20 tibias and 12 femurs with a mean defect of 5 cm (1.5 to 12.5). Antibiotic-loaded PMMA cement was inserted into the defects after radical debridement. After approximately eight weeks, the defects were implanted with bone graft.

Results

The patients were followed for 27.5 months (24 to 32). Radiographic bone union occurred at six months for 26 cases (81%) and clinical healing occurred in 29 cases (90%) at ten months. A total of six cases had a second debridement before bone grafting because of recurrence of infection and one patient required a third debridement. No cases of osteomyelitis had recurred at the time of the last follow-up visit.

Conclusion

The induced membrane technique for the treatment of post-traumatic osteomyelitis is a simple, reliable method, with good early results. However, there are many challenges in determining the scope of the debridement, type of limb fixation and source of bone graft to be used.

Cite this article: *Bone Joint Res* 2016;5:101–105

Keywords: induced membrane; post-traumatic; osteomyelitis; bone defects; bioreactor

Introduction

Post-traumatic osteomyelitis is currently one of the greatest challenges faced by orthopaedic surgeons. Bacteria on the biofilm surface of an implant or bone are protected from the host immune system and from systemic antibiotics; therefore the basis of successful treatment is the removal of the implant and sequestrum.¹ The surgical procedure can create bone defects,² therefore the ultimate goal of the treatment of post-traumatic osteomyelitis is to eradicate infection, and also to reconstruct associated bone defects successfully. Fleiter et al³ reported using gentamicin-releasing resorbable bone

graft substitute in the treatment of osteomyelitis, with a remission of infection for 80% patients.

The induced membrane technique was first reported by Masquelet et al⁴ for use in the reconstruction of large bone defects with a two-stage surgical process; all of the 35 cases treated achieved bony union within four months. This method for the treatment of post-traumatic segmental defects has not been previously reported in post-traumatic osteomyelitis. The purpose of this study was to evaluate the clinical outcome of 32 cases of post-traumatic osteomyelitis treated in our department with the induced membrane technique.

Patients and Methods

After gaining Institutional Review Board approval, we retrospectively reviewed the medical records of all of the patients treated at our institution with the induced membrane technique between August 2011 and October 2012. The confirmation of osteomyelitis used several diagnostic criteria: history of open fracture or surgery; draining fistula; local bone pain and swelling on examination; imaging procedures; microbiology and histopathology; and laboratory studies.⁵ Diagnosis of osteomyelitis was mainly based on the Osteomyelitis Diagnosis Score (ODS).⁶ Data collected included injury type, lesion location, bacteria isolated, Cierny-Mader host stages, length of bone defects and type of fixation.

A total of 36 patients were treated for post-traumatic osteomyelitis with the induced membrane technique. One was excluded due to an unrelated death and three were lost to follow-up. Therefore, 32 patients were reviewed (22 men and ten women), with a mean age of 40 years (19 to 70). There were no cases of diabetes or rheumatoid arthritis. A total of 28 patients were classified as Cierny-Mader type A and four as type B. There were 20 cases in the tibia and 12 cases in the femur treated for a mean defect of 5 cm (1.5 to 12.5). The mean duration of bone infection was 1.6 years (3 months to 20 years) and the mean number of operations was 3.7 from the initial injury to our first debridement. In total, 26 patients presented with obvious sinus and pus. Another common clinical presentation was prolonged limb pain following fracture fixation, with imaging confirming bone loss. Necrotic tissue (sequestrum and inflammatory tissue) were found intra-operatively and frozen sections confirmed more than five neutrophils per high-power field; suggestive of infection. In some cases, a positive culture confirmed osteomyelitis.

In all, 20 patients (62.5%) were found to have positive tissue cultures (Table I). The remaining 12 patients with negative cultures had draining sinus tracts and intra-operative bone tissue pathology which was suggestive of suppurative inflammation. The negative culture may be associated with long-term antibiotic treatment or improper handling of specimens.¹

We treated all patients with radical debridement based on the size of the lesion as indicated by the pre-operative imaging which included radiographs, CT, MRI and/or bone scintigraphy examinations. All necrotic soft tissue and bone was debrided until healthy bleeding bone was identified,⁷ The sequestrum and surrounding soft tissue were sent for culture and the debrided wound was extensively irrigated. The medullary canal was reamed for patients with intramedullary infection. The defects were stabilised with a 4.5 mm locking compression plate (LCP) and external fixation, or an external fixation only. The plate was placed on the lateral side of the femur or anteromedial aspect of the tibia. The LCP was stabilised with three locking screws at each end. The bone defects were filled with 40 g of gentamicin polymethyl methacrylate

Table I. Details of pathogens.

Pathogen	n
<i>Staphylococcus aureus</i>	9
<i>Staphylococcus epidermidis</i>	2
<i>Pseudomonas aeruginosa</i>	3
<i>Enterococcus faecalis</i>	3
<i>Escherichia coli</i>	1
Other	4

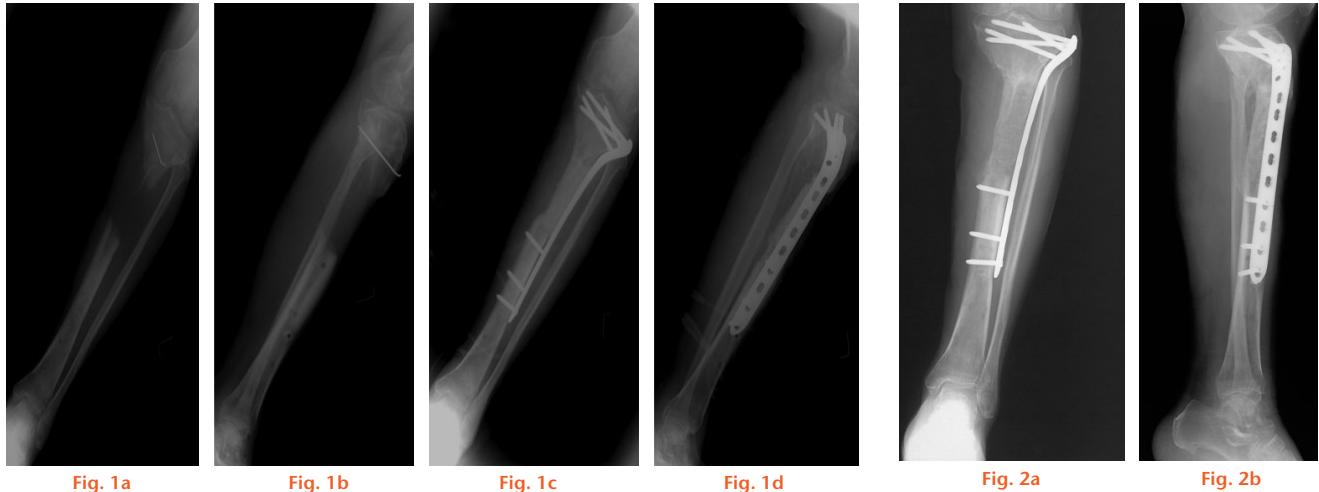
(PMMA Heraeus, Germany) bone cement mixed with 5 g of vancomycin powder (Fig. 1).

A total of five patients required soft-tissue coverage with a myocutaneous, fasciocutaneous, or free flap. Multiple debridements were required in some cases. A third-generation cephalosporin (Ceftazidime, Hailin, China) was administered at a dose of 2 g intravenous every 12 hours until culture results were available. Intravenous antibiotics (culture directed or empirical with negative cultures) were continued for ten to 14 days post-operatively with no oral antibiotics. A suction drain was in place for five to ten days.

Bone grafting was performed six to eight weeks later. This was delayed for two or three weeks further if the skin or soft-tissue quality was poor. For example, if there was skin crusting or poor tissue flexibility. The following signs were used as markers of recurrent infection; redness, swelling, pain, sinus and pus at the involved site and frozen sections intra-operatively demonstrating acute inflammation. Systemically, raised white blood cell count, C-reactive protein and/or Erythrocyte sedimentation rate were used to aid in the diagnosis of infection. If these signs suggested that there was recurrent infection, a repeat debridement was performed. The mean interval between the first stage and the second stage was 62 days (42 to 98).

The length and width of the defects was measured on the CT scan and used to calculate the amount of bone graft needed.⁸ Autologous bone was harvested from the iliac crest and implanted into the defect. If there was an insufficient volume of autologous bone, allograft bone was added, ensuring that the ratio of allograft was less than one third of the total volume.⁹ In this series, a mean of 48 cm³ (28 to 60) autogenous bone was obtained from the posterior iliac crest of one side and a mean of 15 cm³ (8 to 20) was obtained from a single anterior iliac crest. The graft was then cut into fragments approximately 0.5 cm × 0.5 cm × 0.5 cm in size. The previous incision at the defect site was then re-opened and the bone cement was carefully removed, ensuring that the surrounding induced membrane was protected. The bone ends were freshened and the bone graft was implanted into the defect. The induced membrane was then sutured over the graft with an indwelling drain. Systemic antibiotics were given for 24 hours but topical antibiotics were not used in the second stage.

Patients were followed up every three months and assessed for control of infection, pain, oedema, limb length/



Radiographs showing patient 12 - male, 55 yrs, with chronic osteomyelitis for eight months following a car accident. a) and b) pre-operatively, showing left tibial osteomyelitis with bone defect and c) and d), antibiotic bone cement implanted after debridement.

Radiographs showing callus formation three months after the grafting.

deformity, range of movement of the ankle and knee and weight bearing. (Progressive weight bearing was permitted as soon as callus was evident on the radiographs.)

An excellent outcome was defined as bone union, free from infection, deformity $< 7^\circ$ and leg-length discrepancy < 2.5 cm.¹⁰ Radiographic healing was defined as bridging callus on three or more cortices and clinical healing was defined as pain-free full weight-bearing and lack of tenderness on physical examination. When radiographic union was in doubt, CT scans were obtained to delineate the extent of bone healing more clearly.⁸ Control of infection was judged using a combination of clinical findings and laboratory parameters, specifically, the absence of a sinus, pus, erythema and tenderness and normalisation of the laboratory parameters.¹¹

Results

The mean follow-up was 27.5 months (24 to 32). All of the patients achieved bone union (Figs 2 and 3). The mean size of bone defect was 42 cm³ (9 to 136). The mean radiographic bone healing time was 4.9 months (three to nine), clinical healing time (pain-free full weight bearing) was 7.5 months (four to 14). Radiographic bone union had occurred by six months for 26 cases (81%) and clinical healing had occurred by ten months in 29 cases (90%). All of the patients were free of osteomyelitis at the last follow-up (24 to 32 months) with normalisation of their inflammatory makers. Six cases required a second debridement before bone grafting because of recurrent infection. One case needed a third debridement before grafting. Five cases suffered from pin-tract infection, which resolved after removal of the external fixation or with local disinfection. Two patients developed iliac crest infection, which needed surgical treatment and ten patients suffered from iliac pain or discomfort for about six months. One patient had prolonged ankle stiffness and one patient had bone deformity as a result of

unstable fixation. Lower extremity oedema occurred with standing in 21 cases. These patients were advised to wear elastic stockings, elevate their limb to reduce oedema and reduce their activities appropriately. In most of these patients there was a reduction of the oedema by four months (Tables II and III).

Discussion

Treatment of post-traumatic osteomyelitis is difficult, requiring stable fixation, elimination of dead space, soft-tissue coverage, effective drainage and appropriate antibiotics to control bone infection.¹² Reconstruction of the bone defect is the main issue after infection control. Masquelet et al⁴ first reported 35 cases of bone defects treated with the induced membrane technique and achieved good clinical efficacy and O'Malley and Kates¹³ reported a 17 cm bone defect followed by MRSA infection which was successfully treated with the induced membrane technique.

Individualised treatment programmes are important for patients with post-traumatic osteomyelitis; in general, palliative care strategies are suitable for patients classified as Cierny-Mader C hosts, while more radical tactics should be used for A and B hosts.¹⁴ In this study there were 20 tibial cases and 12 femoral which were treated using this strategy. Five tibial cases had a problem with skin coverage and required some form of plastic surgery, whereas in femoral cases this was rarely a problem. More bone cement was needed to fill the dead space for the femoral defects. To increase the amount of antibiotic released from the bone cement, antibiotic powder was added to the distilled water before mixing with bone cement.¹⁵ Our preferred method of fixation for the femur at the second stage was intramedullary nailing.

A versatile model of open-fracture infection has been successfully built in animals.¹⁶ Bacteria within a biofilm are protected against the killing action of antibiotics and the body's

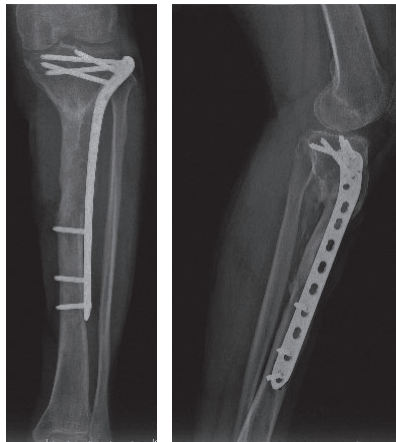

Fig. 3a

Fig. 3b

Radiographic examination showed bone union 25 months after the second stage.

immune system.¹² Bacteria can also enter osteoblasts and fibroblasts by some mechanism which is not yet fully understood.¹⁷ Both biofilm formation and the cellular internalisation of bacteria make bone infection difficult to control by conventional drainage and antibiotic therapy. Therefore debridement is the foundation of treatment and the necessary therapeutic step for controlling bone infection for most patients. The main complication of this technique is recurrent infection caused by incomplete debridement.¹⁸ Six patients recurred after the first stage and required another debridement in this study, because of incomplete initial debridement. Currently, the 'paprika sign' is used to determine the extent of bone resection, but it may have limitations. We used pre-operative radiographs, CT scans and MRIs to determine the extent of the lesions. In some patients, radioactive nuclide imaging was useful for resection planning and localising the sequestrum, especially for those with metal plants in whom MRI was not useful.^{19,20}

Masquelet et al⁴ found that fibrin and laminin gathered at the surface of bone cement, a white membrane formed eight months after implantation of PMMA. This membrane was considered to be able to induce bone union within four months, regardless of the length of the bone defect. The mean radiographic time to bone union was 4.9 months in this study, which was near to the reported results. A number of clinical studies have reported that the induced membrane technique has advantages.²¹⁻²⁵ The induced membrane is thought to promote bone healing by the secretion of a variety of osteogenic growth factors and angiogenesis related factors.²⁶⁻²⁹ This is similar to the approach in tissue engineering and indeed in 2005, Stevens et al³⁰ proposed the concept of an *in vivo* bioreactor. The 'watertight' induced membrane chamber can be considered to be a complex bioreactor, continuously providing osteogenetic factors, cells as well as a blood supply for bone graft. This is considered to be the reason why induced membrane can quickly repair bone defects. However, further research is needed on the nature of this *in vivo* bioreactor.

Table II. Evaluation of the results.

Results	Tibia	Femur	Total	Criteria
Excellent	12	8	20	Union, no infection, deformity < 7°, limb length discrepancy (LLD) < 2.5 cm
Good	6	3	9	Union plus any two of the following: absence of infection, deformity < 7°, LLD < 2.5 cm
Fair	2	1	3	Union plus any one of the following: absence of infection, deformity < 7°, LLD < 2.5 cm
Poor	0	0	0	Nonunion/refracture/union plus infection plus deformity > 7° plus LLD > 2.5 cm

Table III. Details of complications.

Complications	Cases
Pin-tract infection	5
Iliac crest infection	2
Iliac pain	10
Ankle stiffness	1
Deformity connection	3
Oedema	21

Induced membrane technique must be combined with stable fixation, as instability may lead to deformity or non-union.³¹ Indeed, unstable fixation resulted in deformity in one case in this study. The average time to full weight bearing was relatively late at 7.5 months, which had a great impact on the patients' daily life. Aparad et al³² reported 12 cases of tibial infections, initially treated with an intramedullary nail. Most patients obtained bone union, but five patients recurred between eight months and two years after the second stage, which was treated by removal of the nail or a prolonged course of antibiotics. Similarly, Tsang et al³³ reported that in cases of infected tibial nonunion after IM nailing, the majority of patients needed two or more nail exchanges to clear the infection and stress the importance of the patient being made aware that they are likely to need at least two stages when an IM nail is used in order to stabilise an infected tibia.

To avoid biofilm formation and to create a complete induced membrane, we consider that the steel surface should be completely covered with the antibiotic cement. The use of locking plates has previously been reported^{34,35} and we used them to replace external fixators for temporary fixation. However, at the second stage (grafting), intramedullary nail was used whenever possible in order to ensure strong fixation and to allow an early return to exercises.

The insufficient bone source is an important factor restricting the reconstruction of large bone defects, autograft has long been the benchmark because of its osteoinductive and osteoconductive properties,⁹ but the iliac crest infections and post-operative pain demand that we search for new alternatives. The RIA system acquires the graft from the canal of the femur, which has been suggested to cause fewer complications and acquire material with a higher osteogenic ability.²³ Tissue-engineered bone has attracted more attention in recent years, but is still faced with constraints such as vascularisation. The vascular conditions of

induced membrane, along with tissue engineered bone, may offer an exciting combination for the future. Reports have shown a good ability of tissue-engineered bone to induce osteogenesis in the induced membrane with animal models³⁶ and Hesse et al³⁷ successfully repaired a 7.2 cm segmental tibial defect with induced membrane and bone tissue engineering. Once bone tissue engineering combined with the induced membrane technique has been demonstrated to be a reliable efficacious clinical treatment for large bone defects, it has the potential to be of value in a wide range of patients.

Supplementary material



A table showing patient demographics is available alongside the online version of this article at www.bjr.boneandjoint.org.uk.

References

- Patzakis MJ, Zalavras CG. Chronic posttraumatic osteomyelitis and infected nonunion of the tibia: current management concepts. *J Am Acad Orthop Surg* 2005;13:417-427.
- Dinh P, Hutchinson BK, Zalavras C, Stevanovic MV. Reconstruction of osteomyelitis defects. *Semin Plast Surg* 2009;23:108-118.
- Fleiter N, Walter G, Bösebeck H, et al. Clinical use and safety of a novel gentamicin-releasing resorbable bone graft substitute in the treatment of osteomyelitis/osteitis. *Bone Joint Res* 2014;3:223-229.
- Masquelet AC, Fitoussi F, Begue T, Muller GP. [Reconstruction of the long bones by the induced membrane and spongy autograft]. *Ann Chir Plast Esthet* 2000;45:346-353. (In French)
- Low DP, Waldvogel FA. Osteomyelitis. *Lancet* 2004;364:369-379.
- Schmidt HG, Tiemann AH, Braunschweig R, et al. (Definition of the Diagnosis Osteomyelitis-Osteomyelitis Diagnosis Score (ODS)). *Z Orthop Unfall* 2011;149:449-460. (In German.)
- Simpson AH, Deakin M, Latham JM. Chronic osteomyelitis. The effect of the extent of surgical resection on infection-free survival. *J Bone Joint Surg [Br]* 2001;83-B:403-407.
- Stafford PR, Norris BL. Reamer-irrigator-aspirator bone graft and bi Masquelet technique for segmental bone defect nonunions: a review of 25 cases. *Injury* 2010;41:S72-S77.
- Taylor BC, French BG, Fowler TT, Russell J, Poka A. Induced membrane technique for reconstruction to manage bone loss. *J Am Acad Orthop Surg* 2012;20:142-150.
- Yin P, Zhang L, Li T, et al. Infected nonunion of tibia and femur treated by bone transport. *J Orthop Surg Res* 2015;10:49.
- Leung AH, Hawthorn BR, Simpson AH. The Effectiveness of Local Antibiotics in Treating Chronic Osteomyelitis in a Cohort of 50 Patients with an Average of 4 Years Follow-Up. *Open Orthop J* 2015;9:372-378.
- Cierny G III. Surgical treatment of osteomyelitis. *Plast Reconstr Surg* 2011;127:190S-204S.
- O'Malley NT, Kates SL. Advances on the Masquelet technique using a cage and nail construct. *Arch Orthop Trauma Surg* 2012;132:245-248.
- Cierny G III, Mader JT, Penninck JJ. A clinical staging system for adult osteomyelitis. *Clin Orthop Relat Res* 2003;414:7-24.
- Chang YH, Tai CL, Hsu HY, et al. Liquid antibiotics in bone cement: an effective way to improve the efficiency of antibiotic release in antibiotic loaded bone cement. *Bone Joint Res* 2014;3:246-251.
- Penn-Barwell G., Rand B. C. C., Brown K. V., Wenke J. C. A versatile model of open-fracture infection. *J Bone Joint Surg* 2014;3:187-192.
- Ellington JK, Harris M, Hudson MC, et al. Intracellular Staphylococcus aureus and antibiotic resistance: implications for treatment of staphylococcal osteomyelitis. *Journal Orthop Res* 2006, 24:87-93.
- Flamans B, Pauchot J, Petite H, et al. [Use of the induced membrane technique for the treatment of bone defects in the hand or wrist, in emergency]. *Chir Main* 2010;29:307-314 (In French.)
- Aigner RM, Fueger GF, Ritter G. Results of three-phase bone scintigraphy and radiography in 20 cases of neonatal osteomyelitis. *Nucl Med Commun* 1996;17:20-28.
- Nadel HR. Bone scan update. *Semin Nucl Med* 2007;37:332-339.
- Cuthbert RJ, Churchman SM, Tan HB, et al. Induced periosteum a complex cellular scaffold for the treatment of large bone defects. *Bone* 2013;57:484-492.
- Accadbled F, Mazeau P, Chotel F, et al. Induced-membrane femur reconstruction after resection of bone malignancies: three cases of massive graft resorption in children. *Orthop Traumatol Surg Res* 2013;99:479-483.
- Karger C, Kishi T, Schneider L, Fitoussi F, Masquelet AC, French Society of Orthopaedic Surgery and Traumatology (SoFCOT). Treatment of posttraumatic bone defects by the induced membrane technique. *Orthop Traumatol Surg Res* 2012;98:97-102.
- Chotel F, Nguiabanda L, Braillon P, et al. Induced membrane technique for reconstruction after bone tumor resection in children: a preliminary study. *Orthop Traumatol Surg Res* 2012;98:301-308.
- Zappaterra T, Ghislandi X, Adam A, et al. [Induced membrane technique for the reconstruction of bone defects in upper limb. A prospective single center study of nine cases]. *Chir Main* 2011;30:255-263. (In French.)
- Pelissier P, Masquelet AC, Bareille R, Pelissier SM, Amedee J. Induced membranes secrete growth factors including vascular and osteoinductive factors and could stimulate bone regeneration. *J Orthop Res* 2004;22:73-79.
- Aho OM, Lehenkari P, Ristiniemi J, et al. The mechanism of action of induced membranes in bone repair. *J Bone Joint Surg [Am]* 2013;95-A:597-604.
- Christou C, Oliver RA, Yu Y, Walsh WR. The Masquelet technique for membrane induction and the healing of ovine critical sized segmental defects. *PLoS One* 2014;9:e114122.
- Yin Q, Sun Z, Gu S. Progress of Masquelet technique to repair bone defect. *Chinese Journal of Reparative And Reconstructive Surgery* 2013;27:1273-1276. (English Abstract)
- Stevens MM, Marini RP, Schaefer D, et al. In vivo engineering of organs: the bone bioreactor. *Proc Natl Acad Sci U S A* 2005;102:11450-11455.
- Villemagne T, Bonnard C, Accadbled F, et al. Intercalary segmental reconstruction of long bones after malignant bone tumor resection using primary methyl methacrylate cement spacer interposition and secondary bone grafting: the induced membrane technique. *J Pediatr Orthop* 2011;31:570-576.
- Apard T, Bigorre N, Cronier P, et al. Two-stage reconstruction of post-traumatic segmental tibia bone loss with nailing. *Orthop Traumatol Surg Res* 2010;96:549-553.
- Tsang STJ, Mills LA, Baren JP, et al. Exchange nailing for tibial diaphyseal fracture nonunions: risk factors for failure. *Bone Joint J* 2016;98-B:534-541.
- Tulner SA, Strackee SD, Kloen P. Metaphyseal locking compression plate as an external fixator for the distal tibia. *Int Orthop* 2012;36:1923-1927.
- Ma CH, Wu CH, Tu YK, Lin TS. Metaphyseal locking plate as a definitive external fixator for treating open tibial fractures—clinical outcome and a finite element study. *Injury* 2013;44:1097-1101.
- Viateau V, Bensidhoum M, Guillemin G, et al. Use of the induced membrane technique for bone tissue engineering purposes: animal studies. *Orthop Clin North Am* 2010;41:49-56.
- Hesse E, Kluge G, Atfi A, et al. Repair of a segmental long bone defect in human by implantation of a novel multiple disc graft. *Bone* 2010;46:1457-1463.

Funding Statement

This work was supported by the National Basic Research Program of China (973 program, no. 2010CB529406), and the Funding of State Key Laboratory of Trauma, Burns and Combined Injury (SKLKF201313), Key Project of Logistics Research Plan of PLA (BWS13C014).

Author Contributions

- X. Wang, Data collection, Writing the paper, Data analysis, Performed surgeries.
- F. Luo, Data collection, Data analysis, Performed surgeries, Writing the paper
- K. Huang, Data collection.
- Z. Xie, Overall planning, Data analysis, Performed surgeries.

*These authors contributed equally to the manuscript.

ICMJE conflict of interest

- None declared.

© 2016 Xie et al. This is an open-access article distributed under the terms of the Creative Commons Attribution License (CC-BY-NC), which permits unrestricted use, distribution, and reproduction in any medium, but not for commercial gain, provided the original author and source are credited.