



■ ONCOLOGY

Radiodynamic therapy with acridine orange local administration as a new treatment option for primary and secondary bone tumours

**Y. Matsuyama,
T. Nakamura,
K. Yoshida,
T. Hagi,
T. Iino,
K. Asanuma,
A. Sudo**

*From Mie University,
Tsu, Japan*

Aims

Acridine orange (AO) demonstrates several biological activities. When exposed to low doses of X-ray radiation, AO increases the production of reactive radicals (radiodynamic therapy (AO-RDT)). We elucidated the efficacy of AO-RDT in breast and prostate cancer cell lines, which are likely to develop bone metastases.

Methods

We used the mouse osteosarcoma cell line LM8, the human breast cancer cell line MDA-MB-231, and the human prostate cancer cell line PC-3. Cultured cells were exposed to AO and radiation at various concentrations followed by various doses of irradiation. The cell viability was then measured. In vivo, each cell was inoculated subcutaneously into the backs of mice. In the AO-RDT group, AO (1.0 µg) was locally administered subcutaneously around the tumour followed by 5 Gy of irradiation. In the radiation group, 5 Gy of irradiation alone was administered after macroscopic tumour formation. The mice were killed on the 14th day after treatment. The change in tumour volume by AO-RDT was primarily evaluated.

Results

The viability of LM8, MDA-MB-231, and PC-3 cells strongly decreased at AO concentration of 1.0 µg/ml and a radiation dose of 5 Gy. In xenograft mouse model, the AO-RDT also showed a strong cytotoxic effect on tumour at the backside in osteosarcoma, breast cancer, and prostate cancer. AO-RDT treatment was more effective for tumour control than radiotherapy in breast cancer.

Conclusion

AO-RDT was effective in preventing the proliferation of osteosarcoma, breast cancer, and prostate cancer cell lines in vitro. The reduction in tumour volume by AO-RDT was also confirmed in vivo.

Cite this article: *Bone Joint Res* 2022;11(10):715–722.

Keywords: Acridine orange, Radiodynamic therapy, Bone metastasis

Article focus

- We hypothesized that radiodynamic therapy using acridine orange (AO-RDT) could be effective against breast and prostate cancer cell lines, which are likely to develop bone metastases.
- We elucidated the efficacy of AO-RDT in those cell lines using in vitro and in vivo studies.

Key messages

- AO-RDT was effective in preventing the proliferation of osteosarcoma, breast cancer, and prostate cancer cell lines both in vitro and in vivo.
- The reduction in tumour volume by AO-RDT was also confirmed in vivo.

Correspondence should be sent to Tomoki Nakamura; email: tomoki66@clin.medic.mie-u.ac.jp

doi: 10.1302/2046-3758.1110.BJR-2022-0105.R2

Bone Joint Res 2022;11(10):715–722.

Strengths and limitations

- We believe that we are the first to report the efficacy of AO-RDT in breast and prostate cancer cell lines, which are likely to develop bone metastases.
- Our lack of power calculation and lack of reporting side effects of the AO-RDT should be addressed in future studies.

Introduction

Acridine orange (AO), a fluorescent dye extracted from coal tar, demonstrates several biological activities. AO emits fluorescence after excitation with blue light (466.5 nm).^{1,2} AO also has a strong cytotoxic effect on cancer cells after strong light excitation or X-ray irradiation.^{3,4} When AO is excited by strong light, it produces an excited singlet state that can lose energy via fluorescence or cross the intersystem barrier to the triplet state, which can then undergo an energy-transfer mechanism to triplet oxygen, producing single oxygen. AO accumulates in acidic environments. Cancer cells with many large acidic vesicles readily absorb AO, whereas normal cells with basic environments and weakly acidic lysosomes quickly exclude AO.^{2,5} It has been clarified that the inhibition of V-ATPase activity by bafilomycin causes a decrease in AO accumulation into the lysosome, suggesting that AO accumulates into the lysosome in an acidity-dependent manner.^{5,6} Previous studies have shown that AO quickly accumulates in mouse osteosarcoma cells as well as in normal cells in muscles or adipose tissue after intraperitoneal injection, and AO was subsequently excluded from normal cells within two hours, but not from tumour cells.² Therefore, AO remains in the tumour cells longer than in the normal cells. When exposed to low doses of radiograph radiation, AO also increases the production of reactive radicals.⁴ Kusuzaki et al¹ and Satonaka et al^{3,7} developed photodynamic and radiodynamic therapies with AO (AO-PDT and AO-RDT) using *in vitro* and *in vivo* studies. In addition, other studies observed excellent clinical outcomes in patients with bone and soft-tissue sarcomas who received AO-PDT and AO-RDT.^{8–10} AO-PDT and AO-RDT using 1.0 µg/ml of AO were effective for acquiring local tumour control in patients with high-grade sarcoma such as osteosarcoma, chondrosarcoma, synovial sarcoma, and undifferentiated pleomorphic sarcoma.^{8,10} Nakamura et al⁹ reported that the five- and ten-year local recurrence-free rates were 78.9% and 73.3%, respectively, in patients with high-grade soft-tissue sarcoma who received AO-PDT and AO-RDT after intralesional and marginal tumour resection. However, preliminary and clinical studies for the use of AO-RDT for cancer are lacking. It has been noted that 70% of patients with breast or prostate cancer develop bone metastasis.¹¹ Metastatic bone tumours are common and may lead to severe complications. These include skeletal-related events, such as pain, impaired mobility, hypercalcaemia, pathological fracture, and spinal nerve compression, all of which can have an impact on the function and quality of life of the patient.¹² The current therapeutic options

for metastatic bone tumours mainly include a combination of radiotherapy with anticancer drugs and/or bone-modifying drugs, but a number of patients eventually develop more aggressive malignant forms that are resistant to the most commonly used treatments.^{13,14} We hypothesized that AO-RDT could be effective for breast and prostate cancer cell lines as well as osteosarcoma cell lines. To this end, we elucidated the efficacy of AO-RDT in those cell lines using *in vitro* and *in vivo* studies.

Methods

Tumour cell lines. In this study, we used the mouse osteosarcoma cell line LM8, the human breast cancer cell line MDA-MB-231 (American Type Culture Collection (ATCC), USA), and the human prostate cancer cell line PC-3 (European Collection Of Authenticated Cell Cultures (ECACC), UK). The mouse LM8 cell line was kindly provided by Osaka University (Japan, December 2014). LM8 cells were cultured in Minimum Essential Medium (MEM; Gibco, Thermo Fisher Scientific, USA) containing 10% fetal bovine serum, MDA-MB-231 cells were cultured in Roswell Park Memorial Institute (RPMI)-1640 medium (Gibco, Thermo Fisher Scientific) containing 10% fetal bovine serum, and PC-3 cells were cultured in MEM containing 10% fetal bovine serum and 18 mg/l inositol in a humidified atmosphere and 5% CO₂ at 37°C.

In vitro study. The LM8, MDA-MB-231, and PC-3 cells were seeded (5×10^3 cells/well) in 96-well plates with 50 µl medium and incubated at 37°C in a 5% CO₂ atmosphere. All experiments were conducted after 24 hours of cell culture. The cells were divided into nine groups ($n = 7$): 1) groups 1 to 3 received no irradiation and were exposed to different concentrations of AO (group 1, AO-free medium; group 2, 0.1 µg/ml AO; group 3, 1.0 µg/ml AO); 2) groups 4 to 6 received 3 Gy of irradiation and were exposed to different concentrations of AO (group 4, AO-free medium; group 5, 0.1 µg/ml AO; group 6, 1.0 µg/ml AO); and 3) groups 7 to 9 received 5 Gy of radiation and were exposed to different concentrations of AO (group 7, AO-free medium; group 8, 0.1 µg/ml AO; group 9, 1.0 µg/ml AO). At the beginning of the treatment (0 hrs), the medium in each well was supplemented with 50 µl medium containing different concentrations of AO (0.1 or 1.0 µg/ml) or 50 µl AO-free medium. The viability ratios of LM8, MDA-MB-231, and PC-3 cells in each well were assessed at six, 24, and 48 hours. Cell viability was measured using the Cell-Titer 96 Aqueous One Solution Cell Proliferation Assay (G3581; Promega Corporation, USA).

In vivo study. LM8 cells (2×10^6), isolated by performing trypsinization, were inoculated subcutaneously into the backs of C3H/HeSlc mice (five-week-old males); similarly, BALB/cSlc-*nu/nu* mice (five-week-old males) were inoculated with MDA-MB-231 and PC-3 cells. After macroscopic tumour formation (5 mm in diameter), the following experiments were performed. The tumour volume (V) was calculated using the following equation: $V = \pi \times (\text{major axis}) \times (\text{minor axis})^2 / 6$.¹⁵ The following four

groups were generated ($n = 5$). The control group was left untreated, and the treatment groups received the following treatments: AO-RDT group (AO 1.0 $\mu\text{g/ml}$ and 5 Gy), AO group (AO 1.0 $\mu\text{g/ml}$), and radiotherapy group (5 Gy). AO (1.0 ml) was locally administered subcutaneously around the tumour at a concentration of 1.0 $\mu\text{g/ml}$. The AO group received only local administration. By contrast, the mice in the AO-RDT and radiation group were also administered anaesthesia, using a combination of anaesthetics and 5 Gy radiation. A combination of anaesthetics was prepared using 0.75 mg/kg of medetomidine, 4.0 mg/kg of midazolam, and 5.0 mg/kg of butorphanol. The actual amount adjusted was 1.875 ml medetomidine, 2 ml midazolam, 2.5 ml butorphanol, and 18.625 ml physiological saline for a total of 25 ml. The mice were administered 10 $\mu\text{l/g}$ of mouse body weight anaesthetic by intraperitoneal injection. Then, body weight and tumour diameter were measured twice a week and the mice were killed on the 14th day after treatment, and the tumour tissue was resected for evaluation in all groups. All mice in every group survived to the study endpoint of 14 days. The primary purpose of this *in vivo* study was to confirm the change in tumour volume after the treatment.

Immunohistochemical staining. The mouse breast cancer cell line was stained with antibodies against Ki67 (clone MIB-1: human monoclonal antibody, 1:100 dilution; Dako, Denmark). Nuclear staining for Ki67 was defined as positive, and the percentage of positively stained cells among the total number of malignant cells was scored.¹⁶ We randomly counted three fields for scoring Ki67 using the Olympus cellSens ver.1.18 software and a BX50 microscope equipped with a DP74 camera (Olympus, Japan). Furthermore, the MIB-1 index was independently reviewed by a pathology technician (TI) and clinicians (YM, TN, KY).

Evaluation of lung metastases using microscopy. The lung tissues were fixed in 10% formalin and embedded in paraffin. The excised lungs were fixed with formalin, embedded in paraffin, sectioned, and stained with haematoxylin and eosin for histological observation. The number of lung metastases was then counted under high-power light microscopy based on histological findings, regardless of tumour size, which was independently reviewed by a pathology technician (TI) and orthopaedic surgeons (YM, TN, TH).

Statistical analysis. Significant differences between the two groups were compared using the Mann-Whitney U test, and more than three groups were compared using the Kruskal-Wallis chi-squared test. The statistical significance level was set at $p < 0.05$. All statistical analyses were performed using the EZR graphical user interface (Saitama Medical Centre, Jichi Medical University, Saitama, Japan) for R package (R Foundation for Statistical Computing, Austria), which is a modified version of the R Commander designed to add statistical functions commonly used in biostatistics.

Ethics statement. All experiments were performed in accordance with the interdisciplinary principles and guidelines for the use of animals in research, testing, and education. The study was approved by the Ethics Committee of the Animal Research Committee, Mie University Faculty of Medicine (approval number 2020-11). We have included an ARRIVE checklist to show that we have conformed to the ARRIVE guidelines.

Results

Efficacy of AO-RDT treatment of LM8, MDA-MB-231, and PC-3 cells. Cell proliferation was evaluated at each concentration of AO and dose of radiation after AO-RDT treatment using the cell proliferation assay. In LM8 cells, at a concentration of 1.0 $\mu\text{g/ml}$ AO, the 5 Gy dose showed a significant decrease in cell proliferation, compared with 0 Gy ($p = 0.001$) and 3 Gy ($p = 0.007$, both Mann-Whitney U test) (Figure 1a). At a radiation dose of 5 Gy, cell proliferation was significantly inhibited in a AO dose-dependent manner (Figure 1a).

In MDA-MB-231 cells, at a concentration of 1.0 $\mu\text{g/ml}$ AO, a significant decrease in cell proliferation was observed at radiation doses of 3 Gy ($p = 0.003$) and 5 Gy ($p = 0.001$, both Mann-Whitney U test) when compared with that in the non-irradiated group at 48 hours (Figure 1b). At a dose of 5 Gy, a remarkable decrease in cell proliferation was observed at AO concentrations of 0.1 and 1.0 $\mu\text{g/ml}$ for up to 24 hours when compared with that in the non-administered group. Furthermore, the treatment groups with AO concentrations of 1.0 $\mu\text{g/ml}$ remained significantly different from the non-administered group after 48 hours ($p = 0.001$, Mann-Whitney U test) (Figure 1b).

In PC-3 cell lines, at an AO concentration of 1.0 $\mu\text{g/ml}$, radiation doses of 3 Gy ($p = 0.002$) and 5 Gy ($p = 0.006$, both Mann-Whitney U test) resulted in a significant decrease in cell proliferation when compared with that in the non-irradiated group at 48 hours (Figure 1c). Cell proliferation was significantly inhibited in a dose-dependent manner at a dose of 5 Gy (Figure 1c).

Thus, we decided to use an AO concentration of 1.0 $\mu\text{g/ml}$ and a radiation dose of 5 Gy in a xenograft mouse model of LM8, MDA-MB-231, and PC-3 cells based on the results of the *in vitro* study.

Mouse xenograft model. During the 14 days, there were no obvious differences in body weight between the groups. The AO-RDT group showed a significant inhibition in tumour volume compared with that in the control and AO groups (Figure 2a). The mean tumour size of the control group at 14 days was 1,148 mm^3 (standard deviation (SD) 1,185; 191 to 3,194), whereas the mean tumour sizes of the AO, radiotherapy, and AO-RDT groups were 813 mm^3 (SD 444; 421 to 1,516, $p = 0.841$), 256 mm^3 (SD 326; 5.2 to 802, $p = 0.056$), and 38 mm^3 (SD 30; 0 to 68, $p = 0.008$, all Mann-Whitney U test), respectively. For MDA-MB-231 cells, the tumour volume in the AO-RDT group was significantly lower than that in the control group. There was no significant difference in tumour

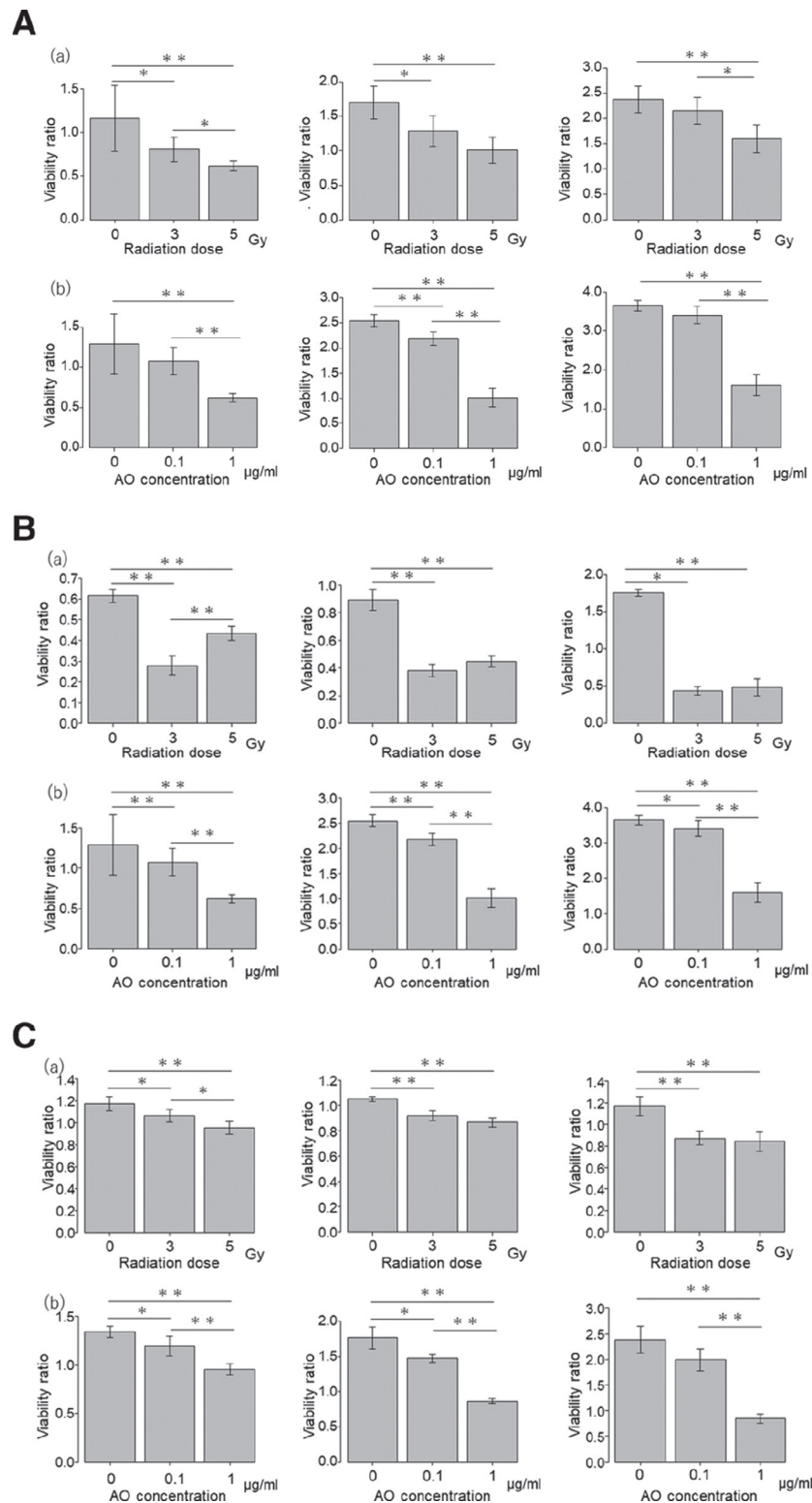


Fig. 1

A) Cell proliferation assay at six hours (left), 24 hours (middle), and 48 hours (right) in LM8 cells. a) Under acridine orange (AO) concentration of 1.0 µg/ml and several radiation doses. b) Under the radiation dose of 5 Gy and several concentrations of AO. Cell viability at each hour was compared with that at 0 hours. B) MTS assay at six hours (left), 24 hours (middle), and 48 hours (right) in MDA-MD-231 cells. a) Under AO concentration of 1.0 µg/ml and several radiation doses. b) Under the radiation dose of 5 Gy and several concentrations of AO. Cell viability at each hour was compared with that at 0 hours. C) MTS assay at six hours (left), 24 hours (middle), and 48 hours (right) in PC3 cells. a) Under AO concentration of 1.0 µg/ml and several radiation doses. b) Under the radiation dose of 5 Gy and several concentrations of AO. Cell viability at each hour was compared with that at 0 hours. * $p < 0.05$, ** $p < 0.01$ (Mann-Whitney U test).

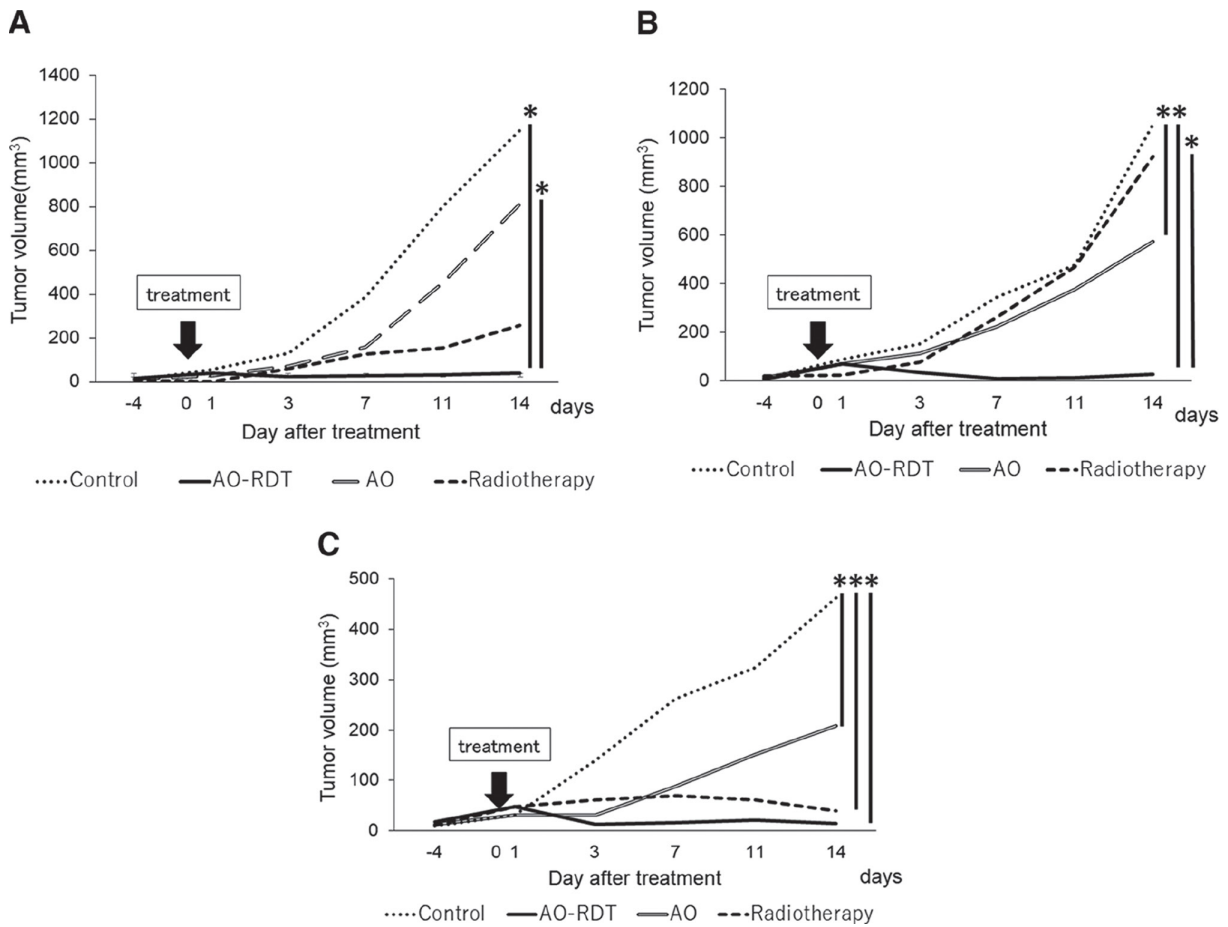


Fig. 2

a) The change in tumour volume during the 14 days after treatment in osteosarcoma model. b) The change in tumour volume during the 14 days after treatment in breast cancer model. c) The change in tumour volume during the 14 days after treatment in prostate cancer model. * $p < 0.05$, ** $p < 0.01$, all Mann-Whitney U test. AO, acridine orange; AO-RDT, radiodynamic therapy using acridine orange.

volume between the radiotherapy and control groups. However, when compared with the radiotherapy group, the AO-RDT group showed a significant reduction in tumour size ($p = 0.008$, Mann-Whitney U test) (Figure 2b). The mean tumour size of the control group at 14 days was $1,055 \text{ mm}^3$ (SD 236; 817 to 1,421), while the AO, radiotherapy, and AO-RDT groups' mean tumour sizes were 573 mm^3 (SD 212; 296 to 780, $p = 0.008$), 923 mm^3 (SD 309; 482 to 1,272, $p = 0.552$), and 24 mm^3 (SD 10; 6 to 33, $p = 0.008$, all Mann-Whitney U test), respectively. In PC-3 cells, there was a significant difference in tumour volume between the treatment group and the control group (Figure 2c). The mean tumour size of the control group at 14 days was 463 mm^3 (SD 176; 240 to 650), while the AO, radiotherapy, and AO-RDT groups' mean tumour sizes were 209 mm^3 (SD 127; 84 to 413, $p = 0.032$), 39 mm^3 (SD 20; 10 to 63, $p = 0.008$), and 15 mm^3 (SD 10; 1 to 29, $p = 0.008$, all Mann-Whitney U test), respectively. Table I shows the median and interquartile range (IQR) during 14 days at each xenograft model.

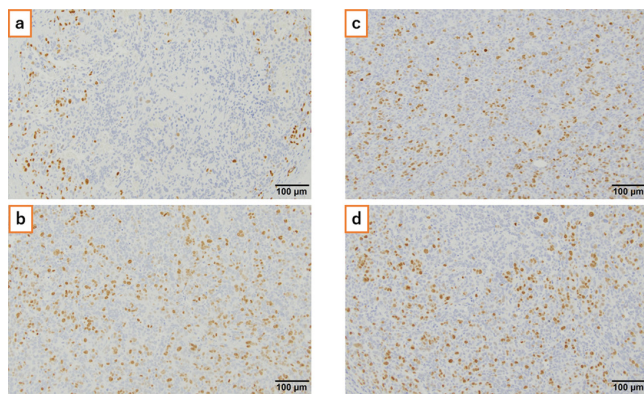
MIB-1 index of MDA-MB-231 cells. The median of each MIB-1 index was 25.9% (IQR 22.6 to 33.4) for AO-RDT, 40.3% (IQR 40.1 to 45.2) for AO, 45.7% (IQR 43.6 to 51.1) for radiotherapy, and 48.3% (IQR 43.6 to 54.9) for control. The MIB-1 index of the AO-RDT group was significantly lower than that of the control ($p = 0.016$), AO ($p = 0.032$), and radiation groups ($p = 0.008$, all Mann-Whitney U test) (Figure 3).

The analysis of lung metastasis. In the LM8 xenograft model, there was a significant correlation between the number of lung metastases and tumour volume ($\rho = 0.54$, $p = 0.005$, Spearman's rank correlation). In the MDA-MB-231 and PC-3 xenograft models, there was no significant correlation between the number of lung metastases and tumour volume. In all models, there was no significant difference in the number of lung metastases between groups ($p = 0.353$ for LM8, $p = 0.078$ for MDA-231, and $p = 0.166$ for PC-3, all Kruskal-Wallis chi-squared test).

Table I. The changes in tumour volume during 14 days after treatment in xenograft model.

Tumour	Group	Median volume, mm ³ (IQR)		
		Day 0	Day 7	Day 14
LM8	Control	58 (38 to 67)	210 (150 to 280)	890 (510 to 960)
	AO	24 (23 to 33)	170 (74 to 170)	780 (450 to 900)
	Rx	5.9 (5.9 to 16)	98 (23 to 140)	120 (50 to 310)
	AO-RDT	33 (23 to 63)	33 (23 to 35)	42 (16 to 63)
MDA-MB-231	Control	67 (54 to 84)	290 (250 to 310)	1,060 (880 to 1,100)
	AO	58 (46 to 90)	250 (110 to 260)	620 (410 to 750)
	Rx	23 (10 to 31)	260 (240 to 300)	1,010 (760 to 1,100)
	AO-RDT	33 (23 to 63)	5.2 (5.2 to 11)	29 (25 to 29)
PC-3	Control	28 (23 to 32)	270 (130 to 390)	530 (320 to 580)
	AO	28 (28 to 32)	94 (74 to 100)	200 (130 to 220)
	Rx	54 (32 to 58)	74 (47 to 75)	45 (28 to 50)
	AO-RDT	58 (28 to 65)	16 (13 to 16)	14 (11 to 20)

AO, acridine orange; AO-RDT, radiodynamic therapy using AO; IQR, interquartile range; Rx, radiotherapy.

**Fig. 3**

Ki67 staining of MDA-MB-231 cells. a) Radiodynamic therapy using acridine orange (AO) group; b) AO group; c) radiation group; d) control group.

Discussion

In this study, we demonstrated the efficacy of AO-RDT treatment in breast cancer, prostate cancer, and osteosarcoma cell lines. Furthermore, radiation treatment with the local administration of AO in mice was found to be effective in the inhibition of tumour growth. Interestingly, AO-RDT treatment was more effective for tumour control than radiotherapy in the breast cancer xenograft model. We used breast and prostate cancer cell lines because they are likely to develop bone metastases. Bone-modifying agents may be considered for patients with metastatic bone tumours.^{17,18} Recently, several studies reported the association of high interleukin-6 (IL-6) level with poor prognosis in patients with cancers including osteosarcoma, breast cancer, and prostate cancer.¹⁹ The effect of IL-6-receptor-targeting antibody has been studied in advanced cancers.^{19,20} Conventional external beam radiotherapy has also been the standard of care for painful bone metastases and metastatic epidural spinal cord compression.²¹ However, it has limitations, such as poor long-term tumour control rates and

difficulties with re-irradiation due to adverse events.²¹⁻²³ Stereotactic body radiotherapy has recently been widely used in patients with bone metastasis because of its clinical advantages, including high pain and local control rates.²³ However, there are risks of vertebral body fractures, oesophageal complications, and neuropathy.²³ According to the findings of this study, AO-RDT with a low dose of AO and radiation may be a new treatment option for bone metastases. In patients with bone and soft-tissue sarcoma, previous studies reported that local tumour control was achieved after marginal or intral-lesional resection and AO-PDT and AO-RDT.⁸⁻¹⁰ Local administration of 1.0 µg/ml AO solution into the surgical field in combination with low-dose radiotherapy (5 Gy) did not lead to any complications.⁸⁻¹⁰ In a pilot study, Kusuzaki et al²⁴ reported the clinical outcome of radiotherapy after intravenous administration of AO (iAOR) in eight patients with metastatic cancer. Over the course of one hour, patients received an intravenous infusion of 100 ml of AO solution diluted in saline at a concentration of 0.5 or 1 mg/kg. Two hours after the infusion ended, the target cancerous lesions were irradiated with 3 or 5 Gy of X-rays using a linear accelerator. None of the patients exhibited adverse effects from AO injection. Three of the five patients who received the full course of iAOR treatment exhibited clinical or image-based responses. However, the safety of the regimen in the present study (local administration of 1.0 µg/ml AO in combination with low-dose radiotherapy) should be confirmed before clinical application.

In this study, we evaluated the expression of Ki67 in breast cancer cells. Previous studies have shown that Ki67 levels in resected tumours after neoadjuvant chemotherapy have prognostic value for local tumour control in patients with breast cancer.^{25,26} Patients with higher positive Ki67 levels had a higher local recurrence rate. In the present study, the MIB-1 index of the AO-RDT group was statistically lower than that of the control group. Furthermore, there was no significant difference in the

expression of Ki67 between the control and radiotherapy groups. These findings imply that excellent local control following AO-RDT could be expected.

Finally, we evaluated lung metastases *in vivo*. Satonaka et al²⁷ showed that AO-PDT using strong strobe light and AO alone inhibited pulmonary metastases of mouse osteosarcoma LM8 cell line. They administered AO through the tail vein. In the present study, AO-RDT treatment did not statistically inhibit pulmonary metastases of mouse osteosarcoma, breast cancer, or prostate cancer cell lines. As a result, although the effect of tumour reduction by AO-RDT may indirectly reduce the number of lung metastases, local administration of AO could not affect the entire body.

As limitations, lack of power calculation and lack of reporting side effects of the present treatment should be addressed and further research is warranted to confirm these.

In conclusion, AO-RDT was effective in preventing the proliferation of osteosarcoma, breast cancer, and prostate cancer cell lines *in vitro*. The reduction in tumour volume by AO-RDT was also confirmed *in vivo*.

Supplementary material



An ARRIVE checklist is included to show that the ARRIVE guidelines were adhered to in this study.

References

- Kusuzaki K, Aomori K, Suginoshita T, et al. Total tumor cell elimination with minimum damage to normal tissues in musculoskeletal sarcomas following photodynamic therapy with acridine orange. *Oncology*. 2000;59(2):174–180.
- Kusuzaki K, Suginoshita T, Minami G, et al. Fluorovisualization effect of acridine orange on mouse osteosarcoma. *Anticancer Res*. 2000;20(5A):3019–3024.
- Satonaka H, Kusuzaki K, Matsubara T, et al. Flash wave light strongly enhanced the cytotoxic effect of photodynamic therapy with acridine orange on a mouse osteosarcoma cell line. *Anticancer Res*. 2007;27(5A):3339–3344.
- Hashiguchi S, Kusuzaki K, Murata H, et al. Acridine orange excited by low-dose radiation has a strong cytotoxic effect on mouse osteosarcoma. *Oncology*. 2002;62(1):85–93.
- Hiruma H, Katakura T, Takenami T, et al. Vesicle disruption, plasma membrane bleb formation, and acute cell death caused by illumination with blue light in acridine orange-loaded malignant melanoma cells. *J Photochem Photobiol B*. 2007;86(1):1–8.
- Matsubara T, Kusuzaki K, Matsumine A, Shintani K, Satonaka H, Uchida A. Acridine orange used for photodynamic therapy accumulates in malignant musculoskeletal tumors depending on pH gradient. *Anticancer Res*. 2006;26(1A):187–193.
- Satonaka H, Kusuzaki K, Matsubara T, et al. *In vivo* anti-tumor activity of photodynamic therapy with intravenous administration of acridine orange, followed by illumination with high-power flash wave light in a mouse osteosarcoma model. *Oncol Lett*. 2010;1(1):69–72.
- Nakamura T, Kusuzaki K, Matsubara T, Matsumine A, Murata H, Uchida A. A new limb salvage surgery in cases of high-grade soft tissue sarcoma using photodynamic surgery, followed by photo- and radiodynamic therapy with acridine orange. *J Surg Oncol*. 2008;97(6):523–528.
- Nakamura T, Kusuzaki K, Matsubara T, et al. Long-term clinical outcome in patients with high-grade soft tissue sarcoma who were treated with surgical adjuvant therapy using acridine orange after intra-lesional or marginal resection. *Photodiagnosis Photodyn Ther*. 2018;23:165–170.
- Matsubara T, Kusuzaki K, Matsumine A, et al. Clinical outcomes of minimally invasive surgery using acridine orange for musculoskeletal sarcomas around the forearm, compared with conventional limb salvage surgery after wide resection. *J Surg Oncol*. 2010;102(3):271–275.
- Agarawal JP, Swangsilpa T, van der Linden Y, Rades D, Jeremic B, Hoskin PJ. The role of external beam radiotherapy in the management of bone metastases. *Clin Oncol (R Coll Radiol)*. 2006;18(10):747–760.
- Coleman RE. Skeletal complications of malignancy. *Cancer*. 1997;80(8 Suppl):1588–1594.
- Nielsen OS, Munro AJ, Tannock IF. Bone metastases: pathophysiology and management policy. *J Clin Oncol*. 1991;9(3):509–524.
- Li L, Wang N, Zhu M, et al. Aberrant super-enhancer-driven oncogene ENC1 promotes the radio-resistance of breast carcinoma. *Cell Death Dis*. 2021;12(8):777.
- Ovejera AA, Houchens DP, Barker AD. Chemotherapy of human tumor xenografts in genetically athymic mice. *Ann Clin Lab Sci*. 1978;8(1):50–56.
- Dowsett M, Nielsen TO, A'Hern R, et al. Assessment of Ki67 in breast cancer: recommendations from the International Ki67 in Breast Cancer working group. *J Natl Cancer Inst*. 2011;103(22):1656–1664.
- Fizazi K, Lipton A, Mariette X, et al. Randomized phase II trial of denosumab in patients with bone metastases from prostate cancer, breast cancer, or other neoplasms after intravenous bisphosphonates. *J Clin Oncol*. 2009;27(10):1564–1571.
- Martin M, Bell R, Bourgeois H, et al. Bone-related complications and quality of life in advanced breast cancer: results from a randomized phase III trial of denosumab versus zoledronic acid. *Clin Cancer Res*. 2012;18(17):4841–4849.
- Hagi T, Nakamura T, Kita K, Iino T, Asanuma K, Sudo A. Anti-tumor effect of tocilizumab for osteosarcoma cell lines. *Bone Joint Res*. 2020;9(11):821–826.
- Dorff TB, Goldman B, Pinski JK, et al. Clinical and correlative results of SWOG S0354: a phase II trial of CNT0328 (siltuximab), a monoclonal antibody against interleukin-6, in chemotherapy-pretreated patients with castration-resistant prostate cancer. *Clin Cancer Res*. 2010;16(11):3028–3034.
- Rich SE, Chow R, Raman S, et al. Update of the systematic review of palliative radiation therapy fractionation for bone metastases. *Radiother Oncol*. 2018;126(3):547–557.
- Kirkpatrick JP, van der Kogel AJ, Schultheiss TE. Radiation dose-volume effects in the spinal cord. *Int J Radiat Oncol Biol Phys*. 2010;76(3 Suppl):S42–9.
- Yamada Y, Katsoulakis E, Laufer I, et al. The impact of histology and delivered dose on local control of spinal metastases treated with stereotactic radiosurgery. *Neurosurg Focus*. 2017;42(1):E6.
- Kusuzaki K, Takai T, Yoshimura H, Inoue K, Takai S, Baldini N. Clinical trial of radiotherapy after intravenous injection of acridine orange for patients with cancer. *Anticancer Res*. 2018;38(1):481–489.
- Wu ZY, Kim H-J, Lee J-W, et al. Oncologic outcomes of nipple-sparing mastectomy and immediate reconstruction after neoadjuvant chemotherapy for breast cancer. *Ann Surg*. 2021;274(6):e1196–e1201.
- Goto W, Kashiwagi S, Takada K, et al. Significance of intrinsic breast cancer subtypes on the long-term prognosis after neoadjuvant chemotherapy. *J Transl Med*. 2018;16(1):307.
- Satonaka H, Kusuzaki K, Akeda K, et al. Acridine orange inhibits pulmonary metastasis of mouse osteosarcoma. *Anticancer Res*. 2011;31(12):4163–4168.

Author information:

- Y. Matsuyama, MD, Orthopaedic Surgeon
- T. Nakamura, MD, PhD, Orthopaedic Surgeon
- K. Yoshida, MD, Orthopaedic Surgeon
- T. Hagi, MD, PhD, Orthopaedic Surgeon
- T. Iino, MT, Medical Technician
- K. Asanuma, MD, PhD, Orthopaedic Surgeon
- A. Sudo, MD, PhD, Head of Department
Department of Orthopaedic Surgery, Mie University Graduate School of Medicine, Tsu, Japan.

Author contributions:

- Y. Matsuyama: Writing – original draft, Methodology, Data curation, Formal Analysis, Investigation, Resources.
- T. Nakamura: Conceptualization, Writing – original draft, Methodology, Investigation, Visualization, Project administration, Formal Analysis.
- K. Yoshida: Methodology, Investigation, Resources.
- T. Hagi: Methodology, Data curation, Investigation.
- T. Iino: Methodology, Data curation, Investigation.
- K. Asanuma: Methodology, Supervision.
- A. Sudo: Funding acquisition, Writing – review & editing.

Funding statement:

- The authors received no financial or material support for the research, authorship, and/or publication of this article.

ICMJE COI statement:

- There was no conflict of interest in this study.

Data sharing:

- The data that support the findings of this study are available from the corresponding author upon reasonable request.

Ethical review statement:

- The study was approved by the Ethics Committee of the Animal Research Committee, Mie University (approval number 2020-11).

Open access funding

- The authors report that the open access funding for their manuscript was self-funded.

© **2022 Author(s) et al.** This is an open-access article distributed under the terms of the Creative Commons Attribution Non-Commercial No Derivatives (CC BY-NC-ND 4.0) licence, which permits the copying and redistribution of the work only, and provided the original author and source are credited. See <https://creativecommons.org/licenses/by-nc-nd/4.0/>