



■ BONE FRACTURE

3D ultrasound reconstruction of sonographic callus

A NOVEL IMAGING MODALITY FOR EARLY EVALUATION OF FRACTURE HEALING

**J. A. Nicholson,
W. M. Oliver,
T. J. MacGillivray,
C. M. Robinson,
A. H. R. W. Simpson**

From University of
Edinburgh, Edinburgh,
UK

Aims

The aim of this study was to establish a reliable method for producing 3D reconstruction of sonographic callus.

Methods

A cohort of ten closed tibial shaft fractures managed with intramedullary nailing underwent ultrasound scanning at two, six, and 12 weeks post-surgery. Ultrasound capture was performed using infrared tracking technology to map each image to a 3D lattice. Using echo intensity, semi-automated mapping was performed to produce an anatomical 3D representation of the fracture site. Two reviewers independently performed 3D reconstructions and kappa coefficient was used to determine agreement. A further validation study was undertaken with ten reviewers to estimate the clinical application of this imaging technique using the intraclass correlation coefficient (ICC).

Results

Nine of the ten patients achieved union at six months. At six weeks, seven patients had bridging callus of \geq one cortex on the 3D reconstruction and when present all achieved union. Compared to six-week radiographs, no bridging callus was present in any patient. Of the three patients lacking sonographic bridging callus, one went onto a nonunion (77.8% sensitive and 100% specific to predict union). At 12 weeks, nine patients had bridging callus at \geq one cortex on 3D reconstruction (100%-sensitive and 100%-specific to predict union). Presence of sonographic bridging callus on 3D reconstruction demonstrated excellent reviewer agreement on ICC at 0.87 (95% confidence interval 0.74 to 0.96).

Conclusion

3D fracture reconstruction can be created using multiple ultrasound images in order to evaluate the presence of bridging callus. This imaging modality has the potential to enhance the usability and accuracy of identification of early fracture healing.

Cite this article: *Bone Joint Res* 2021;10(12):759–766.

Keywords: Ultrasound, Tibia, Nonunion

Article focus

■ The aim of this study was to establish a reliable method for producing 3D reconstruction of sonographic callus.

■ Presence of sonographic bridging callus on 3D reconstruction demonstrated excellent reviewer agreement.

Key messages

■ Bridging 3D callus at six weeks post intramedullary nailing is 77.8% sensitive and 100% specific to predict union when present.

Strengths and limitations

■ We present an objective and repeatable method of 3D callus mapping.
■ This was a small proof-of-concept cohort of only ten patients.

Correspondence should be sent to
Jamie A. Nicholson; email:
jamie.nicholson@ed.ac.uk

doi: 10.1302/2046-3758.1012.
BJR-2021-0250

Bone Joint Res 2021;10(12):759–
766.

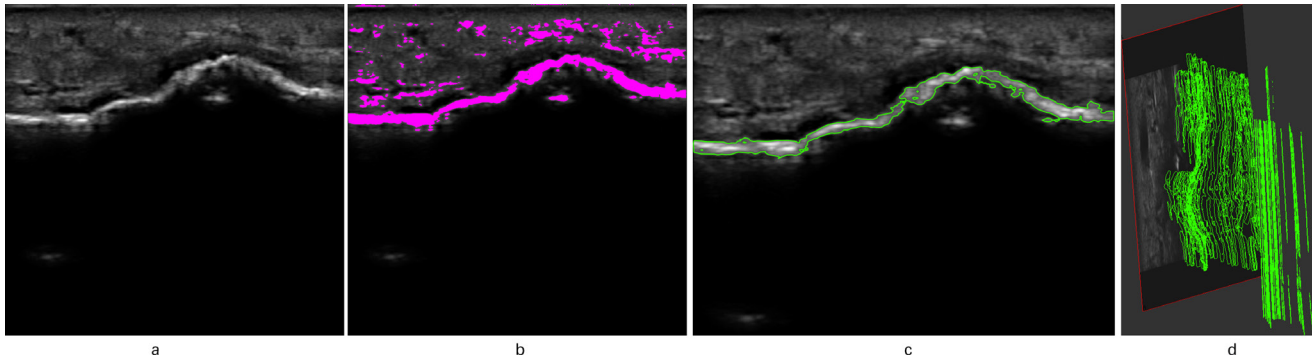


Fig. 1

a) Example of semi-automatic ultrasound 3D mapping with callus. a) Long axis scout of tibia. b) Mapping of sonographic callus using the grayscale threshold of 80. c) Plotted sonographic callus. d) Matrix plot of sequential 2D images of sonographic callus and cortical tibia surface.

Introduction

Following a long bone fracture, bridging callus usually requires three months to be detected on radiographs.¹⁻³ The development of a cortical bridge of callus appears to be crucial to reduce strain and, once achieved, is strongly predictive of ultimate fracture union.⁴⁻⁶ The use of ultrasound to detect early callus formation from six weeks post-intramedullary nailing has been shown to correlate with fracture healing.⁷⁻⁹ More recently, sonographic bridging callus on ultrasound has been described and shown to be strongly predictive of fracture healing for the clavicle.^{10,11}

Current evaluation of callus on ultrasound is entirely operator-dependent. Multiple viewing ‘windows’ are required for long bone fractures in order to appreciate the circumferential presence of callus on each respective cortical surface. This can lead to potential errors in judgement and makes the repeat assessment of a fracture at different timepoints difficult. The ability to visualize multiple ultrasound images of a cortical surface in a single 3D image has great potential to improve the accuracy and usability of this imaging technique. To date, there is no published standardized method to reproduce a 3D ultrasound scan of bridging callus at a fracture site.

The primary aim of this study was to establish a scanning technique to allow 3D imaging of callus formation of a long bone fracture at multiple timepoints.

The secondary aim was to evaluate the reliability of reconstruction and judgement of bridging callus between independent observers.

Methods

The freehand ultrasound software Stradwin version 6.0 (Department of Engineering, University of Cambridge, UK) was used for image acquisition and analysis. This allows simultaneous image and position acquisition. B-mode images are acquired at full speed and mapped to the 3D lattice as the transducer probe is moved through a determined pattern of movement. The ultrasound frequency (3 MHz to 7 MHz), depth penetration (60 mm), and resolution (1 mm) were used.

An AdapTRAX tracking tool (Traxtal, Philips, Canada) was mounted on the transducer, which allows triangulation with six degrees of freedom from the tracking unit. This directly corresponds to the position of the ultrasound transducer, which is indirectly mapped with accuracy to 0.35 mm (Polaris, Northern Digital, Canada).

Ensuring the patient's limb was positioned within the field of capture, scanning via the anteromedial and anterolateral window was performed for the tibia with slow movements over the fracture site with a coupling gel. At the fracture site, multiple captures with different orientations of the probe were performed to limit anisotropy.

The posterior aspect of the tibia was challenging to visualize in the early pilot work of this study, given the depth of the gastrocnemius complex. Therefore, focus was placed on the anterior surface of the tibia for the purpose of this study.

Image interpretation with semi-automated plotting. Semi-automated ultrasound plotting was possible via the use of the echo intensity (EI). Using the long axis ultrasound scout of the tibia, the cortical bone and callus surface can be identified due to the high homogeneity grayscale signal and linear border using an EI with a mean of 87.9 (95% confidence interval (CI) 83.5 to 92.3) as established in previous work.¹⁰ EI is known to fluctuate from the depth of penetration of the ultrasound signal across the soft-tissue envelope, therefore a threshold above 80 was used to identify the desired surface with the Stradwin threshold tool, which was then plotted on sequential images by the reviewer (JAN) (Figure 1).

The evolving bridging callus can then be plotted between the ends of the cortical surface using semi-automated plotting. Using this technique, subsequent 2D image slices can be sequentially mapped from different ‘windows’ around the surface of the tibia to build a single 3D image.

Patient cohort and follow-up routine. The mean age was 49.8 years at time of injury (27 to 73), and seven of the ten patients were male. Half of the injuries were a low-energy mechanism with a fall from standing height (Table I).

Table 1. Patient demographic data of pilot study.

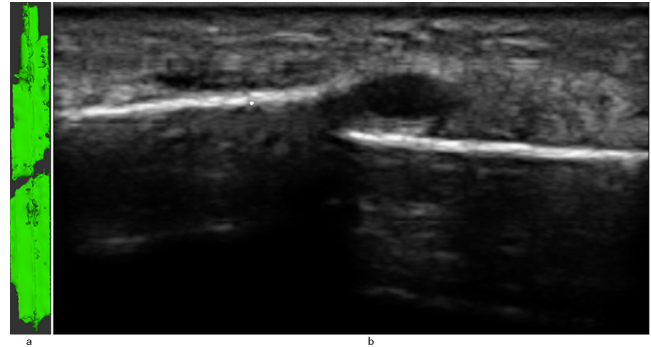Pt No.	Age, yrs	Sex	Mechanism	Smoker	Side	Comminution
1	34	F	Sport	No	L	No
2	27	M	Fall > 2 m	No	R	No
3	61	M	Fall > 2 m	No	R	Yes
4	51	M	Sport	No	R	Yes
5	55	M	Fall < 2 m	Yes	L	Yes
6	62	M	Crush	No	L	Yes
7	62	F	Fall < 2 m	No	L	Yes
8	73	F	Fall < 2 m	No	L	No
9	37	M	Fall < 2 m	No	R	No
10	36	M	Fall < 2 m	No	R	No

Eligible patients were those with a closed diaphyseal tibia fracture with or without fibula fracture. Patients were required to give informed consent and be local to the treatment centre for follow-up. Exclusion criteria were open injuries or substantial soft-tissue crush element with compromised skin, compartment syndrome, under 16 years of age at time of injury, or within the metaphyseal width (Mueller box) of the joint surface. Segmental fractures were excluded but fractures with simple comminution or a butterfly fragment were not.

The modified Radiographic Union Score for Tibia fractures (RUST) was used to grade radiological callus formation at six and 12 weeks.¹² Union was determined by absence of pain on weightbearing and bridging callus on three of the four cortices (RUST score of 11 or more). If the diagnosis of union was in doubt, patients underwent a CT scan of the fracture at six months.

All patients were reviewed and scanned by one of the two surgeons (JAN and WMO). Patients were seen at two weeks after the injury and recruited. At six and 12 weeks patients underwent radiographs and an ultrasound scan. At six months they were seen for a final clinical review and radiograph to ensure union. A pilot cohort of ten patients was the desired sample size in order to establish the practicality and feasibility of the technique. Overall, 18 patients were recruited and ten of these completed six months' follow-up. Eight patients were lost to follow-up and did not re-present for further treatment over the course of this study.

Callus observer agreement on 3D scan. To determine the repeatability and usability of the method, agreement of the presence or absence of 3D bridging callus was determined by two observers (JAN and WMO). Both were orthopaedic surgeons with training in performing and interpreting ultrasound for the purpose of fracture evaluation. The reviewers were blinded to the outcome of the cases (i.e. union or nonunion) and radiographs. The ten six-week scans from the cohort were used for this purpose. The lead author (JAN) performed intraobserver repeats with a minimum of 24 hours between each reconstruction. Weighted kappa was used to determine the strength of association between two observers with 0.4

**Fig. 2**

Two-week ultrasound of anteromedial cortex of fracture site without callus (Patient 7). a) 3D reconstruction. b) Long axis scout image.

to 0.6 fair, 0.6 to 0.8 strong, and 0.8 to 1.0 close to perfect agreement.¹³

A further evaluation of the clinical application of the technique was undertaken using ten reviewers, which included five orthopaedic consultants and five senior trainees to determine the intraclass correlation coefficient (ICC). A random selection of ten 3D reconstructions was presented to each reviewer without any indication of scan timing, radiograph, or clinical information. A two-way mixed model, with assessment of consistency between observers was used to calculate a 'single measure'.

Statistical analysis was performed using SPSS version 24 (IBM, USA). Data were tested for normal distribution with the D'Agostino-Pearson test. Linear variables (EI data) were assessed using the independent-samples *t*-test for parametric data or the Mann-Whitney U test for nonparametric data. Analysis of variance (ANOVA) was used to compare the mean EI of over two mean variables. Differences between dichotomous data were assessed using the chi-squared test. A *p*-value of < 0.05 was defined as statistically significant.

Ethics. Ethical approval for the use of ultrasound to observe fracture healing was prospectively obtained from the South East Scotland Research Ethics Committee (reference number 06/S1103/51).

Results

RUST findings. At six weeks the median RUST score was 4 (interquartile range (IQR) 4.0 to 6.25), increasing to 9.5 (IQR 7.75 to 10.25) at 12 weeks. Nine of the ten patients were clinically and radiologically united at six months with a minimum RUST score of 11.

One patient was classified with a nonunion at six months post-injury (Patient 5), and they were the only smoker in the cohort. One cortex was judged to have bridging callus on radiograph at 24 weeks with a RUST score of 8. They underwent a CT scan for a suspected nonunion at approximately nine months postoperatively. Bridging callus was found on two of the four cortices, and the patient was treated as a delayed union and did

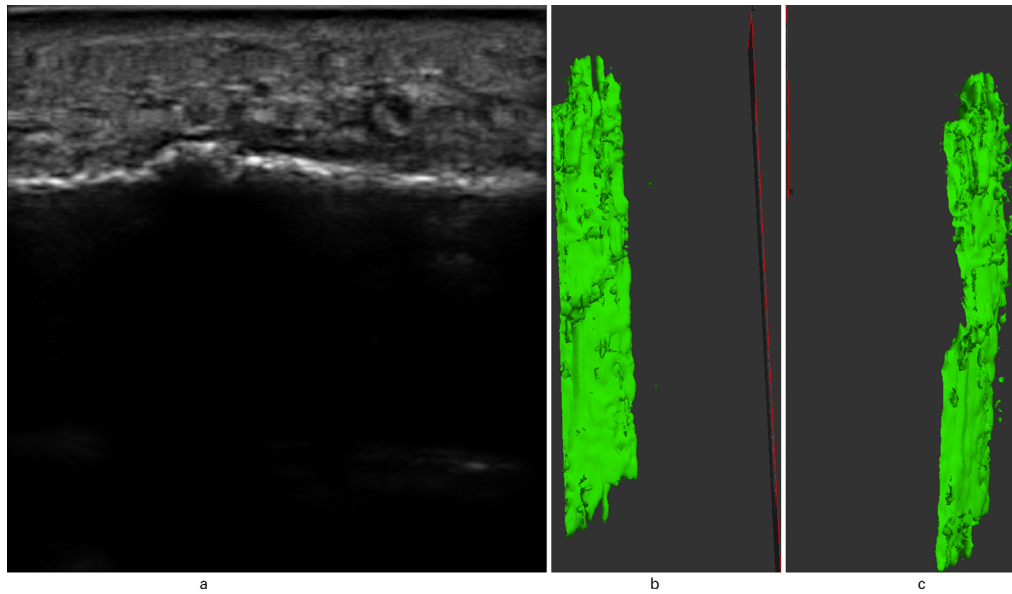


Fig. 3

Six-week ultrasound of anteromedial cortex with bridging callus (Patient 7). a) Long axis scout image. b) 3D reconstruction with bridging callus. c) Second view of 3D reconstruction.

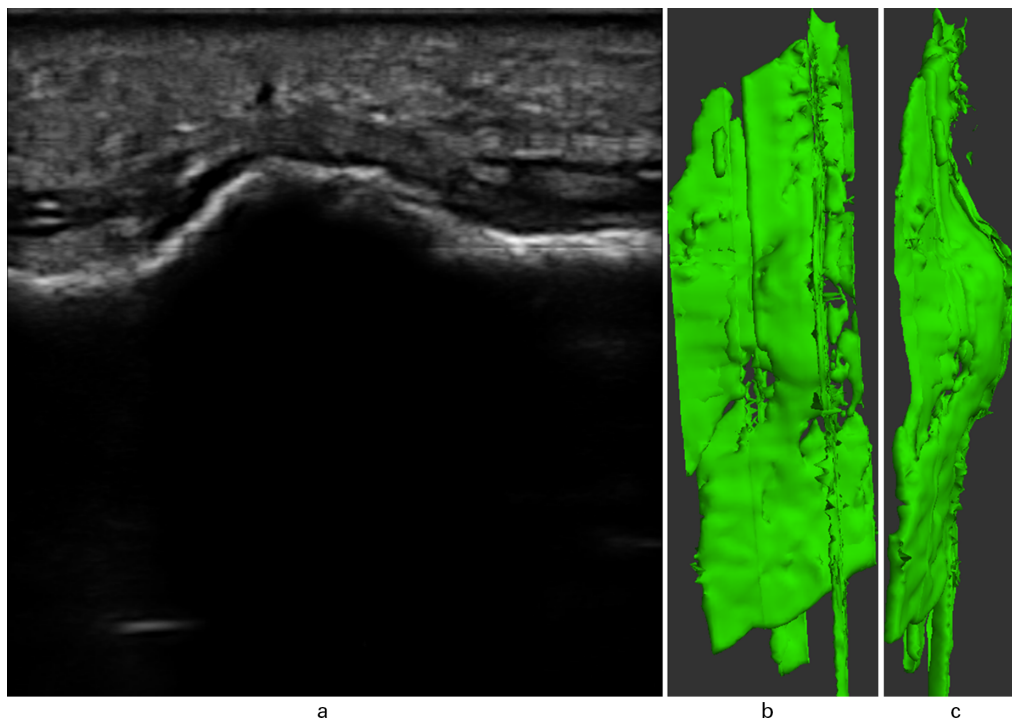


Fig. 4

A 12-week ultrasound of anteromedial cortex with remodelling bridging callus (Patient 7). a) Long axis scout image. b) 3D reconstruction with remodelling callus. c) Second view of 3D reconstruction.

not undergo any further intervention as their symptoms were minimal at that point.

Ultrasound findings and fracture healing prediction. At two weeks post-intramedullary nailing, the fracture site

was clearly visible in all patients but there was no detection of bridging callus (Figure 2). At six weeks, 70% of patients ($n = 7/10$) had bridging callus of at least one cortex (Figures 3 and 4). When detected, all united by

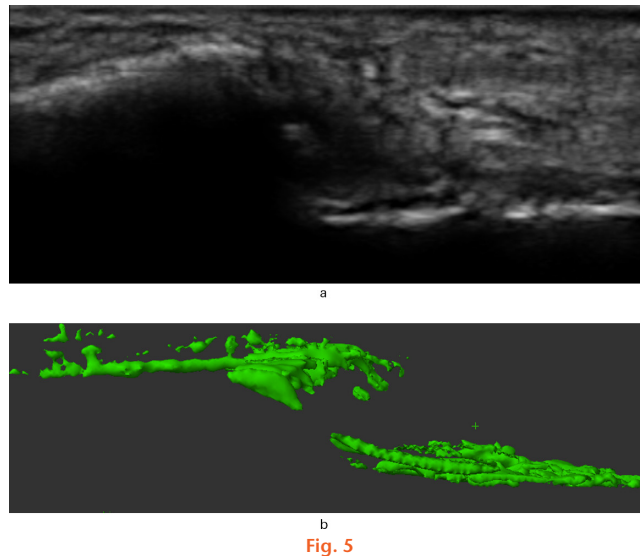


Fig. 5

A 12-week ultrasound of anteromedial cortex without sonographic callus (Patient 5). a) Long axis scout image. b) 3D reconstruction with absent bridging callus.

Table II. Radiograph and ultrasound findings in the cohort.

Pt No.	6 weeks			12 weeks			24 weeks	
	Radiograph		Ultrasound	Radiograph		Ultrasound	Radiograph	
	RUST	Bridging callus		RUST	Bridging callus		RUST	Bridging callus
1	5	No	Yes	8	Yes	Yes	11	Yes
2	4	No	Yes	10	Yes	Yes	12	Yes
3	4	No	Yes	7	No	Yes	11	Yes
4	4	No	Yes	10	Yes	Yes	11	Yes
5	4	No	No	5	No	No	8	Yes
6	6	No	Yes	8	No	Yes	12	Yes
7	4	No	Yes	9	Yes	Yes	11	Yes
8	8	No	Yes	11	Yes	Yes	12	Yes
9	4	No	No	11	Yes	Yes	12	Yes
10	7	No	No	10	Yes	Yes	12	Yes

RUST, Radiographic Union Score for Tibia fractures.

six months (77.8% sensitive and 100% specific to predict union). Of the three patients who lacked bridging callus, one went on to a nonunion (Figure 5).

The RUST score did not show any correlation with the detection of bridging callus on ultrasound at six weeks (median 4.0 vs 4.0; Mann-Whitney U test, $p = 1.000$). Fracture comminution also did not influence the detection of bridging callus on ultrasound (Mann-Whitney U test, $p = 1.000$). Compared to radiographs, no bridging callus was found at six weeks in any patient.

At 12 weeks, 90% of patients ($n = 9/10$) had bridging callus of at least one cortex. When detected, all united (100% sensitive and 100% specific to predict union). In comparison to radiographs at 12 weeks, seven of these nine patients had at least one cortical bridge evident (Table II).

Reviewer agreement. The 3D reconstructions of the ultrasound scans enabled an anatomical reconstruction of the cortical surface and bridging callus, which showed excellent correlation on visual inspection for the majority of patients

between the two reviewers. The kappa intraobserver agreement showed near perfect agreement for the detection of any bridging callus at 1.0 (weighted kappa, $p = 0.020$) (95% CI 1.0 to 1.0). The kappa interobserver agreement between the two independent observers for sonographic bridging callus was 0.78 (weighted kappa, $p = 0.011$) (95% CI 0.39 to 1.18) (Table III and Table IV).

For one patient there was disagreement between the presence of bridging callus. On the medial cortex there was disagreement regarding the presence of bridging callus, the lead author (JAN) plotted this as bridging on the reconstruction and the second reviewer (WMO) did not. On the lateral image the nail is clearly visible across the fracture site, and both reviewers plotted this as absent bridging callus on the reconstruction. At three months, the bridging callus across the fracture was now more apparent on the medial cortex which both reviewers plotted.

The agreement of bridging callus between the ten reviewers was excellent, with an ICC of 0.87 (95% CI 0.74

Table III. Reviewer agreement of 3D scans for presence of any bridging callus and fracture outcome.

Pt No.	Fracture outcome	Author	Second observer	Agreement
1	Union	1	1	Yes
2	Union	1	1	Yes
3	Union	1	0	No
4	Union	1	1	Yes
5	Nonunion	0	0	Yes
6	Union	1	1	Yes
7	Union	1	1	Yes
8	Union	1	1	Yes
9	Union	0	0	Yes
10	Union	0	0	Yes

to 0.96). There was perfect agreement on eight of the ten scans that were presented.

Discussion

In this cohort of ten tibia shaft fractures, prospective ultrasound evaluation of the fracture site with 3D reconstruction was a useful aid to predict union in the majority of fractures. In those patients who united their fractures at six months, bridging callus was visualized on 3D ultrasound reconstruction at six weeks in 70% of patients, increasing to 100% by three months. Two independent reviewers (JAN and WMO) produced 3D reconstructions with a high level of agreement upon which to base clinical judgements. Further validation with ten orthopaedic surgeons found excellent agreement on the judgement of bridging callus. The accurate mapping of 3D callus without ionizing radiation holds great potential to monitor and predict impaired fracture healing.

Nonunion causes considerable morbidity and expense.^{14,15} In modern orthopaedic practice, intramedullary nailing is the most popular initial management of unstable tibial diaphyseal fractures. Nonunion is found in approximately 9% of cases with modern reamed techniques for closed tibia diaphyseal fractures.^{14,16,17} As expected, open fractures have a higher incidence of nonunion and the risk correlates to the severity of the injury.¹⁶ When aseptic nonunion occurs, exchange nailing is a straightforward method of treatment with a high success rate.^{18,19} The indications and timing for exchange nailing must take into account the severity of the original injury. Most closed tibial diaphyseal fractures will heal between 12 and 16 weeks following injury. Absence of radiological evidence of progression to union by 16 weeks is therefore a relative indication for exchange nailing.¹⁹

Callus on radiograph usually takes six to eight weeks to be evident and often requires at least three months before bridging is apparent in long bone fractures.¹⁻³ The importance of a cortical bridge does appear to be the crucial event and once this occurs, union is generally observed.⁴⁻⁶ The 2D projection of radiographs can cause errors in judgement and the development of the RUST score has been advocated to improve user agreement.³ Although CT may improve the accuracy of judging the

Table IV. Overall accuracy of reviewer agreement for presence of any bridging callus and fracture outcome.

Variable	Author	Second observer	Overall agreement
Sensitivity, % (n)	77.8 (7/9)	66.7 (6/9)	72.3
Specificity, % (n)	100 (7/7)	100 (6/6)	100
PPV, % (n)	100 (7/7)	100 (6/6)	100
NPV, % (n)	33.3 (1/3)	25 (1/4)	29.2

NPV, negative predictive value; PPV, positive predictive value.

cortical bridge,²⁰⁻²³ it requires ionizing radiation and the timing at which callus can be found is likely similar to that of radiographs.²

The use of ultrasound to detect early bridging callus prior to radiographs has been demonstrated by two independent research groups. Moed et al⁷ demonstrated a scanning technique in a pilot study of tibial nails using three scanning portals to achieve a 270° view of the tibia. A second prospective study of 50 tibial diaphyseal fractures treated with unreamed statically locked intramedullary nails found that 38 fractures had ultrasound evidence of healing between six and nine weeks, with a 97% positive predictive value and 100% sensitivity for fracture union.⁸ They observed fracture healing on ultrasound at a mean of 6.5 weeks versus 19 weeks on radiographs ($p < 0.001$). Management of tibial diaphyseal fractures has evolved since this study with modern nailing techniques using larger reamed nails and early weightbearing.²⁴ A second research group using modern reamed nails found that ultrasound consistently detected callus prior to radiographs at approximately two weeks earlier.⁹

Despite this promising research, ultrasound has not found a routine use in clinical practice, possibly due to its unfamiliarity for surgeons. We have recently published on a repeatable ultrasound technique,¹⁰ and validated this on a cohort of displaced midshaft clavicle fractures where six week sonographic bridging callus predicted fracture healing in 98.6% of cases.¹¹ The ability to visualize the fracture site as a 3D reconstruction would enable clinicians unfamiliar with ultrasound to make their own judgement on the progression of callus. A series of ultrasound scans can be used to form a 3D reconstruction, allowing for a more anatomical representation of the fracture site and maximizing the ability to view callus from different orientations. The agreement was excellent between observers with potential superiority to a 2D method, upon which our unit has previously published.¹⁰ Reviewers were presented with anterior and lateral cortex of the tibia on which to judge the presence of bridging callus. Although the ICC showed excellent agreement, there were two cases of discrepancies on the presence of bridging callus. In both cases there were minor projections of callus from the fracture ends, but no substantial bridge between cortical fragments.

There were other potential challenges discovered with the 3D reconstruction process. The reconstruction is based on the quality of image acquisition during routine 2D (or B-mode) scanning. If the operator does not capture adequate images, the reconstruction will be flawed. The use of thresholds to plot cortical bone and callus reduced the subjectivity of reviewer interpretation, but this is far from fully automated reconstruction. The EI of superficial tissue above the cortical surface can cause considerable signal changes, and the reviewer still needs to plot each area of interest on sequential imaging. A more refined technique would be the use of an algorithm to produce an automated 3D reconstruction, which would reduce the subjectivity and labour intensity of the process.

Critically for the tibia, any nonunion intervention within the first three months following surgery would likely be considered inappropriate, given that the decision to undertake an exchange nailing might be premature at this stage. However, ultrasound evaluation beyond three months may display evidence of bridging callus prior to radiographs and with potentially superior accuracy. For other fractures such as the clavicle and humerus shaft, which are often managed nonoperatively, 3D reconstructions to monitor callus progression over the first three months following injury have great potential to refine the prediction of fracture healing to guide treatment.

This was a prospective study carried out with a defined cohort of patients. Scans were carried out by two orthopaedic surgeons with training in the technique and reconstructions performed independently of each other. Whether this technique would be valid in open fractures or those with substantial soft-tissue injury is unclear, but theoretically would be applicable. The size of our pilot cohort limits the generalizability of our findings. The effect of smoking on the detection of callus in the tibia is unknown from our work. Furthermore, this study was underpowered to determine the prognostic value of ultrasound to predict nonunion of the tibia. However, the technique which has been outlined and validated in this study would be a reproducible research tool for other groups to employ.

In conclusion, 3D reconstruction of callus progression at a fracture site may enhance the usability and reproducibility of ultrasound for the monitoring of fracture healing. This is the first study to our knowledge to outline a reliable and repeatable technique for 3D fracture site evaluation for bridging callus detection.

Twitter

Follow J. A. Nicholson @OrthoNicholson

References

1. Eyres KS, Bell MJ, Kanis JA. Methods of assessing new bone formation during limb lengthening. Ultrasonography, dual energy X-ray absorptiometry and radiography compared. *J Bone Joint Surg Br.* 1993;75-B(3):358–364.
2. Simpson A. The forgotten phase of fracture healing: The need to predict nonunion. *Bone Joint Res.* 2017;6(10):610–611.
3. Leow JM, Clement ND, Tawonsawatruk T, Simpson CJ, Simpson A. The radiographic union scale in tibial (RUST) fractures: Reliability of the outcome measure at an independent centre. *Bone Joint Res.* 2016;5(4):116–121.

4. Lack WD, Starman JS, Seymour R, et al. Any cortical bridging predicts healing of tibial shaft fractures. *J Bone Joint Surg Am.* 2014;96-A(13):1066–1072.
5. Strotman PK, Karunakar MA, Seymour R, Lack WD. Any Cortical Bridging Predicts Healing of Supracondylar Femur Fractures after Treatment with Locked Plating. *J Orthop Trauma.* 2017;31(10):538–544.
6. DiSilvio F, Foyil S, Schiffman B, Bernstein M, Summers H, Lack WD. Long Bone Union Accurately Predicted by Cortical Bridging within 4 Months. *JB JS Open Access.* 2018;3(4):e0012.
7. Moed BR, Watson JT, Goldschmidt P, Van Holsbeeck M. Ultrasound for the early diagnosis of fracture healing after interlocking nailing of the tibia without reaming. *Clin Orthop Relat Res.* 1995;310:137–144.
8. Moed BR, Subramanian S, Van Holsbeeck M, Watson JT, Cramer KE, Karges DE. Ultrasound for the Early Diagnosis of Tibial Fracture Healing after Static Interlocked Nailing Without Reaming: Clinical Results. *J Orthop Trauma.* 1998;12(3):206–213.
9. Chachan S, Tudu B, Sahu B. Ultrasound monitoring of fracture healing: Is this the end of radiography in fracture follow-ups? *J Orthop Trauma.* 2015;29(3):e133–8.
10. Nicholson JA, Oliver WM, Lizhang J, MacGillivray T, Perks F, Robinson CM. Sonographic bridging callus: An early predictor of fracture union. *Injury.* 2019;50(12):2196–2202.
11. Nicholson JA, Oliver WM, MacGillivray TJ, Robinson CM, Simpson AHRW. Sonographic bridging callus at six weeks following displaced midshaft clavicle fracture can accurately predict healing. *Bone Joint Res.* 2021;10(2):113–121.
12. Litrenta J, Tornetta P, Mehta S, Jones C, O'Toole R, Bhandari M. Determination of radiographic healing: an assessment of consistency using rust and modified rust in metadiaphyseal fractures. *J Orthop Trauma.* 2015;29(11):516–520.
13. Fleiss JL, Levin B, Paik MC. *Statistical Methods for Rates and Proportions.* Third ed. Hoboken, New Jersey: John Wiley & Sons, Inc. 2003.
14. Mills LA, Aitken SA, Simpson A. The risk of non-union per fracture: current myths and revised figures from a population of over 4 million adults. *Acta Orthop.* 2017;88(4):434–439.
15. Lerner RK, Esterhai JL Jr, Polomano RC, Cheatle MD, Heppenstall RB. Quality of life assessment of patients with posttraumatic fracture nonunion, chronic refractory osteomyelitis, and lower-extremity amputation. *Clin Orthop Relat Res.* 1993;295:28–36.
16. Court-Brown CM, McQueen MM, Quaba AA, Christie J. Locked intramedullary nailing of open tibial fractures. *J Bone Joint Surg Br.* 1991;73-B(6):959–964.
17. Rupp M, Biehl C, Budak M, Thormann U, Heiss C, Alt V. Diaphyseal long bone nonunions - types, aetiology, economics, and treatment recommendations. *Int Orthop.* 2018;42(2):247–258.
18. Court-Brown CM, Keating JF, Christie J, McQueen MM. Exchange intramedullary nailing. Its use in aseptic tibial nonunion. *J Bone Joint Surg Br.* 1995;77-B(3):407–411.
19. Tsang ST, Mills LA, Frantzas J, Baren JP, Keating JF, Simpson AH. Exchange nailing for nonunion of diaphyseal fractures of the tibia: our results and an analysis of the risk factors for failure. *Bone Joint J.* 2016;98-B(4):534–541.
20. Kuhlman JE, Fishman EK, Magid D, Scott WW, Brooker AF, Siegelman SS. Fracture nonunion: CT assessment with multiplanar reconstruction. *Radiology.* 1988;167(2):483–488.
21. Schnarkowski P, Rédei J, Peterfy CG, Weidenmaier W, Mutschler W, Arand M. Tibial shaft fractures: Assessment of fracture healing with computed tomography. *J Comput Assist Tomogr.* 1995;19(5):777–781.
22. Costelloe CM, Dickson K, Cody DD, Hernandez M, Demouy EH. Computed tomography reformation in evaluation of fracture healing with metallic fixation: Correlation with clinical outcome. *J Trauma - Inj Infect Crit Care.* 2008;65(6):1421–1424.
23. Grigoryan M, Lynch JA, Fierlinger AL, Guermazi A, Fan B, MacLean DB. Quantitative and qualitative assessment of closed fracture healing using computed tomography and conventional radiography. *Acad Radiol.* 2003;10(11):1267–1273.
24. Keating JF, O'Brien PJ, Blachut PA, Meek RN, Broekhuysen HM. Locking intramedullary nailing with and without reaming for open fractures of the tibial shaft. A prospective randomized study. *J Bone Joint Surg Am.* 1997;79-A(3):334–341.

Author information:

- J. A. Nicholson, MBChB (Hons), BScMedSci (Hons), MRCS (Ed), FHEA, MFSTEd, Specialist Trainee Trauma & Orthopaedics
- W. M. Oliver, LLB (Hons), MBBS (Hons), MRCS(Ed), Specialist Trainee Trauma & Orthopaedics
- C. M. Robinson, FRCS (Ed), Consultant Orthopaedic Surgeon
- A. H. R. W. Simpson, FRCS (Ed), PhD, Professor of Orthopaedic Surgery Department of Orthopaedic Surgery, University of Edinburgh, Edinburgh, UK.

- T. J. MacGillivray, PhD, Senior Research Fellow, Clinical Research Imaging Centre, University of Edinburgh, Edinburgh, UK.

Author contributions:

- J. A. Nicholson: Conceptualization, Methodology, Formal Analysis, Project administration, Writing - original draft.
- W. M. Oliver: Data curation, Methodology, Writing - review & editing.
- T. J. MacGillivray: Conceptualization, Supervision, Writing – review & editing.
- C. M. Robinson: Conceptualization, Supervision, Writing – review & editing.
- A. H. R. W. Simpson: Conceptualization, Supervision, Writing – review & editing.

Funding statement:

- No benefits in any form have been received or will be received from a commercial party related directly or indirectly to the subject of this article.

ICMJE COI statement:

- A. H. R. W. Simpson is Editor-in-Chief of *Bone & Joint Research*.

Acknowledgements:

- The authors thank the SORT-IT (Scottish Orthopaedic Research Trust into Trauma) Edinburgh research team members Keri Swain and Debbie Ketchen for their assistance with administration of the study recruitment. Furthermore, the authors thank Dr Fergus Perks, Musculoskeletal Consultant Radiologist, for his assistance in establishing the ultrasound scanning technique. We also thank the surgeons in the department who contributed to the reviewer scan evaluation.

Ethical review statement:

- Ethical approval was prospectively obtained for this study from South East Scotland Research Ethics Committee, with the unique ID 06/S1103/51.

© 2021 Author(s) et al. This is an open-access article distributed under the terms of the Creative Commons Attribution Non-Commercial No Derivatives (CC BY-NC-ND 4.0) licence, which permits the copying and redistribution of the work only, and provided the original author and source are credited. See <https://creativecommons.org/licenses/by-nc-nd/4.0/>