

## ■ FOOT AND ANKLE

# Comparison of the outcome of total ankle arthroplasty for osteoarthritis with moderate and severe varus malalignment and that with neutral alignment

S-D. Joo,  
K-B. Lee

From Chonnam  
National University  
Hospital, Gwangju,  
Republic of Korea

### Aims

The purpose of this study was to compare the clinical and radiographic outcomes of total ankle arthroplasty (TAA) in patients with pre-operatively moderate and severe arthritic varus ankles to those achieved for patients with neutral ankles.

### Patients and Methods

A total of 105 patients (105 ankles), matched for age, gender, body mass index, and follow-up duration, were divided into three groups by pre-operative coronal plane tibiotalar angle; neutral ( $< 5^\circ$ ), moderate ( $5^\circ$  to  $15^\circ$ ) and severe ( $> 15^\circ$ ) varus deformity. American Orthopaedic Foot and Ankle Society (AOFAS) ankle-hindfoot score, a visual analogue scale (VAS), and Short Form (SF)-36 score were used to compare the clinical outcomes after a mean follow-up period of 51 months (24 to 147).

### Results

The post-operative AOFAS, VAS scores, range of movement and complication rates did not significantly differ among three groups. However, there was less improvement in the SF-36 score of the severe varus group ( $p = 0.008$ ). The mean post-operative tibiotalar alignment was  $2.6^\circ$  ( $0.1^\circ$  to  $8.9^\circ$ ),  $3.1^\circ$  ( $0.1^\circ$  to  $6.5^\circ$ ) and  $4.6^\circ$  ( $1.0^\circ$  to  $10.6^\circ$ ) in the neutral, moderate and severe groups respectively. Although the severe varus group showed less corrected alignment than the neutral group, the mean tibiotalar angles of the three groups were within neutral alignment.

### Conclusion

TAA for moderate and severe varus arthritic deformity showed similar satisfactory clinical and radiographic outcomes as those obtained by patients in the neutral group when post-operative neutral alignment was achieved.

Cite this article: *Bone Joint J* 2017;99-B:1335–42.

Satisfactory outcomes after total ankle arthroplasty (TAA) for osteoarthritis (OA) have been reported.<sup>1–5</sup> Although lower survival rates, and higher complication and re-operation rates after TAA have also been reported compared with hip and knee arthroplasty.<sup>6,7</sup> Poor outcome after TAA has been associated with a history of neuroarthropathy, poor soft tissues, severe angular deformities, osteoporosis, osteonecrosis, long-term therapy with immunosuppressive drugs, and significant joint laxity.<sup>8</sup>

Pre-operative coronal plane deformity of the ankle joint should be corrected as residual post-operative deformity may result in instability, progressive shearing force, edge loading or subluxation of the bearing, resulting in poor long-term results.<sup>9,10</sup> It has been suggested that pre-operative varus or valgus malalignment of  $> 15^\circ$  is a relative contraindication to TAA and  $> 20^\circ$  an absolute contraindication.<sup>5,11</sup> Varus

deformity, if between  $10^\circ$  and  $15^\circ$ , may result in early failure.<sup>4,10</sup> However, other reports have shown that a varus deformity of  $> 10^\circ$  can result in a satisfactory outcome when combined with adequate ancillary procedures such as a deltoid ligament release or lateral ligament reconstruction.<sup>6,12</sup>

A review of 43 TAAs with moderate to severe coronal plane deformity ( $10^\circ$  to  $25^\circ$ ), revealed correction of the coronal plane deformity could be achieved with soft-tissue balancing procedures.<sup>13</sup> In a prospective observational study, a satisfactory clinical outcome of TAA in 103 ankles was reported in both patients with significant ( $> 15^\circ$  varus or valgus) malalignment and neutral alignment ( $< 5^\circ$  varus or valgus).<sup>14</sup> Most studies have focused on comparing the outcomes of varus deformity and those with neutral alignment but the significance of a severe varus deformity has not been fully determined.<sup>5,15</sup>

■ S-D. Joo, MD, Resident  
Chonnam National University  
Hospital - Orthopaedics,  
Jebongro 42, Donggu Gwangju  
501-757, Republic of Korea.

■ K-B. Lee, MD, PhD, Professor  
Chonnam National University  
Hospital - Orthopaedics,  
Jebongro 42, Donggu Gwangju  
501-757, Republic of Korea.

Correspondence should be sent  
to K-B. Lee; email:  
kbleeos@chonnam.ac.kr

©2017 The British Editorial  
Society of Bone & Joint  
Surgery  
doi:10.1302/0301-620X.99B10.  
BJJ-2016-1275.R1 \$2.00

*Bone Joint J*  
2017;99-B:1335–42.  
Received 6 December 2016;  
Accepted after revision 11 May  
2017

**Table I.** Patient demographics

	Neutral	Moderate varus	Severe varus	p-value*
Ankles (n)	35	35	35	
Gender (M/F)	25/10	25/10	22/13	0.506
Age at surgery <sup>†</sup> (yrs)	62.7 (48 to 77)	60.1 (45 to 72)	64.1 (47 to 75)	0.595
Body mass index <sup>†</sup> (kg/m <sup>2</sup> )	24.9 (19.8 to 29.0)	25.2 (20.0 to 28.7)	26.0 (19.5 to 29.2)	0.282
<b>Diagnosis</b>				
Primary osteoarthritis	26	18	6	
Post-traumatic osteoarthritis	9	17	29	
Trauma	9	8	13	
Instability	0	9	16	
Follow-up duration <sup>†</sup> (mths)	56.2 (24 to 141.9)	46.0 (24 to 114.4)	50.2 (24 to 147.2)	0.384

\*analysis of variance

†values are given as mean with the range in parentheses

Our hypothesis is that a satisfactory clinical and radiographic outcome of TAA can be obtained regardless of the severity of the pre-operative varus deformity when post-operative alignment is restored to neutral. The purpose of this study is to compare the clinical and radiographic outcomes of TAA for end-stage ankle OA with moderate ( $5^{\circ}$  to  $15^{\circ}$ ) and severe ( $> 15^{\circ}$ ) varus deformity with that of neutrally aligned ankles ( $< 5^{\circ}$  varus).

### Patients and Methods

**Patients.** This study was approved by the institutional review board, and informed consent was obtained from all patients. The study was performed according to the World Medical Association Declaration of Helsinki.<sup>16</sup>

Between February 2005 and June 2013, 189 consecutive TAA procedures were performed on 179 patients with symptomatic ankle OA using a cementless, three-component HINTEGRA prosthesis (Newdeal SA, Lyon, France). Inclusion criteria for this study were duration of symptoms of more than six months, no local neurovascular insufficiency, adequate bone stock and a stable ankle. A total of 54 patients (62 ankles) were excluded because of valgus coronal alignment, rheumatoid arthritis, avascular necrosis of the talus, Charcot arthropathy, haemophilic arthropathy, or follow-up of  $< 24$  months.

The remaining 125 patients (127 ankles) were divided into three groups by the pre-operative coronal plane tibiotalar angle; neutral alignment ( $< 5^{\circ}$  varus), moderate varus deformity ( $5^{\circ}$  to  $15^{\circ}$ ), and severe varus deformity ( $> 15^{\circ}$ ). Each group was matched for age, gender, body mass index (BMI), and follow-up duration. In all 20 unmatched patients (22 ankles) were excluded and the remaining 105 patients (105 ankles) were included in this study. In each group 35 patients had characteristics similar to those obtained from the pre-operative demographic data, but significant differences in pre-operative diagnoses were detected among the three groups (Table I).

**Surgical technique.** Patients underwent surgery by a single surgeon (K-BL) under general anaesthesia in the supine position with a pneumatic thigh tourniquet. The operations were performed through a 10 cm to 12 cm anterior

longitudinal incision, between the tendons of tibialis anterior and extensor hallucis longus. A standard technique<sup>17</sup> was used to prepare the tibial and talar surfaces with additional soft-tissue procedures as required, so that after insertion of the TAA implants, satisfactory alignment, stability, and joint movement were confirmed and component position was checked by a C-arm image intensifier (GE Healthcare, Chicago, Illinois). The wound was closed over a suction drain and covered with a compressive dressing.

Post-operatively, a well-padded short leg splint was used for two weeks to maintain the foot in a neutral position during the wound healing process and the patient remained non-weight-bearing. After two weeks, the patient was allowed to bear weight as tolerated in an ankle-foot orthosis and after four weeks, a foot and ankle rehabilitation programme was started. Full weight-bearing was permitted eight weeks post-operatively. The duration of immobilisation was determined according to the additional procedures, such as the Modified Bröstrom procedure or a calcaneal osteotomy. All patients were followed at one, three, six, and 12 months post-operatively and annually thereafter.

**Radiographic assessment.** The 105 patients were divided into three groups based on pre-operative coronal plane alignment: neutral ( $< 5^{\circ}$  varus or valgus), moderate ( $5^{\circ}$  to  $15^{\circ}$  of varus), and severe ( $> 15^{\circ}$  varus). The alignment angle was determined from the angle formed between the anatomical axis of the tibia and a line perpendicular to the talus or talar component (Fig. 1). Standardised weight-bearing anteroposterior (AP) and lateral radiographs of the ankle were obtained pre-operatively and immediately post-operatively (Fig. 2). Follow-up radiographs were taken at one, three, six, and 12 months post-operatively and annually thereafter. All radiographic values were measured accurately using the standard tools in a picture archiving and communication system (Maroview version 5.4; Marotech Inc., Quebec, Canada) by two reviewers (S-DJ, G-WL) who were not involved in either the surgery or clinical assessment. On the AP radiograph, moderate varus alignment is defined as tibiotalar angle  $> 5^{\circ}$  but  $< 15^{\circ}$ , while valgus alignment is defined as a negative value. The difference

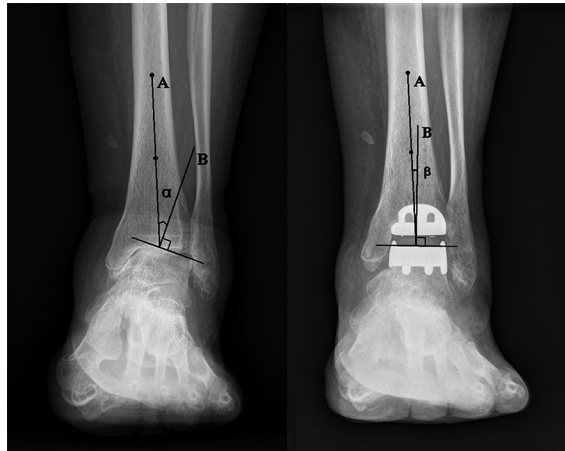


Fig. 1

Radiographs showing the anatomical axis of the tibia (A), which coincides with the mechanical axis of the normal tibia, is defined as a line connecting the centre of the cortex of the tibia at 5 cm and 10 cm proximal to the tibial plafond. The angle ( $\alpha$ ) between the anatomical axis of the tibia and the line drawn perpendicular to the talar dome (B) on the pre-operative weight-bearing anteroposterior view of the ankle was defined as the pre-operative coronal plane alignment of the ankle joint. Angular position of the implants is also measured on the weight-bearing anteroposterior view. The angle ( $\beta$ ) between the anatomical axis of the tibia (A) and the line drawn perpendicular to the talar component (B) was defined as the post-operative coronal plane alignment angle of the ankle joint.

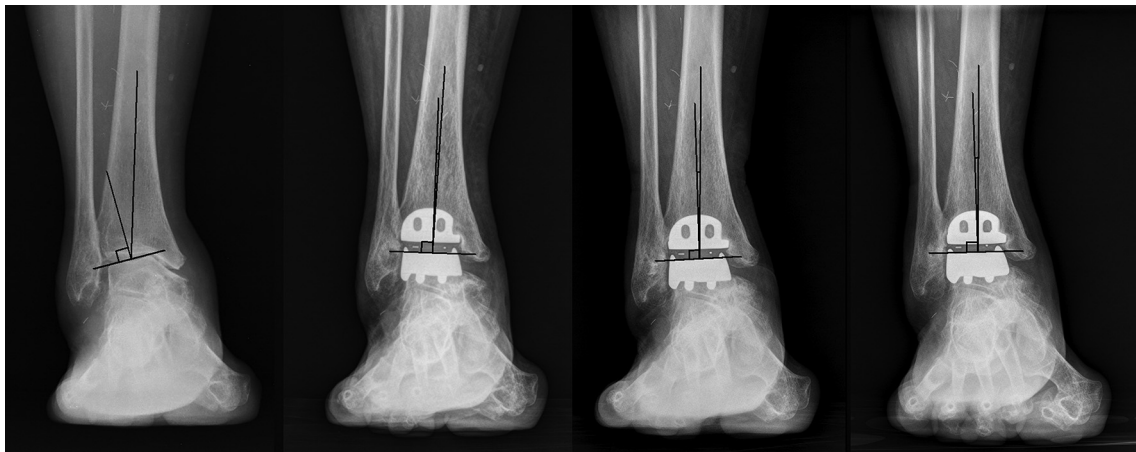

Fig. 2

A patient with a post-traumatic ankle osteoarthritis with incongruent severe varus deformity (tibiotalar angle  $17^\circ$  varus). Pre-operative, one, three, and five years (left to right) post-operative standing anteroposterior radiographs were made.

between these values determined the magnitude of the coronal plane malalignment. A pre-operative varus or valgus deformity of  $> 15^\circ$  was defined as a severe deformity.<sup>13</sup>

**Clinical assessment.** Clinical assessment of the pre-operative and final post-operative results included the American Orthopaedic Foot and Ankle Society (AOFAS) ankle-hind-foot score,<sup>18</sup> a visual analogue scale (VAS) for pain (0 = best, 10 = worst), the physical component summary (PCS) and mental component summary (MCS) subscales of the Short Form (SF)-36 Standard Version 2.0 Health Survey score,<sup>19,20</sup> and range of movement (ROM) measured using a goniometer along the lateral border of the leg and foot. Clinical outcomes were evaluated by two reviewers

(H-AL, S-HW) who were not directly involved in the surgical procedure and radiographic assessment. Any peri-operative complications or additional procedures were also noted.

**Statistical analysis.** To minimise selection bias, we performed a propensity score matching by a logistic regression with age at procedure, gender, BMI, and follow-up duration based on the severe group (35 ankles). To determine the significance of the intergroup differences, the independent statistical methods including 1x3 inter-subject analysis of variance (ANOVA) with Tukey's Honestly Significant Differences *post hoc* test were performed to identify any significant differences among AOFAS scores, VAS scores, SF-36 scores, ROM, and tibiotalar alignment due to the

**Table II.** Radiographic outcomes of total ankle arthroplasty by pre-operative coronal plane alignment (means with range and standard deviation, SD)

Tibiotalar angle(°)	Neutral (n = 35)	Moderate varus (n = 35)	Severe varus (n = 35)	p-value*
Pre-operative	0.5 (-3.5 to 4.4) (SD 2.8)	9.4 (5.1 to 13.4) (SD 2.9)	20.0 (15.1 to 32.2) (SD 4.7)	0.002
Final follow-up	2.6 (0.1 to 8.9) (SD 2.3)	3.1 (0.1 to 6.5) (SD 2.2)	4.6 (1.0 to 10.6) (SD 2.9)	0.031
Comparison with neutral group†	-	0.4 (SD 0.6) (p = 0.570)	1.9 (SD 0.7) (p = 0.024)	-

\*analysis of variance

†values are given as mean and standard deviation with the p-value in parentheses (Tukey's Honestly Significant Differences *post hoc* test)**Table III.** Clinical outcomes of total ankle arthroplasty by pre-operative coronal plane alignment

	Neutral (n = 35)	Moderate varus (n = 35)	Severe varus (n = 35)	p-value*
<b>ROM; dorsiflexion† (°)</b>				
Pre-operative	9.50 (0 to 20)	8.7 (0 to 20)	10.2 (0 to 20)	0.559
Final	10.3 (0 to 20)	9.5 (0 to 20)	9.4 (0 to 20)	0.772
Improvement	0.6 (-10 to 20)	0.8 (-10 to 10)	-0.8 (-15 to 10)	0.668
<b>ROM; plantar flexion† (°)</b>				
Pre-operative	23.4 (0 to 40)	24.7 (0 to 50)	22.9 (0 to 20)	0.792
Final	26.5 (10 to 40)	26.6 (5 to 40)	23.2 (0 to 40)	0.247
Improvement	3.1 (-20 to 30)	1.9 (-20 to 25)	0.3 (-15 to 25)	0.608
<b>AOFAS score†</b>				
Pre-operative	49.1 (26 to 67)	56.3 (23 to 79)	51.6 (19 to 78)	0.162
Final	93.0 (63 to 100)	91.8 (62 to 100)	92.2 (65 to 100)	0.880
Improvement	44.1 (9 to 74)	35.2 (11 to 66)	39.0 (5 to 71)	0.834
<b>VAS†</b>				
Pre-operative	6.8 (5 to 10)	6.4 (4 to 10)	6.7 (4 to 9)	0.163
Final	1.0 (0 to 5)	1.1 (0 to 5)	1.2 (0 to 6)	0.880
Improvement	5.9 (4 to 10)	5.2 (0 to 8)	5.5 (1 to 8)	0.625
<b>SF-36 PCS score†</b>				
Pre-operative	44.3 (23 to 60)	50.8 (21 to 71)	46.6 (17 to 70)	0.147
Final	83.7 (57 to 90)	83.0 (59 to 90)	77.9 (53 to 85)	0.008
Improvement	39.0 (8 to 67)	33.7 (-7 to 69)	31.9 (6 to 66)	0.202
<b>SF-36 MCS score†</b>				
Pre-operative	36.7 (19 to 49)	42.0 (17 to 59)	38.6 (14 to 58)	0.189
Final	69.1 (47 to 75)	68.5 (49 to 75)	67.0 (44 to 71)	0.405
Improvement	32.5 (7 to 56)	26.5 (-6 to 58)	28.3 (5 to 55)	0.216

\*analysis of variance

†values are given as mean with the range in parentheses ROM, range of movement; AOFAS, American Orthopaedic Foot and Ankle Society; VAS, visual analogue scale; SF, Short Form; MCS, mental component score; PCS, physical component score

non-parametric data distribution. For all of the statistical analyses, a p-value < 0.05 was considered significant. Parameters are presented as means with the range in parentheses. All components of the statistical analysis were reviewed independently by a professional medical statistician consultant (M-HS). Analyses were performed using SPSS v.18.0 (SPSS Inc., Chicago, Illinois).

## Results

**Radiographic outcomes.** As shown in Table II, the mean tibiotalar angle of each group was 2.6° (0.1° to 8.9°), 3.1° (0.1° to 6.5°), and 4.6° (1.0° to 10.6°) at final follow-up with a statistically significant intergroup difference (p = 0.031, one-way ANOVA). Tibiotalar angle measured at the final follow-up showed that the degree of coronal alignment of the severe varus group retained statistically greater varus than that of the neutral group. Despite the fact that angular deformity of the severe varus group was

less completely corrected, the mean final coronal alignment of each group was within neutral range without a statistically meaningful difference in the occurrence rate of major complications or revision rate.

**Clinical outcomes.** As shown in Table III, AOFAS, VAS, SF-36 MCS score and ROM all improved at final follow-up across the three groups. On intergroup comparison, there was no significant difference in clinical outcomes other than SF-36 PCS score among three groups at final follow-up (p = 0.008, one-way ANOVA) (Fig. 3).

**Additional procedures.** Some patients required additional procedures performed at the time of TAA to achieve ankle congruity and stability. Seven from the neutral group (20.0%), 20 from the moderate varus group (57.1%), and 21 from the severe varus group (60.0%) underwent additional procedures (Table IV).

**Complications.** There was a total of 15 complications in the neutral group, 12 in the moderate group, and 19 in the severe

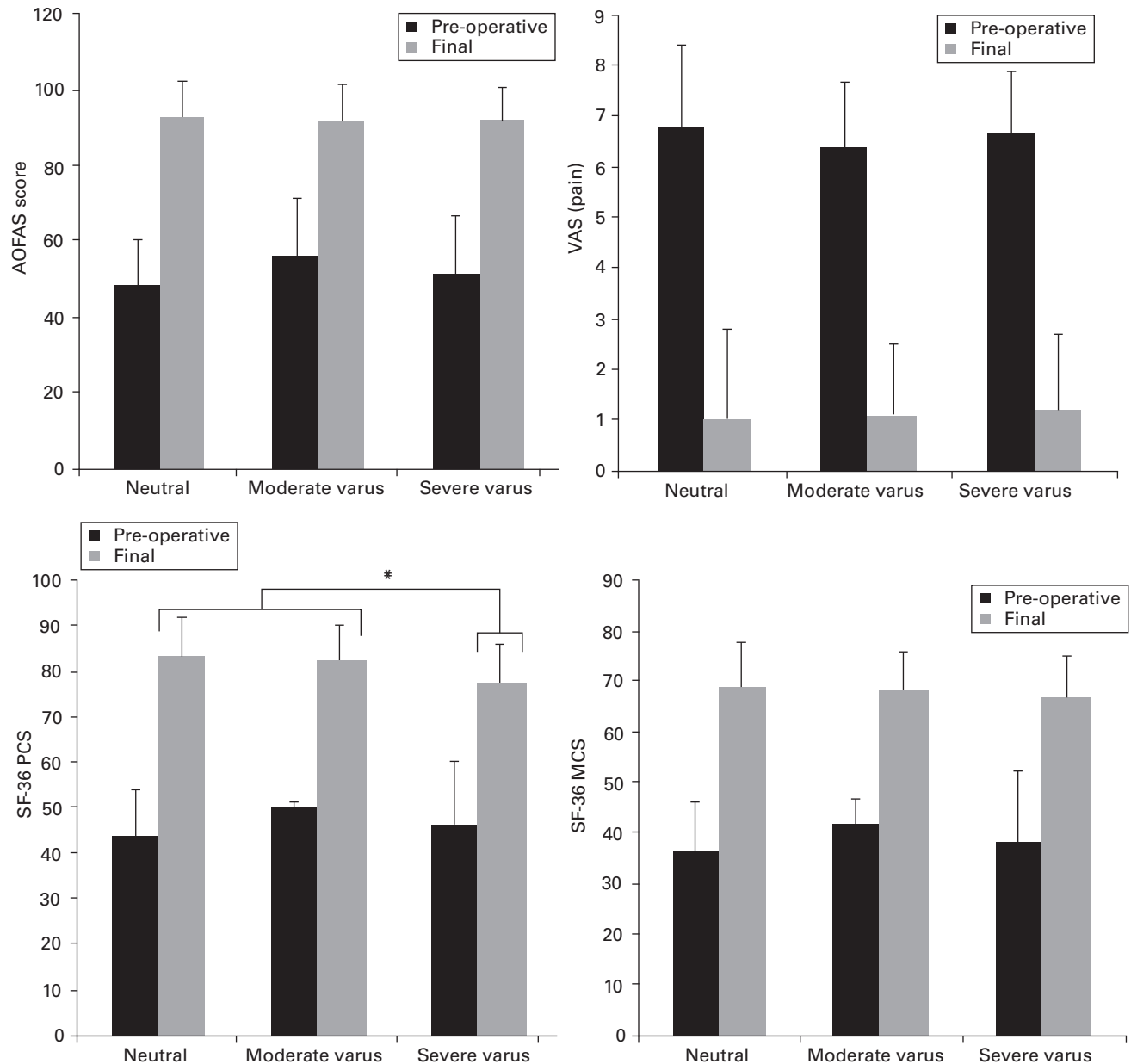


Fig. 3

Bar graphs showing the mean pre-operative and final follow-up clinical values by pre-operative coronal plane alignment group. The error bars indicate standard deviation (AOFAS, American Orthopaedic Foot and Ankle Society; VAS, visual analogue scale; SF-36 PCS, Short Form-36 physical component summary score; SF-36 MCS, Short Form-36 mental component summary score) (\*significant difference between final neutral and severe varus group, and final moderate and severe varus group ( $p = 0.008$ , one-way analysis of variance).

group. Complications were divided into major complications (aseptic loosening and deep infection) and minor complications (minor wound problem, fractures, heterotopic ossifications, and nerve/tendon injuries) (Table V).<sup>21</sup> Revision procedures consist of four exchanges of one or more prosthetic components (due to aseptic loosening, infection, or displacement of the polyethylene bearing). Major complications in the neutral group included one aseptic loosening and one deep infection. Both patients underwent revision arthroplasty. In the moderate group, one patient

underwent revision surgery for displacement of the polyethylene bearing. One patient in the severe group underwent revision because of the aseptic loosening of both components and in addition, there were two ankles with residual varus deformity seen at follow-up. As there was no evidence of either osteolysis or component loosening, the ankles were kept under observation and not revised. We could not see any obvious association between the severity of pre-operative deformity and the risk of a major complication.

**Table IV.** Additional surgical procedures of total ankle arthroplasty by pre-operative coronal plane alignment

	Neutral (n = 35), n (%)	Moderate varus (n = 35), n (%)	Severe varus (n = 35), n (%)	p-value*
Percutaneous Achilles tendon lengthening	4 (11.4)	9 (25.7)	8 (22.9)	0.292
Medial deltoid ligament release	2 (5.7)	7 (20.0)	14 (40.0)	0.001
Modified Bröstrom procedure	1 (2.9)	7 (20.0)	9 (25.7)	0.025
Calcaneal osteotomy (Dwyer)	0 (0)	1 (2.9)	1 (2.9)	0.608
Supramalleolar osteotomy	0 (0)	0 (0)	1 (2.9)	0.371
Syndesmotic fusion	0 (0)	1 (2.9)	0 (0)	0.371
Total (ankles)	7 (20.0)	20 (57.1)	21 (60.0)	0.001

\*analysis of variance

**Table V.** Complications associated with total ankle arthroplasty by coronal plane alignment

	Neutral (n = 35)	Moderate varus (n = 35)	Severe varus (n = 35)	Total (n = 105)	p-value*
Osteolysis	4	2	5	11	0.498
+ Aseptic loosening	1 (1 revision)	0	1 (Revision)	2	0.608
+ Component subsidence	0	1	0	1	0.371
Polyethylene dislodgement	0	1 (1 polyethylene change)	0	1	0.371
Deep infection	1 (1 revision)	0	0	1	0.371
Wound problem	0	2	2	4	0.360
Lateral malleolar fracture	0	0	1	1	0.371
Heterotopic ossification	6	3	3	12	0.436
Ankle ankylosis	0	1	1	2	0.608
Post-operative varus deformity	1	1	2	4	0.776
Tarsal tunnel syndrome	0	1	2	3	0.364
Posterior tibial nerve injury	0	0	2	2	0.133
Peroneal nerve injury	2	0	0	2	0.133
Major complications†	2	2	1	5	0.815
Minor complications†	13	10	18	41	0.144
Total (ankles), n (%)	15 (42.9)	12 (34.2)	19 (54.3)	46 (43.8)	0.244

\*analysis of variance

†the major complications (aseptic loosening and deep infection) and minor complications (minor wound problem, fractures, heterotopic ossifications, and nerve/tendon injuries) are listed above<sup>21</sup>

## Discussion

We believe our study is important as it reports the outcomes in TAA patients with neutral, moderate or severe varus deformity in three matched patient groups. The most important finding of this study was similar clinical outcomes between the three groups. Across the three groups, satisfactory alignment and stable ankles could be achieved with similar clinical and radiological outcomes even if additional intra-operative procedures were required to achieve this.

The treatment of end-stage OA of the ankle with coronal plane deformity has been widely reported. The current literature suggests that a tibiotalar angular deformity  $>10^\circ$  is one of the major factors that results in a poor surgical outcome<sup>9,22</sup> and some authors have suggested that severe coronal plane deformity is a contraindication for TAA. A report of 93 TAAs by Doets et al<sup>9</sup> showed 90% survivorship at eight years in neutrally aligned ankles *versus* 48% in ankles with deformity  $>10^\circ$  and suggested that a pre-operative varus or valgus deformity  $>10^\circ$  was an absolute contraindication to ankle arthroplasty. Wood and Deakin<sup>5</sup> suggested that a talar tilt  $>15^\circ$  was a relative contraindication for TAAs in a report of 200 TAAs. Hintermann, in their study of 134 TAAs,<sup>23</sup> and Clare and Sanders<sup>24</sup> reported that pre-operative varus deformity  $>20^\circ$  was an absolute contraindication to TAA. Although a pre-operative varus malalignment increases the

technical difficulty, as implants, techniques, and surgical experience improve, the indications for TAA with varus OA of the ankle is expanding. In 17 of our 35 TAAs in our severe varus group the deformity exceeded  $20^\circ$ , the most severe being  $32.2^\circ$ . This was previously considered an absolute contraindication.<sup>11</sup> Among these 17, three minor complications (two posterior tibial nerve neuromas with tarsal tunnel syndrome, one residual varus deformity with partial ankylosis) were detected. Our results show that TAA can be performed in ankles with severe varus deformity, providing particular care is taken to address causes of the varus malalignment with adequate additional procedures performed as required.

It is important to achieve a correct post-operative alignment of the TAA to prevent edge loading of the implant.<sup>25-27</sup> When operating on a varus ankle, medial soft-tissue release is required with lateral ligament plication to obtain the correct soft-tissue balance.<sup>28</sup> In addition, osteophyte debridement and cavus deformity correction may also be required to correct a coronal malalignment  $\geq 10^\circ$ .<sup>12</sup> Any instability or residual deformity should be managed and requires additional early procedures to gain proper correction.<sup>29</sup> We found that to obtain a stable ankle joint, more soft-tissue balancing procedures were necessary in the moderate and severe groups compared with the neutral group.

In the moderate group, 57.1% of ankles required additional procedures and in the severe group it was 60.0% of ankles compared with 20.0% in the neutral group. There was no obvious association between the number of additional procedures and radiographic and patient-reported outcomes for cases of varus  $> 15^\circ$ .

In other studies of TAA, the mean AOFAS scores improved from 23.7 to 80.9 points in 36 ankles with a varus deformity  $\geq 10^\circ$  at a mean follow-up of 36.7 months,<sup>12</sup> and 43.7 to 83.4 points in 24 ankles with a tibiotalar angle  $\geq 20^\circ$  at 25.1 months of follow-up.<sup>30</sup> Our results were comparable with those of pre-operative tibiotalar alignment  $< 10^\circ$  and  $20^\circ$ . According to this study, the moderate and severe varus groups showed good and similar outcomes in terms of AOFAS score, VAS, and ROM compared with the neutral group. Although the post-operative SF-36 score was relatively lower in the severe varus group than in the neutral and moderate groups, overall satisfaction and daily life functioning were similar at final follow-up. As long as appropriate additional procedures are applied simultaneously, the presence of accompanying deformities or intra-articular problems did not significantly affect the results.

In terms of radiographic outcomes, the mean post-operative tibiotalar angle of the neutral and severe varus groups were  $2.6^\circ$  and  $4.6^\circ$ , respectively, with statistically less corrected coronal alignment in the latter. However, post-operative angular differences were not correlated with clinical outcomes.

In the present study, the severe deformity group had a 54% complication rate which is higher than in the other two groups. The major complication rates were similar across the three groups and the higher overall complication rate in the severe varus group seems to be related to minor complications (18 of 19 ankles). However, care should be taken for severely deformed ankles because of the anatomic alterations. In a previous paper<sup>31</sup> we reported an overall prevalence of nerve injuries after TAA of 15.3% (23/150 patients), with the posterior tibial nerve most commonly affected. Anatomical change after TAA for ankles with coronal plane deformity  $> 10^\circ$  can lead to tarsal tunnel syndrome due to strain of the posterior tibial nerve.<sup>32</sup> Considering the vulnerability to iatrogenic injury due to its anatomical location, proper soft-tissue release and familiarity with surgical technique is required to avoid posterior tibial nerve injury.<sup>33</sup>

This study had some limitations. Follow-up in the severe group was for a mean of 50.2 months (24 to 147.2) and that may not be long enough to exclude late complications associated with TAA in this group, particularly those ankles with residual post-operative coronal plane deformity. Comparative studies between excessive coronal deformities with longer follow-up durations are needed to evaluate TAA efficacy and survival rates. We used AOFAS score for our clinical outcome assessment but it is not sensitive enough to compare clinical difference such as sports activity levels.

However, because of its wide use in the literature, we believe that the AOFAS score is still valuable.

Although initial TAA results were disappointing, recent reports have shown good short-term results, especially when adjunctive procedures are combined, not only to achieve a neutral alignment but also to restore lateral ligamentous stability.<sup>34</sup> The success of joint arthroplasty depends on many factors, including patient selection, prosthetic design, soft-tissue balancing, implant position and severity of joint deformity.<sup>35-38</sup> Among predisposing factors, ankles with varus malalignment  $> 15^\circ$  can be appropriate candidates for TAA. The results of this study suggest similar clinical and radiographic outcomes of TAA for ankle OA among neutral alignment, moderate and severe varus groups. Although different radiographic outcomes were seen in the severe varus group, this did not affect the clinical results of TAA. To establish neutral alignment on the coronal plane, more additional procedures were required in the moderate and severe varus groups than in the neutral group. With proper implant positioning and ligament balancing, satisfactory outcomes can be achieved.

Where varus malalignment is identified radiologically, the magnitude of the deformity does not affect the clinical and radiographic outcomes providing post-operative neutral implant alignment is achieved. Thus, TAA can be recommended as an effective and reliable treatment method for end-stage ankle OA regardless of severity of varus deformity.



#### Take home message:

- TAA can be helpful in treating OA of the ankle regardless of severity of varus deformity, providing proper implant positioning and ligament balancing are achieved.

#### Author contributions:

SD. Joo: Data collection and analysis, Radiographic assessment, Writing the manuscript.

KB. Lee: Study design, Planning of study, Performing the operations, Revising the manuscript.

The authors would also like to acknowledge the following contributions: GW. Lee, radiographic assessment; HA. Lim, clinical assessment; SH. Wang, clinical assessment and MH. Shin, statistical analysis.

No benefits in any form have been received or will be received from a commercial party related directly or indirectly to the subject of this article.

This article was primary edited by M. Barry and first proof edited by G. Scott.

#### References

1. Lee KT, Lee YK, Young KW, et al. Perioperative complications of the MOBILITY total ankle system: comparison with the HINTEGRA total ankle system. *J Orthop Sci* 2010;15:317-322.
2. Gougoulas N, Khanna A, Maffulli N. How successful are current ankle replacements?: a systematic review of the literature. *Clin Orthop Relat Res* 2010;468:199-208.
3. Alvine FG. The AGILITY ankle: mid- and long-term results. *Orthopade* 2006;35:521-526.
4. Hintermann B, Valderrabano V, Dereymaeker G, Dick W. The HINTEGRA ankle: rationale and short-term results of 122 consecutive ankles. *Clin Orthop Relat Res* 2004;424:57-68.
5. Wood PL, Deakin S. Total ankle replacement. The results in 200 ankles. *J Bone Joint Surg [Br]* 2003;85-B:334-341.

6. **Trincat S, Kouyoumdjian P, Asencio G.** Total ankle arthroplasty and coronal plane deformities. *Orthop Traumatol Surg Res* 2012;98:75–84.
7. **Rippstein PF, Huber M, Coetzee JC, Naal FD.** Total ankle replacement with use of a new three-component implant. *J Bone Joint Surg [Am]* 2011;93-A:1426–1435.
8. **Robert BA, Michael JC, Charles LS.** Ankle replacement. In: Alexej B, Charles LS, eds. *Mann's surgery of the foot and ankle*. Vol. 1. Ninth ed. Philadelphia: Elsevier Saunders, 2014:1085–1088.
9. **Doets HC, Brand R, Nelissen RG.** Total ankle arthroplasty in inflammatory joint disease with use of two mobile-bearing designs. *J Bone Joint Surg [Am]* 2006;88-A:1272–1284.
10. **Haskell A, Mann RA.** Ankle arthroplasty with preoperative coronal plane deformity: short-term results. *Clin Orthop Relat Res* 2004;424:98–103.
11. **Valderrabano V, Pagenstert G, Hintermann B.** Total ankle replacement - three component prosthesis. *Tech Foot Ankle Surg* 2005;4:42–54.
12. **Trajkovski T, Pinsker E, Cadden A, Daniels T.** Outcomes of ankle arthroplasty with preoperative coronal-plane varus deformity of 10° or greater. *J Bone Joint Surg [Am]* 2013;95-A:1382–1388.
13. **Reddy SC, Mann JA, Mann RA, Mangold DR.** Correction of moderate to severe coronal plane deformity with the STAR ankle prosthesis. *Foot Ankle Int* 2011;32:659–664.
14. **Queen RM, Adams SB Jr, Viens NA, et al.** Differences in outcomes following total ankle replacement in patients with neutral alignment compared with tibiotalar joint malalignment. *J Bone Joint Surg [Am]* 2013;95-A:1927–1934.
15. **Hintermann B, Valderrabano V, Knupp M, Horisberger M.** The HINTEGRA ankle: short- and mid-term results. *Orthopade* 2006;35:533–545.
16. **No authors listed.** World Medical Association declaration of Helsinki. Recommendations guiding physicians in biomedical research involving human subjects. *JAMA* 1997;277:925–926.
17. **Bai LB, Lee KB, Song EK, et al.** Total ankle arthroplasty outcome comparison for post-traumatic and primary osteoarthritis. *Foot Ankle Int* 2010;31:1048–1056.
18. **Kitaoka HB, Alexander IJ, Adelaar RS, et al.** Clinical rating systems for the ankle-hindfoot, midfoot, hallux, and lesser toes. *Foot Ankle Int* 1994;15:349–353.
19. **Ware JE Jr, Sherbourne CD.** The MOS 36-item short-form health survey (SF-36). I. Conceptual framework and item selection. *Med Care* 1992;30:473–483.
20. **Ware JE, Snow KK, Kosinski M, Gandek B.** SF-36 health survey: manual and interpretation guide. New England Medical Center. *The Health Institute, Boston*, 1993.
21. **Robert BA, Michael JC, Charles LS.** Ankle replacement. In: Alexej B, Charles LS, eds. *Mann's surgery of the foot and ankle*. Vol. 1. Ninth ed. Philadelphia: Elsevier Saunders, 2014:1030.
22. **Haskell A, Mann RA.** Ankle arthroplasty with preoperative coronal plane deformity: short-term results. *Clin Orthop Relat Res* 2004;424:98–103.
23. **Hintermann B.** *Total ankle arthroplasty: historical overview, current concepts, and future perspectives*. Austria: Springer-Verlag, 2005:91–126.
24. **Clare MP, Sanders RW.** Preoperative considerations in ankle replacement surgery. *Foot Ankle Clin* 2002;7:709–720.
25. **Barg A, Elsner A, Anderson AE, Hintermann B.** The effect of three-component total ankle replacement malalignment on clinical outcome: pain relief and functional outcome in 317 consecutive patients. *J Bone Joint Surg [Am]* 2011;93-A:1969–1978.
26. **Zhou X, Wang Q, Zhang X, et al.** Effect of pelvic obliquity on the orientation of the acetabular component in total hiparthroplasty. *J Arthroplasty* 2012;27:299–304.
27. **Haytmanek CT Jr, Gross C, Easley ME, Nunley JA.** Radiographic Outcomes of a Mobile-Bearing Total Ankle Replacement. *Foot Ankle Int* 2015;36:1038–1044.
28. **Kim BS, Choi WJ, Kim YS, Lee JW.** Total ankle replacement in moderate to severe varus deformity of the ankle. *J Bone Joint Surg [Br]* 2009;91-B:1183–1190.
29. **Lee WC, Moon JS, Lee HS, Lee K.** Alignment of ankle and hindfoot in early stage ankle osteoarthritis. *Foot Ankle Int* 2011;32:693–699.
30. **Sung KS, Ahn J, Lee KH, Chun TH.** Short-term results of total ankle arthroplasty for end-stage ankle arthritis with severe varus deformity. *Foot Ankle Int* 2014;35:225–231.
31. **Primadi A, Xu HX, Yoon TR, Ryu JH, Lee KB.** Neurologic injuries after primary total ankle arthroplasty: prevalence and effect on outcomes. *J Foot Ankle Res* 2015;8:55.
32. **Primadi A, Kim BS, Lee KB.** Tarsal tunnel syndrome after total ankle replacement—a report of 3 cases. *Acta Orthop* 2016;87:205–206.
33. **Knecht SI, Estin M, Callaghan JJ, et al.** The Agility total ankle arthroplasty. Seven to sixteen-year follow-up. *J Bone Joint Surg [Am]* 2004;86-A:1161–1171.
34. **Tan KJ, Myerson MS.** Planning correction of the varus ankle deformity with ankle replacement. *Foot Ankle Clin* 2012;17:103–115.
35. **Deorio JK, Easley ME.** Total ankle arthroplasty. *Instr Course Lect* 2008;57:383–413.
36. **Guyer AJ, Richardson G.** Current concepts review: total ankle arthroplasty. *Foot Ankle Int* 2008;29:256–264.
37. **Knecht SI, Estin M, Callaghan JJ, et al.** The Agility total ankle arthroplasty. Seven to sixteen-year follow-up. *J Bone Joint Surg [Am]* 2004;86-A:1161–1171.
38. **Spirt AA, Assal M, Hansen ST Jr.** Complications and failure after total ankle arthroplasty. *J Bone Joint Surg [Am]* 2004;86-A:1172–1178.