



10.1302/0301-620X.105B8.BJJ-2022-1071.R2

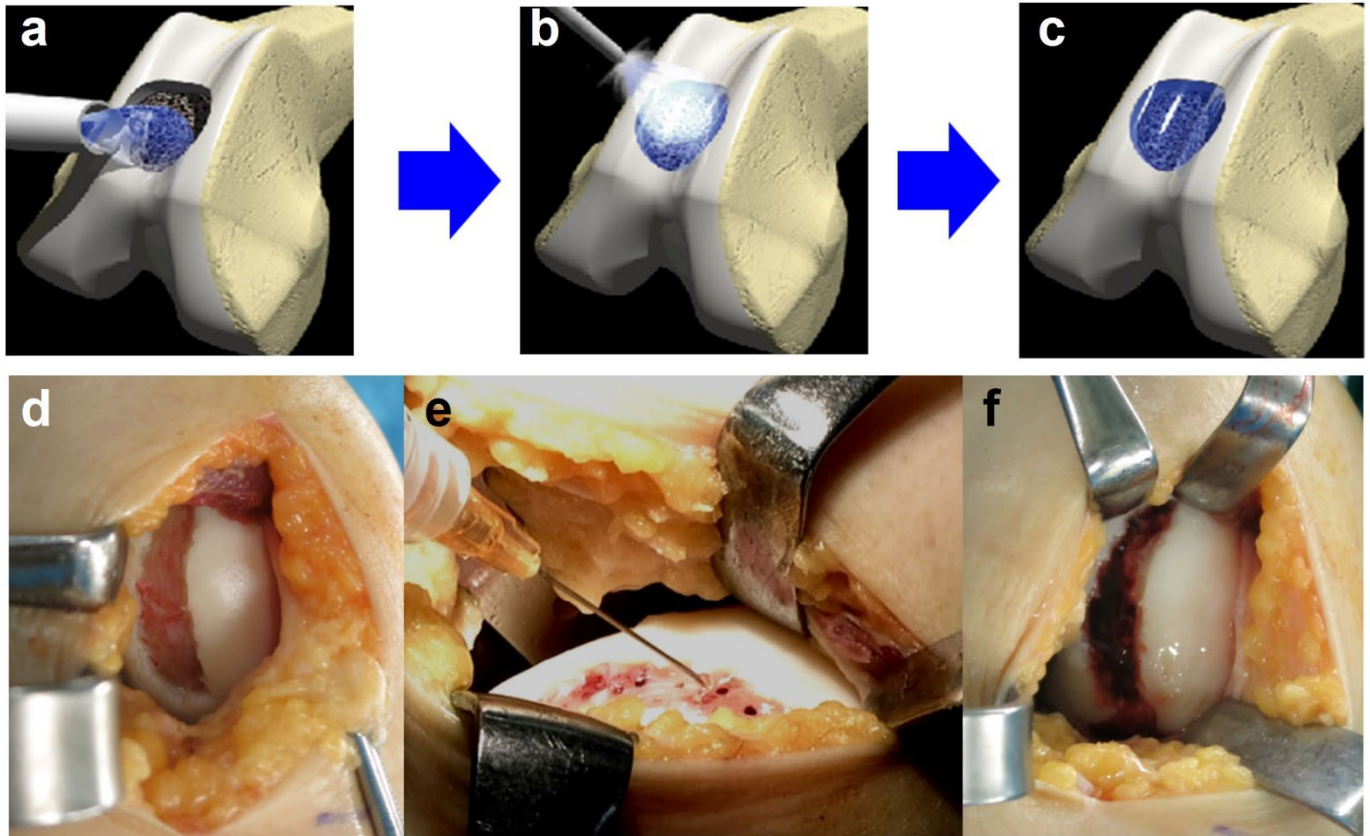


Fig a. Schematic representation of ultra-purified alginate (UPAL) gel implantation and representative surgical photos. a) The defects were filled with a UPAL solution. b) The UPAL surface layer was subsequently gelated with CaCl_2 . c) UPAL after gelation. d) Cartilage defect after debridement. e) UPAL implantation after microfracture. f) Cartilage defect immediately after UPAL gel implantation.

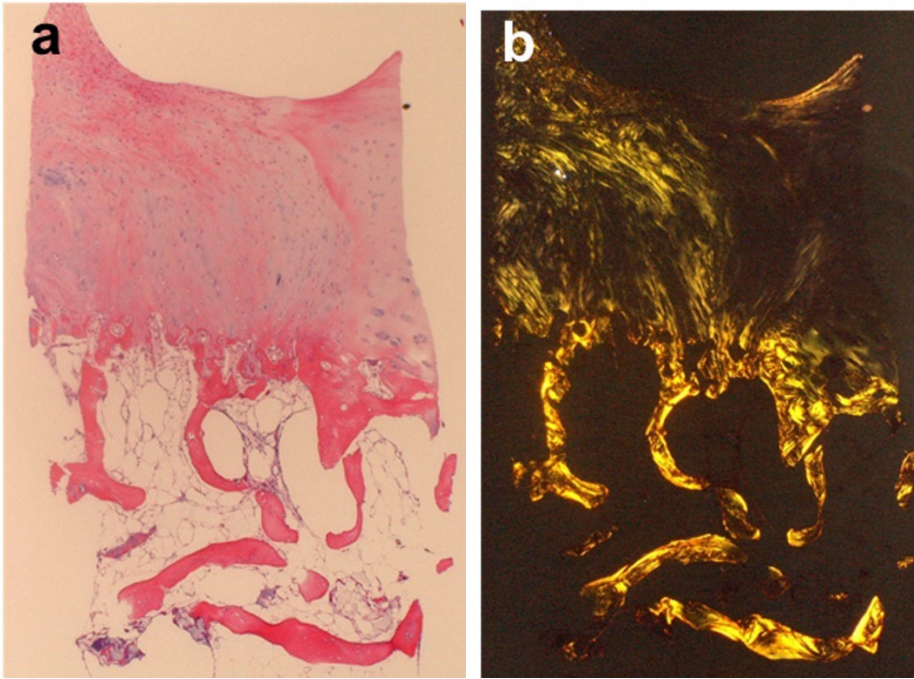


Fig b. Histological analysis of the representative biopsy specimens obtained at 72 weeks postoperatively ($\times 4$ magnification). The sections were a) stained with haematoxylin and eosin and b) observed by polarized light microscopy.