

Vikas Khanduja,  
MSc, FRCS (Orth)  
Consultant Orthopaedic  
Surgeon,  
Addenbrooke's -  
Cambridge University  
Hospital NHS Trust,  
Cambridge  
CB2 0QQ, UK.  
Associate Editor, *The  
Bone & Joint Journal*  
email: vk279@cam.ac.uk

The FRCS (Tr & Orth) examination has three components: MCQs, Vivas and Clinical Examination. The Vivas are further divided into five sections comprising Basic Science, Adult Pathology, Hands, Children's Orthopaedics and Trauma. The Clinical Examination section is divided into upper- and lower-limb cases. The aim of this section in the Journal is to focus specifically on the trainees preparing for the exam and to cater to all the sections of the exam every month. The vision is to complete the cycle of all relevant exam topics (as per the syllabus) in four years.

## MCQs and EMQs – Single Best Answer

1. With regards to carpal instability, match the pattern of instability to the statements below:

- I. Carpal instability dissociative **b**
- II. Carpal instability non-dissociative **d**
- III. Carpal instability complex **f**
- IV. Carpal instability adaptive **e**

- a. The malalignment lies either distal or proximal to the wrist
- b. There is a derangement within the bones of a single carpal row
- c. Scaphoid fracture
- d. There is dysfunction between the radius and either the proximal or distal carpal row or between the rows
- e. Ulnar negative variance
- f. A combination of CID and CIND
- g. Trapeziometacarpal osteoarthritis

Carpal instability is a disruption of the normal kinematics of the wrist and is associated with pain, weakness and loss of motion. If untreated it can cause progressive degenerative change and significant disability. It may be classified according to severity as occult (detectable on MRI), dynamic (requiring stress views or live screening) or static (visible on standard radiographs).<sup>1</sup>

**Carpal instability dissociative** describes instability between bones of the same row. Examples include DISI and VISI deformities  
**Carpal instability non-dissociative** describes instability between rows. For example midcarpal instability. This also includes any instability secondary to a simple scaphoid fracture.

**Carpal instability complex** is any situation where there is a combination of CID and CIND. Which includes all perilunate injuries. A trans-scaphoid perilunate fracture dislocation (greater arc injury) would therefore be CIC.

**Carpal instability adaptive** is related to extrinsic factors causing secondary adaptation within the carpus.

2. Which of the following mechanism induces the directional migration of osteoblasts during bone formation?

- c. Chemotaxis  
Osteoblast recruitment to the site of future bone formation is essential for skeletal development, bone remodeling and fracture healing. A number of factors associated with bone tissue have been reported to induce

directional migration of osteoblasts. IGF-I has been shown to induce cell migration of both MC3T3-E1 cells and primary mouse osteoblasts, and checkerboard analysis revealed that IGF-I markedly induced directional migration (chemotaxis) of osteoblasts.<sup>2</sup> Neutralisation of mouse IGF-I with monoclonal antibodies resulted in delayed osteoblast monolayer wound healing and cellular polarization but addition of human IGF-I reversed these effects. IGF-I also promoted cell spreading on fibronectin in an integrin beta1-dependent manner.

3. Which of the following does not have an aetiological association with non-traumatic osteonecrosis of the femoral head?

- d. Paracetamol overdose

Non-traumatic osteonecrosis of the femoral head is due to vascular occlusion in the juxtaarticular sinusoids. Its incidence is not precisely known. It is more common in males. It may be related to underlying coagulation abnormalities such as protein C and protein S deficiency. It is also associated with corticosteroid use, excess alcohol intake and sickle cell disease.<sup>3</sup> There is an increased incidence of AVN in patients with HIV. This is likely due to the hyperlipidaemia secondary to the use of protease inhibitors.<sup>4</sup>

4. A patient is having a trans-articular C1/C2 screw fixation. Which structure is most at risk?

- d. Vertebral artery

The indications for C1-C2 transarticular screw fixation include traumatic injuries to the atlantoaxial complex, instability resulting from inflammatory disease (rheumatoid arthritis), and congenital abnormalities (os odontoideum). The structure that is most at risk is the vertebral artery in the C2 vertebral artery groove, this may be at risk in almost 10%<sup>5</sup> of patients based on CT planning but actual injury is thankfully much rare.<sup>6</sup>

5. Which of the following modality of investigation exposes an individual to the greatest dose equivalent radiation?

- c. One years exposure to average background radiation

Exposure to radiation may be measured in Sieverts. The total effective dose for the above procedures is tabulated below.<sup>7</sup> Note that this is the equivalent dose to the body as a whole not the level of radiation of the imaged part.

Examination	Typical effective dose (mSv) to the whole body
Head CT	2
Annual background radiation	3
Hip radiograph	0.7
Lumbar spine	1.5
One way flight Europe to Australia	0.04 <sup>9</sup>

6. With regard to the gait cycle, a double-limb stance consists of approximately what total percentage of one cycle (stride)?  
d. 20%

#### References

1. Miller MD. *Review of Orthopaedics*. Sixth ed. Elsevier 2012;526.
2. Nakasaki M, Yoshioka K, Miyamoto Y, et al. IGF-1 secreted by osteoblasts acts as a potent chemotactic factor for osteoblasts. *Bone* 2008;43:869-79.
3. Miller MD. *Review of Orthopaedics*. Sixth ed. Elsevier 2012;37.
4. Matos MA, Alencar RW, Matos SS. Avascular necrosis of the femoral head in HIV infected patients. *Braz J Infect Dis* 2007;11:31-4.
5. Yeom JS, Buchowski JM, Kim HJ, et al. Risk of vertebral artery injury: comparison between C1-C2 transarticular and C2 pedicle screws. *Spine J* 2013;13:775-85.
6. Grob D, Jeanneret B, Aebi M, Markwalder TM. Atlanto-axial fusion with transarticular screw fixation. *J Bone Joint Surg [Br]* 1991;73-B:972-6.
7. Mettler FA Jr, Huda W, Yoshizumi TT, Mahesh M. Effective doses in radiology and diagnostic nuclear medicine: a catalog. *Radiology* 2008;248:254-63.
8. No authors listed. Australian Government. Radiation protection. [http://www.arpana.gov.au/radiationprotection/factsheets/is\\_cosmic.cfm](http://www.arpana.gov.au/radiationprotection/factsheets/is_cosmic.cfm) (date last accessed 19 May 2014).

## Vivas

### Adult Pathology

A 17-year-old female presents with history of pain in her left hip and difficulty walking. She had an infection in her hip at the age of one year and was treated with long-term antibiotics at that time. These are the radiographs obtained in clinic (Figs 1a and 1b).

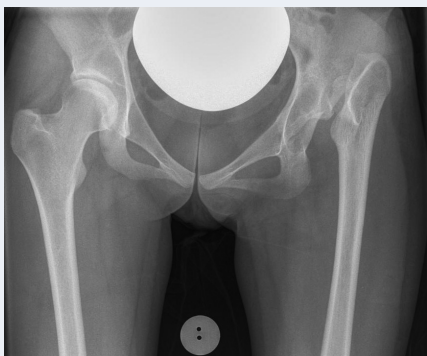

Fig. 1a

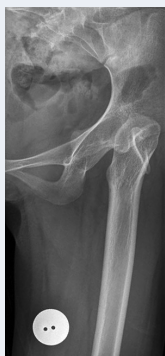

Fig. 1b

1. Describe the radiographs.  
An AP pelvis and AP centred view of the left hip showing absence of the left femoral head and formation of a superior pseudo-acetabulum. The native acetabulum however looks well formed with a normal quadrangular plate.
2. How would you classify the dysplasia?  
I would classify this using the Crowe classification for adult dysplastic hips.<sup>1</sup>This is based on the degree of subluxation with this being grade 4 (100%). Grade 1 is up to 50%, grade 2 is 50% to 75% and grade 3 is 75% to 100%.
3. What are the options of treatment?  
The options as always include non-surgical interventions, judicious analgesia, activity moderation and walking aids (including shoe lifts) however it is likely that she would progress to requiring surgical intervention. The surgical option is total hip arthroplasty.
4. How would you plan surgery if she wishes to go ahead with an operative option?

The major pre-operative consideration regards the leg length discrepancy. It is possible to ignore the leg length issue and place the acetabular component in the pseudoacetabulum however this leads to a significant increase in component loosening.<sup>2</sup>Therefore some attempt at normalising the anatomy is required. If excessive lengthening is required (possibly more than 5 cm) then the sciatic nerve may be at risk of neurapraxia. In order to reduce this risk a concurrent femoral shortening osteotomy has been recommended<sup>3</sup> although some centres advocate the use of a temporary distracting external fixator.<sup>4</sup> Both cemented and un-cemented components have been used with some success in this patient group.

### Trauma

A 27-year-old male injured his left heel following a jump off a high wall. These are the radiographs and CT scan obtained at the time of injury (Figs 2a to 2c).

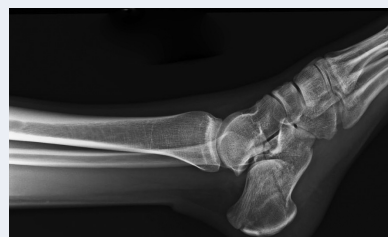

Fig. 2a

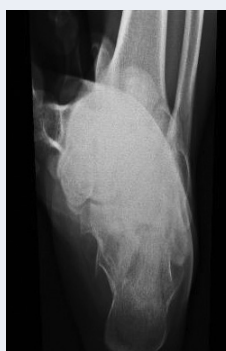

Fig. 2b

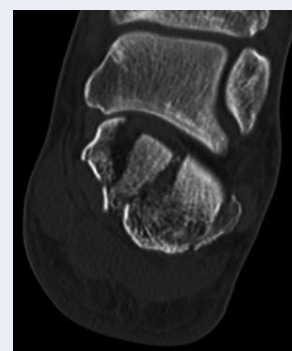


Fig. 2c

- Describe the radiographs and the coronal slice of the CT scan.  
The radiographs show an intra-articular calcaneal fracture. The lateral view reveals that Bohler's angle is reduced (normal 20° to 40°) and the calcaneal view reveals some widening of the heel. The CT scan shows two main fracture lines in the posterior facet with further lateral comminution.
- What is primary fracture line in these fractures and how does the position of the foot dictate the path of the primary fracture line?  
The primary fracture line usually runs obliquely through the posterior facet from antero-lateral to postero-medial and is caused by the lateral process of the talus being driven into the calcaneus. This is due to the foot landing with the heel in relative valgus. The actual path of the fracture line is therefore influenced by position of the foot. The anteromedial fragment which includes the sustentaculum tali is held in place by medial talocalcaneal and interosseous ligaments and is termed the 'constant fragment'.
- How would you classify this injury?  
I would classify this injury as a Sanders grade 3 injury.<sup>5</sup> This is based on the CT scan appearance.

Sanders Classification	
Type I	• Nondisplaced posterior facet (regardless of number of fracture lines)
Type II	• One fracture line in the posterior facet (two fragments)
Type III	• Two fracture lines in the posterior facet (three fragments)
Type IV	• Comminuted with more than three fracture lines in the posterior facet (four or more fragments)

Sanders further subclassified the injury depending on the location of the primary fracture line. This would therefore be a Sanders type 3BC.

- How would you manage this patient?  
Following appropriate emergency care and resuscitation according to ATLS protocols and assuming that this injury is both isolated and closed I would arrange for this gentleman to be admitted for elevation and consideration of surgery. There is an association with other skeletal injuries including lumbar spine, hip and tibial plateau. I would examine specifically for these. There is a significant risk of compartment syndrome (5% to 17%) and he requires counselling for this.<sup>6</sup> A Sanders type 3 fracture is best managed with open reduction internal fixation if he has no contra-indications to surgery. Surgery allows quicker return to work and seems to improve medium term function.<sup>7,8</sup> The timing of surgery depends on the condition of the soft tissues. The surgery should be carried out using a lateral approach and full thickness flap to reduce wound healing problems. The reconstruction should be based around the constant fragment and the lateral wall may be windowed via the comminution to assist with the reconstruction. The reduction may be temporarily held with smooth wires prior to the application of a lateral locking plate.  
If the fracture is more comminuted than is apparent on these images then a primary subtalar fusion is an option that has good results.<sup>9</sup>
- What are the predictors of prognosis?  
Male gender, medium and heavy labor, presence of

workers compensation schemes, and presence of bilateral intra-articular fractures are all shown to be associated with a poorer prognosis.<sup>10</sup>

## Hands

A 70-year-old retired nurse presents with a chronic illness and longstanding deformities of fingers of both the hands but with increasing dysfunction particularly with gripping objects (Fig. 3).

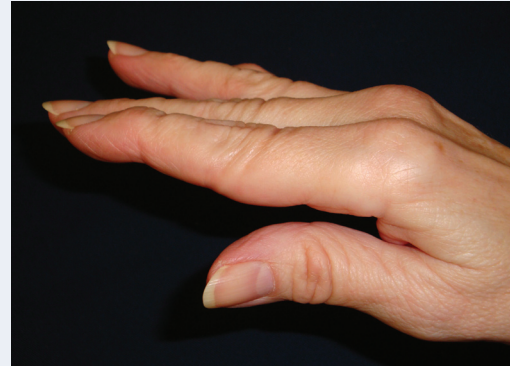

Fig. 3

- What is the most likely diagnosis?  
Rheumatoid Arthritis
- What is the finger deformity called?  
Swan neck deformity. Hyper extended PIPJ with flexed DIPJ.
- What is the aetiopathogenesis of this deformity in this particular case?  
Attenuation of the PIP joint volar plate associated with proliferative synovitis or an FDS rupture commonly cause this deformity in a rheumatoid patient. It may also be driven by distal disease, if the DIP becomes eroded and flexed with associated attenuation of the extensor tendon then this may lead to increased tension in the extensor hood over the PIPJ causing PIP hyperextension.
- How is this classified?  
The Nalebuff classification may be used.<sup>11</sup> Grade 1 has full passive movement at the PIPJ. Grade 2 has restricted movement at the PIPJ related to tenodesis. Grade 3 has a fixed contracture at the PIPJ without any underlying change on the radiograph. Grade 4 includes those who have underlying arthritic change at the PIPJ in addition to a fixed deformity.
- What is the treatment of the above deformity?  
The management depends on the clinical examination and radiographic appearance of the finger. As always a functional assessment and trial of non-surgical management with the assistance of a hand therapy department is the initial management. Surgical management depends on the grade and the principles are outlined below.  
For grade 1 consider flexor synovectomy, intrinsic release, FDS tenodesis, dermadesis, retinacular ligament reconstruction or DIP arthrodesis (to correct primary mallet finger deformity). In grade 2 the problem lies with the intrinsic and therefore release and possible MP joint reconstruction if needed. In grade 3 disease the restriction in motion may be improved by mobilisation of the lateral bands and the hyper-extension of the PIPJ may be limited by hemitenodesis of FDS tendon to the base of the middle phalanx. Grade 4 disease is managed with fusion of the

index and middle and arthroplasty of the little and ring finger PIPJs.

### Children's Orthopaedics

1. What is sclerotome subtraction and how does it explain the clinical and radiographic features (Figs 4a and 4b) in this child?

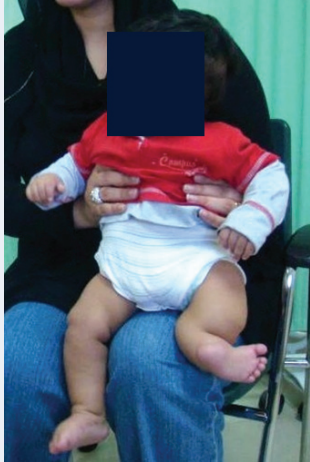

Fig. 4a

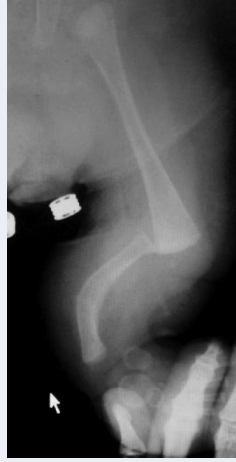

Fig. 4b

A sclerotome is a continuous band of skeletal elements extending from the spine towards the periphery, supplied by one spinal sensory nerve.

The growth and development of a limb depends on an intact sensory nerve supply (neurotrophism).

In embryonic life, if a sclerotome is damaged or fails to form, this will be reflected in the absence of that sclerotome from the limb.

This child has congenital absence of the tibia, which is due to subtraction of the L4 and part of the L3 sclerotomes.

Here is the radiograph of the femur of a nine-year-old boy (Fig. 5a)

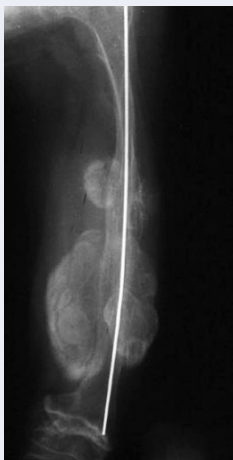

Fig. 5a

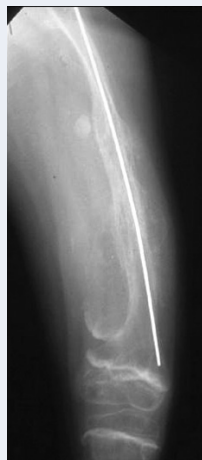

Fig. 5b

2. What is happening and how would you manage the condition?

The boy has osteogenesis imperfecta and is demonstrating hypertrophic callus after corrective osteotomy. The appearances can be frightening and there is a possibility of circulatory compromise.

The condition should be managed symptomatically and will resolve spontaneously (Fig. 5b).

### Basic Science

1. How do you assess the success of a particular type of total joint replacement?

The outcome following arthroplasty may be gauged in both objective and subjective manners. Historically objective data in the form of longevity of the implant was mainly used. This was measured by revision rates and led to the Orthopaedic Data Evaluation Panel (ODEP) rating being developed. This quantifies the length of time that an implant has follow up data for (three years, five, seven or ten) and the level of evidence favouring the use of the implant (A-C). The use of joint registries have furthered this process by publishing revision rates for each implant.<sup>12</sup> Recently more subjective measures in the form of patient rated outcome measures have been introduced.<sup>13</sup>

2. What do you understand by the term survival curve?

When referring to orthopaedic implants a survival curve is a graphical representation of the change in number of functioning implants over time. The curve therefore starts at time zero with 100% functioning implants and then this number declines over time.

3. What are the major limitations with survival curves in relation to total joint replacement?

The main criticism of survival curves when related to implants is that revision rate is a crude measure of the success of a device. It is conceivable that an implant fails but is not revised for other reasons for example the patient is unfit for surgery or refuses intervention. This would therefore lead to an under-reporting of revisions. Similarly revisions for infection or peri-prosthetic fracture may be unrelated to implant choice and need to be adjusted for. Implant survivorship gives little indication of patient satisfaction or pain relief however it remains the easiest objective measure to collect.

4. What is the National Joint Registry (NJR) and explain its role.

The National Joint registry for England, Wales and Northern Ireland has been running now for ten years and is developing and maturing into the world's largest orthopaedic registry. It collects data on primary and revision arthroplasty for hips and knees. Since 2010 it has included ankle arthroplasty and since 2012 also includes shoulder and elbow arthroplasty. It collects data via an electronic upload and publishes annual reports. These include outcomes for all of the different implants used. Furthermore the NJR analyses individual surgeons via their outcomes. This helps to identify outliers (ie those surgeons or implants which are performing worse than expected) and improves patient outcomes. The NJR is a vital source of information regarding orthopaedic implants and has a full time research fellow.

5. What is the latest evidence from the NJR with regards to metal-on-metal total hip replacements?

The 10th annual report contains an in depth review of the NJR data regarding metal on metal articulations. This suggests that metal on metal articulations have now virtually ceased with only 0.1% of hip arthroplasty in 2012 involving this bearing surface. It also highlights the high failure rate particularly in smaller head sizes and women (these factors are independent). In men with the largest head sizes the revision rate is not significantly worse than the alternatives but only 23% of men have the largest size.



## References

1. **Crowe JF, Mani VJ, Ranawat CS.** Total hip replacement in congenital dislocation and dysplasia of the hip. *J Bone Joint Surg [Am]* 1979;61-A:15-23.
2. **Pagnano W, Hanssen AD, Lewallen DG, Shaughnessy WJ.** The effect of superior placement of the acetabular component on the rate of loosening after total hip arthroplasty. *J Bone Joint Surg [Am]* 1996;78-A:1004-14.
3. **Charity JA, Tsiridis E, Sheeraz A, et al.** Treatment of Crowe IV high hip dysplasia with total hip replacement using the Exeter stem and shortening derotational subtrochanteric osteotomy. *J Bone Joint Surg [Br]* 2011;93-B:34-8.
4. **Lai KA, Shen WJ, Huang LW, Chen MY.** Cementless total hip arthroplasty and limb-length equalization in patients with unilateral Crowe type-IV hip dislocation. *J Bone Joint Surg [Am]* 2005;87-A:339-45.
5. **Sanders R, Fortin P, DiPasquale T, Walling A.** Operative treatment in 120 displaced intraarticular calcaneal fractures: results using a prognostic computed tomography scan classification. *Clin Orthop Relat Res* 1993;290:87-95.
6. **Mittlmeier T, Mächler G, Lob G, et al.** Compartment syndrome of the foot after intraarticular calcaneal fracture. *Clin Orthop Relat Res* 1991;269:241-8.
7. **Crosby LA, Fitzgibbons T.** Intraarticular calcaneal fractures: results of closed treatment. *Clin Orthop Relat Res* 1993;290:47-54.
8. **Agren PH, Wretenberg P, Sayed-Noor AS.** Operative versus nonoperative treatment of displaced intra-articular calcaneal fractures: a prospective, randomized, controlled multicenter trial. *J Bone Joint Surg [Am]* 2013;95-A:1351-7.
9. **Huefner T, Thermann H, Geerling J, Pape HC, Pohlemann T.** Primary subtalar arthrodesis of calcaneal fractures. *Foot Ankle Int* 2001;22:9-14.
10. **Tufescu TV, Buckley R.** Age, gender, work capability, and worker's compensation in patients with displaced intraarticular calcaneal fractures. *J Orthop Trauma* 2001;15:275-9.
11. **Nalebuff EA.** The rheumatoid swan-neck deformity. *Hand Clin* 1989;5:203-14.
12. **No authors listed.** National Joint Registry for England, Wales and Northern Ireland. 10th Annual Report, 2013. [http://www.njrcentre.org.uk/njrcentre/Portals/0/Documents/England/Reports/10th\\_annual\\_report/NJR%2010th%20Annual%20Report%202013%20B.pdf](http://www.njrcentre.org.uk/njrcentre/Portals/0/Documents/England/Reports/10th_annual_report/NJR%2010th%20Annual%20Report%202013%20B.pdf) (date last accessed 19 May 2014).
13. **No authors listed.** Health & Social Care Information Centre. Provisional Monthly Patient Reported Outcome Measures (PROMs) in England - April 2013 to May 2013, October 2013 release. <http://www.hscic.gov.uk/catalogue/PUB11658> (date last accessed 19 May 2014).